

VIDEOS IN CLINICAL MEDICINE

Placement of a Femoral Venous Catheter

Janet Y. Tsui, M.D., Adam B. Collins, M.D., Douglas W. White, B.A.,
Jasmine Lai, B.S., and Jeffrey A. Tabas, M.D.

INDICATIONS

From the School of Medicine (J.Y.T, A.B.C., D.W.W., J.L., J.A.T.), Department of Anesthesia (A.B.C.), and Department of Medicine, Division of Emergency Medicine (J.A.T.), University of California, San Francisco, San Francisco. Address reprint requests to Dr. Tabas at San Francisco General Hospital Emergency Services, 1001 Potrero Ave., Office 1E21, San Francisco, CA 94110, or at jtabas@sfgghed.ucsf.edu.

The insertion of a femoral venous catheter may be necessary when peripheral access to the circulatory system is compromised and no other sites for placement of a central catheter are available. Such a catheter may be used to administer large fluid volumes or potentially irritating medicines, to provide temporary access for emergency dialysis, for immediate central access during emergency resuscitation, to facilitate cardiac catheterization, or, in rare instances, for drawing blood, if a patient requires frequent blood sampling and no other access site is available.

CONTRAINDICATIONS

N Engl J Med 2008;358:e30.
Copyright © 2008 Massachusetts Medical Society.

There are few absolute contraindications to placement of a central catheter, other than the patient's not agreeing to the procedure. There are several relative contraindications. As compared with subclavian or jugular catheters, femoral catheters are associated with a higher risk of infection, thrombosis, and, in the absence of ultrasound guidance, arterial puncture.¹ If a safer option exists, it should be chosen. It is important to note that uncooperative patients place both the operator and themselves at risk for injury. Evident infection at the site where the needle will enter should prompt the operator to seek another access site. In addition, complications are more likely to occur if the site is distorted by trauma or is obscured. In patients with uncorrected bleeding disorders, a central catheter should be placed with caution and only if necessary. Central catheters should not be placed by inexperienced operators who lack supervision.

EQUIPMENT

Materials required for this procedure include personal protective equipment, a bag of sterile saline for infusion, intravenous tubing, local anesthetic medications, a central-catheter kit, and blood-drawing equipment. The central-catheter kit typically includes a sterile drape, skin preparation solution, sterile gauze, an introducer needle, a guidewire, a scalpel, a dilator, an intravenous catheter, a mechanism for securing the catheter to the skin, and a sterile, transparent dressing.

PREPARATION

Explain the procedure to the patient, and obtain written informed consent when possible. Confirm that you have the correct patient, have selected the correct anatomical location, and are planning the correct procedure. An assistant should be empowered to halt the procedure if inappropriate technique or practice occurs.

For optimal exposure of the femoral region, externally rotate and abduct the patient's leg away from midline. The femoral vein lies medial to the femoral artery as it runs distal to the inguinal ligament. Localize the vein by palpating the femoral artery, or use ultrasonography. Prepare the skin with chlorhexidine, and cover the area with a sterile drape. Use full sterile dress. Prepare the central-catheter kit, and flush the catheter ports with sterile saline. If you are using ultrasound localization, prepare the ultrasound probe for sterile use.

Anesthetize the area with long-acting anesthetic such as lidocaine with epinephrine or bupivacaine. Adequate analgesia will increase the patient's comfort and the operator's likelihood of successful catheter placement.

PLACEMENT OF THE CATHETER

After ensuring that the femoral area has been properly anesthetized, reconfirm the position of the femoral vein by palpating the femoral artery or visualizing it directly with ultrasonography. Insert the introducer needle at a 45-degree angle from the skin, directed along the course of the artery, while you pull back the plunger (Fig. 1). To prevent femoral-artery cannulation, maintain palpation of the artery while you advance the needle.

Once you see a flash of blood, carefully anchor the needle to avoid dislodging it from an intraluminal location (Fig. 2). Detach the syringe and thread the guidewire through the needle. It should pass easily and without resistance into the lumen of the vessel. While maintaining your grasp of the wire, remove the introducer needle. Incise the skin at the wire-entry site with a scalpel, keeping the sharp edge away from the wire. Advance the dilator over the wire to make a tract through the tissues into the vessel (Fig. 3). Larger catheters may have dilators that fit inside them and must be advanced together with the catheter. Unless that is the case, remove the dilator and thread the catheter over the wire. Before advancing the catheter past the skin, firmly grasp the guidewire protruding from the proximal end of the catheter. It is often necessary to feed the wire back through the catheter to accomplish this. After the catheter has been threaded into the vessel, remove the wire. Confirm the intravenous location of the catheter, flush sterile saline through each port, and secure the catheter with sutures or staples. Place a sterile dressing over the site before removing the drapes. Place all sharp and soiled materials in an appropriate receptacle.

ULTRASOUND GUIDANCE

Several studies have shown that using ultrasonography to assist in central-catheter placement increases success and reduces complications.^{2,3} Choose a linear probe rather than a curved probe for femoral catheter placement. Linear probes emit high-frequency waves that are optimal for viewing superficial structures, such as the femoral vessels. Position yourself toward the patient's feet, and place the ultrasound monitor in front of you. Orient the probe so that the patient's right is on the right side of the screen. Place the probe in a sterile sheath with coupling gel inside. Sterile gel can be applied to the outside of the protective covering. Placing the patient in a reverse Trendelenberg position engorges the femoral vein and may aid in visualization. Ultrasound imaging renders vessel walls brighter than their lumens, which are filled with blood. The femoral vein is collapsible as compared with the artery. Use of the Doppler function of the ultrasound machine may help distinguish pulsatile (arterial) from more continuous (venous) blood flow. Position the vein in the center of the screen, and insert the needle at the center of the probe (Fig. 4). After the ultrasound images indicate that the needle is in an appropriate position for entering the vein, you will also note the intravenous location by observing a flash of blood into the syringe.

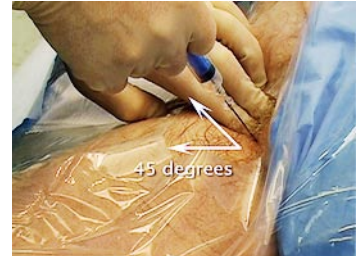

Figure 1. Inserting the Introducer Needle.

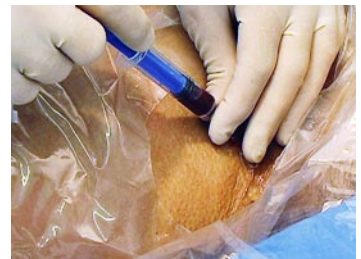

Figure 2. Anchoring the Needle.

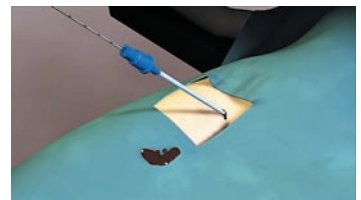


Figure 3. Advancing the Dilator to Make a Tract.

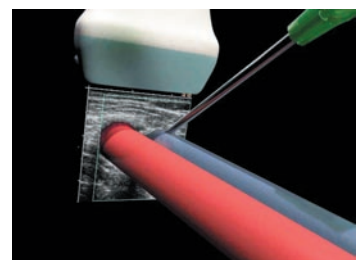


Figure 4. Inserting the Needle at the Center of the Probe.

REFERENCES

1. McGee DC, Gould MK. Preventing complications of central venous catheterization. *N Engl J Med* 2003;348:1123-33.
 2. Hind D, Calvert N, McWilliams R, et al. Ultrasonic locating devices for central venous cannulation: meta-analysis. *BMJ* 2003;327:361.
 3. Rothschild JM. Ultrasound guidance of central vein catheterization: evidence report/technology assessment. In: Making health care safer: a critical analysis of patient safety practices. No. 43. Rockville, MD: Agency for Healthcare Research and Quality, 2001:245-53. (AHRQ publication no. 01-E058.)
- Copyright © 2008 Massachusetts Medical Society.

COMPLICATIONS

Potential complications include infection, thromboembolism, arterial puncture, and hematoma. It is important to be aware of these possible problems and to keep them in mind as you monitor the patient. Less common complications include arteriovenous fistula and pseudoaneurysm. Most of these complications can be prevented by following proper sterile technique, using ultrasonography for placing the catheter, limiting the number of attempts at placing the catheter, and removing it as soon as possible.

If the femoral artery has been punctured, apply pressure to the site for at least 10 minutes. Small hematomas may be managed conservatively, but continuing hemorrhage may require surgical intervention.

Dr. Collins reports receiving lecture fees from General Electric Ultrasound. No other potential conflict of interest relevant to this article was reported.