

VIDEOS IN CLINICAL MEDICINE

Central Venous Catheterization

Alan S. Graham, M.D., Caroline Ozment, M.D., Ken Tegtmeyer, M.D.,
Susanna Lai, M.P.H., and Dana A.V. Braner, M.D.

INDICATIONS

Central venous catheterization provides a route for delivery of caustic or critical medications and allows measurement of central venous pressure.

CONTRAINDICATIONS

General contraindications for the placement of a central venous catheter include infection of the area overlying the target vein and thrombosis of the target vein; site-specific and relative contraindications include coagulopathy, although this is not an absolute contraindication. Extreme care must be exercised in patients with coagulopathy and in other patients for whom complications would be life-threatening.

EQUIPMENT

Many institutions stock prepackaged catheter-insertion kits containing the necessary equipment. The catheter should have the appropriate lumen size to deliver the required medications, and its length should be appropriate to reach the junction of the vena cava and the right atrium. Approximate length can be measured against the patient's external anatomical landmarks. Seven-French 20-cm catheters are the most commonly used. Dialysis or rapid fluid resuscitation requires larger-bore catheters. Each additional lumen decreases the size of the individual lumens, which will decrease the maximal rate at which fluids can be administered. The catheter should be flushed, and compatibility between the guide wire and the needle should be confirmed.

PREPARATION

Explain the procedure to the patient, and obtain written informed consent. Select the insertion site on the basis of the comparisons noted in Table 1. Subclavian and inter-

From the Department of Pediatrics, Division of Pediatric Critical Care, Doernbecher Children's Hospital, Portland, OR (A.S.G., K.T., S.L., D.A.V.B.); and the Department of Pediatrics, Division of Pediatric Critical Care, Duke University, Durham, NC (C.O.). Address reprint requests to Dr. Tegtmeyer at the Department of Pediatrics, Division of Pediatric Critical Care, Doernbecher Children's Hospital, Oregon Health & Science University, Mail Code: CDRC-P, 707 SW Gaines St., Portland, OR 97239-2901, or at tegtmeye@ohsu.edu.

N Engl J Med 2007;356:e21.

Copyright © 2007 Massachusetts Medical Society.

Table 1. Risk of Complications Associated with Internal Jugular, Subclavian, and Femoral Central Venous Catheterization.

Complication	Risk of Complication at Catheterization Site*		
	Internal Jugular Vein	Subclavian Vein	Femoral Vein
Pneumothorax (%)	<0.1 to 0.2	1.5 to 3.1	NA
Hemothorax (%)	NA	0.4 to 0.6	NA
Infection (rate per 1000 catheter-days)	8.6	4	15.3
Thrombosis (rate per 1000 catheter-days)	1.2 to 3	0 to 13	8 to 34
Arterial puncture (%)	3	0.5	6.25
Malposition	Low risk (into inferior vena cava, passing through right atrium)	High risk (crossing to contralateral subclavian vein, ascending internal jugular vein)	Low risk (lumbar venous plexus)

* NA denotes not applicable.

nal jugular sites are generally preferred because they present a lower risk of infection and fewer mechanical complications.¹ If the patient has challenging anatomy, a scar at the insertion site, or any other indication that could result in a difficult insertion, an expert operator should be in attendance.

Anatomical landmarks for the central approach to internal jugular venous catheterization begin at the apex of the triangle formed by the heads of the sternocleidomastoid muscle and the clavicle. A confluence between the internal jugular vein and the brachiocephalic vein facilitates cannulation at this location. After identifying the landmarks, sterilize the area with chlorhexidine, using a circular motion from the center outward, and then apply a sterile drape.

Administer local anesthesia, using 1 to 2 ml of 1% lidocaine or equivalent, with a 25-gauge needle at the cannulation site. To avoid air embolism, place the patient with head down, in the Trendelenburg position. The head should be rotated 45 degrees away from the site of cannulation; avoid excessive rotation of the head, which can cause collapse of the vein. During the procedure, place the index finger of your nondominant hand on the patient's carotid artery to diminish the risk of inadvertent puncture of the artery.

Ultrasound Guidance

In numerous studies, ultrasound guidance has been shown to increase the success of first-time catheter placement and to decrease the risk of complications.² When using ultrasound guidance, enlist an assistant either to handle the probe or to remove it when it is no longer needed.

The vein and artery appear circular and black on the ultrasound image; the vein is much more compressible when gentle pressure is applied to the skin via the probe. The needle appears echogenic and can be followed into the image of the vein on ultrasound. Newer commercial kits include needles that are more echogenic.

THE PROCEDURE

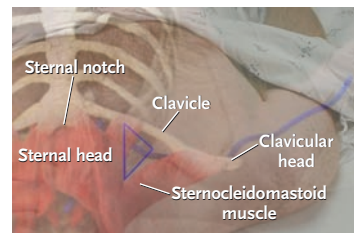
Starting just lateral to the carotid pulse, insert an 18-gauge needle slightly superior to the apex of the triangle. The needle is maintained at an angle of 20 degrees above the coronal plane as it is advanced past the apex of the triangle, with the longitudinal axis in the direction of the ipsilateral nipple. The vein is generally encountered approximately 0.5 in. (1.3 cm) under the skin,¹ though this can vary, depending on regional adiposity.

After venous access is obtained, hold the needle carefully as you disconnect the syringe. The J-shaped end of the guide wire is introduced into the needle and advanced. The wire should thread easily, without resistance, well beyond the end of the needle. If cardiac rhythm changes are noted, pull the wire back until the rhythm normalizes. Then remove the needle, leaving the wire in place. Carefully maintain control of the wire, and make a 1-to-2-mm incision at the site of skin puncture. Advance the dilator over the guide wire. Once the tract is dilated, remove the dilator and thread the catheter over the wire and into the vessel. Then remove the guide wire, confirm blood return, and apply a sterile dressing.

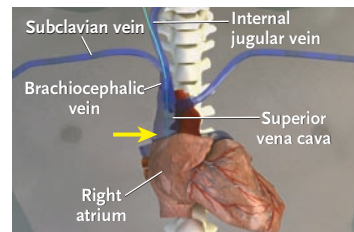
COMPLICATIONS

Risks associated with central venous catheterization include infectious, mechanical, and thrombotic complications. A chest radiograph should be obtained to confirm placement and to assess for complications.

Catheter infections occur by means of one of three mechanisms: local insertion-site infection, which travels down the catheter externally; or hub colonization followed by infection via the intraluminal route or via hematogenous seeding of the



Anatomical landmarks



Site of cannulation

catheter.¹ The Institute for Healthcare Improvement recommends five steps to reduce central-line infections: hand hygiene, adherence to maximal barrier precautions, chlorhexidine skin antiseptics, selection of an optimal catheter site, and daily review of the necessity of the catheter, with prompt removal when the catheter is no longer needed.³ Implementation of these steps has been conclusively shown to decrease the rate of catheter-related bloodstream infection.⁴ Scheduled changing of a catheter over a guide wire or moving a catheter to a new site can increase mechanical and infectious complications, and neither is recommended.¹ Antiseptic-containing hubs and antimicrobial-impregnated catheters have been shown to decrease the rate of catheter-related bloodstream infections.¹ Topical antibiotic ointments are ineffective, promote antibiotic-resistant bacteria, and increase fungal colonization.

Mechanical Complications

Mechanical complications include arterial puncture, hematoma, pneumothorax, hemothorax, arrhythmia, and improper location of the catheter, whether in an accessory vein or in the other vessels of the upper vascular system. Insertion of a catheter into the femoral vein, not shown in this video, has the highest risk of mechanical complications, but the rates of serious mechanical complications for femoral and subclavian insertion are similar.⁵ If an artery is punctured, further attempts at that site should be abandoned, and access to an alternative site should be attempted. Internal jugular and subclavian cannulation sites are preferred because of their lower overall rate of mechanical complications. However, these sites carry a small risk of hemothorax and pneumothorax.¹ Ultrasound guidance for internal jugular cannulation significantly reduces the number of attempts required and the risk of complications.²

Thrombotic Complications

Central venous cannulation increases the risk of central venous thrombosis, with the concomitant potential risk of venous thromboembolism. Thrombosis may occur as early as the first day after cannulation. The site with the lowest risk for thrombotic complications is the subclavian vein.^{1,4} Prompt removal of the catheter when it is no longer needed decreases the risk of catheter-related thrombosis.

No potential conflict of interest relevant to this article was reported.

REFERENCES

1. McGee DC, Gould MK. Preventing complications of central venous catheterization. *N Engl J Med* 2003;348:1123-33.
2. Hind D, Calvert N, McWilliams R, et al. Ultrasonic locating devices for central venous cannulation: meta-analysis. *BMJ* 2003;327:361.
3. Implement the Central Line Bundle. Cambridge, MA: Institute for Healthcare Improvement. (Accessed April 30, 2007, at <http://www.ihp.org/IHI/Topics/CriticalCare/IntensiveCare/Changes/ImplementtheCentralLineBundle.htm>.)
4. Pronovost P, Needham D, Berenholtz S, et al. An intervention to decrease catheter-related bloodstream infections in the ICU. *N Engl J Med* 2006;355:2725-32.
5. Merrer J, De Jonghe B, Golliot F, et al. Complications of femoral and subclavian venous catheterization in critically ill patients: a randomized controlled trial. *JAMA* 2001;286:700-7.

Copyright © 2007 Massachusetts Medical Society.