




TEXAS TECH UNIVERSITY
HEALTH SCIENCES CENTER™
EL PASO



Dale Quest

Paul L. Foster School of Medicine

Texas Tech University Health Sciences Center El Paso

Required reading (included as a learning material on Canvas):

Michaelson L, Sweet M, Parmalee D. The essential elements of team-based learning. Adapted from Chapter 1 of Michaelson, L., Sweet, M. & Parmalee, D. (2009) *Team-Based Learning: Small Group Learning's Next Big Step*. *New Directions in Teaching and Learning*, 7-27.



Learning Objectives

After this session and the required reading, participants will be able to:

- Define the components and composite grading of the readiness assurance process.
- Outline the nature and purpose of the application exercise.
- Compare and contrast TBL with a traditional lecture-based educational approach



Team-Based Learning is a complete coherent framework for actively engaging trainees in collaborative critical thinking.



Preparation

Study of basic concepts

Pre-class

Independent Study

Readiness Assurance Process

Work on simple problems

45-75 mins class time

Individual test

Group test

Written appeals

Tutor clarification

Application exercises

Work on complex problems

1 - 4 hours class time

Application of oriented activities

Peer Evaluation

Review

After class



Preparation

Study of basic concepts

Pre-class

Independent Study

Readiness Assurance Process

Work on simple problems

45-75 mins class time



Individual test

Group test

Written appeals

Tutor clarification


Immediate Feedback Assessment Technique (iF-AT) scoring sheet

- "scratch-and-win"-style scoring sheets dramatically increase the quality of discussion in the tRAT process and provide immediate feedback.
- each question has a row of boxes that can be scratched like a lottery ticket. A small star, exposed by scratching one of the boxes, indicates the correct answer.
- 4 points for the right answer on the 1st scratch, 2 on the 2nd, 1 point on the 3rd scratch, and zero if they scratch off all 4 boxes to reveal the correct answer.
- see P.9 of the required reading.

IMMEDIATE FEEDBACK ASSESSMENT TECHNIQUE (IF AT®)
Name Team #3 Test # 2
Subject _____ Total _____

SCRATCH OFF COVERING TO EXPOSE ANSWER

	A	B	C	D	Score
1.	★	_____
2.	...	★	_____
3.	★	_____
4.	_____
5.	_____
6.	_____
7.	_____





Application exercises

Work on complex problems

1 - 4 hours class time



Application of oriented
activities



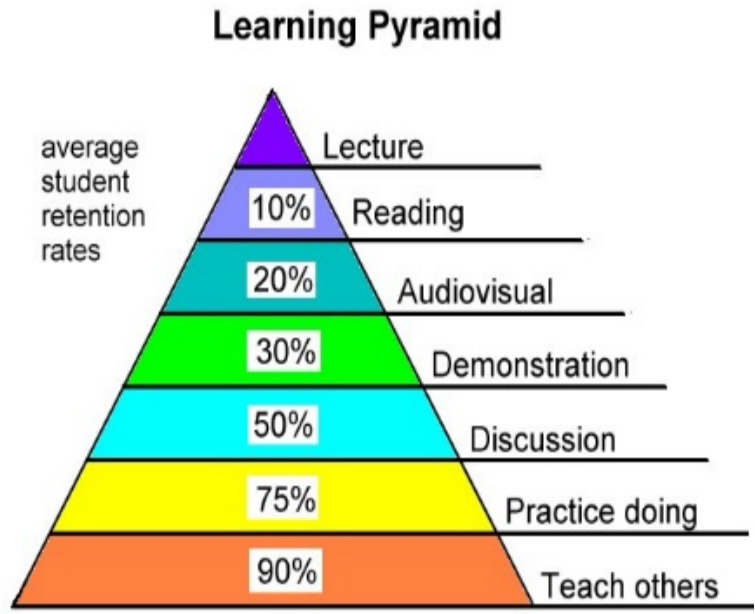
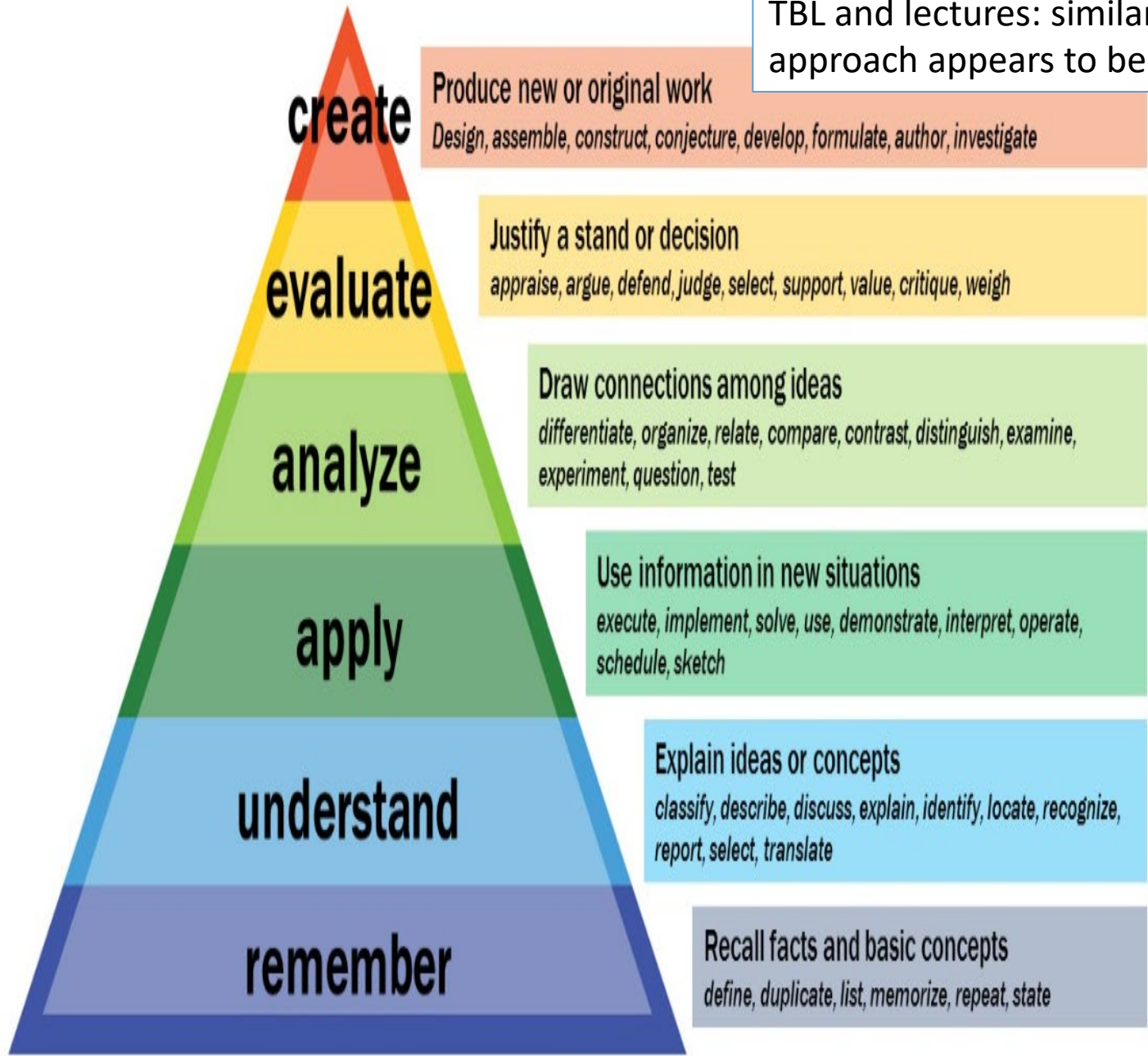
Peer Evaluation Review

After class





TBL and lectures: similar faculty resource requirement, but lecture-based approach appears to be less effective, thus less cost-effective.



Source: National Training Laboratories, Bethel, Maine

Readiness Assurance Test

work in groups

Q#1: Starting an angiotensin-converting enzyme inhibitor evokes a marked increase in serum creatinine in a patient with recent rapid development of hypertension. Which is most likely?

A chronic kidney disease

B coarctation of the aorta

C renal artery stenosis

D pheochromocytoma

E primary hyperaldosteronism

Q#2: A young woman with Turner syndrome has developed treatment-resistant hypertension. Her arm pulses are noticeably stronger than leg pulses. CXR shows rib notching. Which is most likely?

A chronic kidney disease

B coarctation of the aorta

C pheochromocytoma

D primary hyperaldosteronism

E renal artery stenosis

Q#3: Antihypertensive drugs have achieved good blood pressure control in a woman with pre-gestational hypertension, but nausea prompted her to get a pregnancy test. She's pregnant. Which drug should be stopped?

A ACE-inhibitors

B beta-blockers

C calcium channel blockers

D diuretics

E all antihypertensive drugs!!!

Q#4: A woman of African-American ancestry has developed new onset hypertension, proteinuria and peripheral edema in the third trimester of twin pregnancy. Which is most likely?

A gestational hypertension

B eclampsia

C pheochromocytoma

D primary hypertension

E preeclampsia

Q#5: A woman 6 weeks postpartum has increasingly frequent and severe bouts of unprovoked anxiety, sweats, tachycardia, tremor, nausea and pounding headaches. During an episode, her blood pressure spiked to 190/110. Priority work-up is for...?

A gestational hypertension

B eclampsia

C preeclampsia

D pheochromocytoma

E psychiatric anxiety/panic disorder

Q#6: Which enzyme prevents cortisol from reaching mineralocorticosteroid responsive elements in the kidney?

A 5-alpha reductase

B aromatic-L-amino acid
decarboxylase

C renin

D 11-beta-hydroxysteroid
dehydrogenase

E tyrosine hydroxylase



Q#7: Which enzyme catalyzes the rate-limiting step in catecholamine synthesis?



A tyrosine hydroxylase

B aromatic-L-amino acid
decarboxylase

C dopamine
beta-hydroxylase

D phenylethanolamin
e-N-methyltransferase

E 11-beta-hydroxysteroid
dehydrogenase

Q#8: Which receptors will need to be blocked preoperatively to prevent intraoperative hypertensive crisis in a pheochromocytoma patient?

A beta-adrenergic receptors

B alpha-adrenergic receptors

C cholinergic receptors

D dopaminergic receptors

E mineralocorticosteroid receptors

Q#9: Which receptors will need to be blocked preoperatively to prevent intraoperative cardiac tachyarrhythmias in a pheochromocytoma patient?

A alpha-adrenergic receptors

B cholinergic receptors

C dopaminergic receptors

D beta-adrenergic receptors

E mineralocorticosteroid receptors



Q#10: Which receptors are primarily responsible for clinical features in primary hyperaldosteronism?

A alpha-adrenergic

B mineralocorticosteroid

C beta-adrenergic

D glucocorticosteroid

E 11-beta-hydroxysteroid

Secondary Hypertension

Worked Case Examples

Case 1

ID: 36 y.o. man in clinic for insurance physical.

HPI: self-described health-conscious guy committed to regular resistance and endurance exercise, probiotics, organic only groceries, no prescription or OTC medications, no tobacco or alcohol. Prefers natural and herbal alternatives. He uses natural organic licorice and synthetic non-caloric sweeteners in place of sugar.

Work-up:

lying and standing BP 144-148/94-96, no orthostasis

2+ ankle edema

serum sodium: 141 mmol/L [135-145 mmol/L]

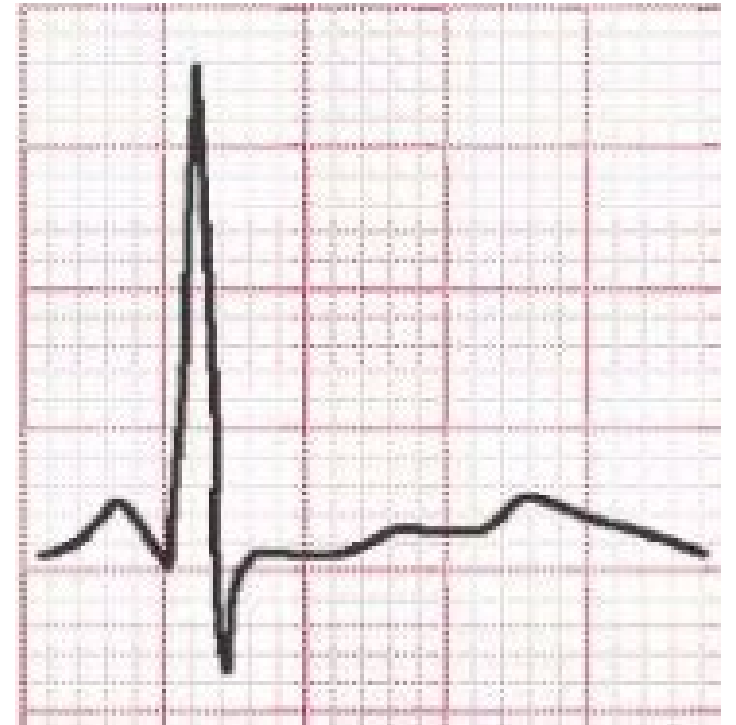
serum potassium: 3.1 mmol/L [3.5 – 5.0 mmol/L]

aldosterone: Upright 8 ng/dL [4-31 ng/mL]

plasma renin activity: Upright 1.0 ng/mL/hr [0.8 – 5.8 ng/mL/hr]

venous pH: 7.34 [7.32-7.43]

ECG is what you see.....



mineralocorticoid hypertension typically includes sustained BP elevation, increased urinary excretion of potassium which can result in hypokalemia, and metabolic alkalosis.

Causes include:

Renin-producing pathologies

renin-secreting tumors (rare)

coarctation of aorta

Aldosterone-producing pathologies

primary aldosteronism (Conns syndrome)

familial hyperaldosteronism 1, 2, and 3

Non-aldosterone mineralocorticoid producing pathologies

Liddle syndrome

ectopic adrenocorticotrophic hormones (ACTH) syndrome

congenital adrenal hyperplasia

Drugs with mineralocorticoid activity

licorice

carbenoxolone therapy

Glucocorticoid receptor resistance syndromes (rare)

Which is most likely in this case?

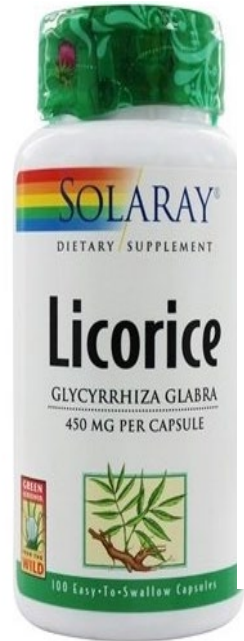
A primary hyperaldosteronism

B secondary hyperaldosteronism

C exogenous inhibitors of 11-beta-hydroxysteroid dehydrogenase inhibition e.g., plant-derived glycyrrhizate, glycyrrhetic acid hemisuccinate, ...

D exogenous or endogenous excess mineralocorticoid steroid e.g., fludrocortisone, , deoxycorticosterone, Cushing syndrome

E syndrome of apparent mineralocorticoid excess (AME, hereditary)



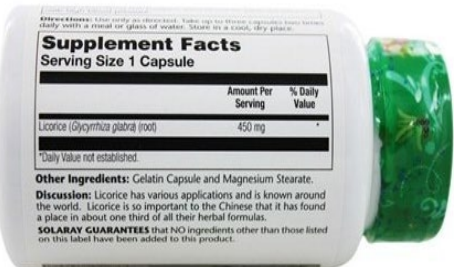Aldosterone and cortisol are equi-efficacious agonists at mineralocorticoid response elements in the distal nephron.

Although cortisol circulates at up to 100-times higher concentration than aldosterone, cortisol does not normally exert mineralocorticoid effects because renal tubular 11-beta-hydroxysteroid dehydrogenase-2 enzyme activity effectively converts cortisol to cortisone. Cortisone has no mineralocorticoid activity.

Renal tubular 11-beta-hydroxysteroid dehydrogenase-2 enzyme activity thus protects the mineralocorticoid receptors in the distal nephron from responding to normal circulating cortisol.

Several species of licorice root (*Glycyrrhizia sp*) contain glycyrrizoids (e.g., glycyrrizic acid and glycyrretic acid), which are 50 times as sweet as sucrose. They specifically inhibit 11-beta-hydroxysteroid dehydrogenase-2.

Glycyrrhizoids dose-dependently produce a syndrome of mineralocorticoid excess, which includes sodium and water retention, hypertension and hypokalemia, which can be distinguished from primary hyperaldosteronism on the basis of history of consumption of glycyrrizoid-containing food, food-additive and tobacco products, and low/low normal aldosterone and PRA.



Supplement Facts

Serving Size 1 Capsule

	Amount Per Serving	% Daily Value
Licorice (Glycyrrhiza glabra root)	450 mg	*

*Daily Value not established.
Other Ingredients: Gelatin Capsule and Magnesium Stearate.
Discussion: Licorice has various applications and is known around the world. Licorice is so important to the Chinese that it has found a place in about one third of all their herbal formulas.
SOLARAY GUARANTEES that NO ingredients other than those listed on this label have been added to this product.

Secondary Hypertension

Worked Case Examples

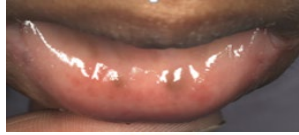Case 2

A 20-y.o. female martial arts competitor with mid-diaphyseal # left ulna has marked blood pressure elevation during pre-op work-up for ORIF.

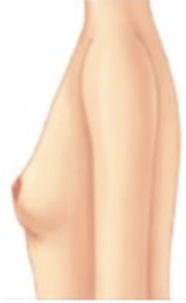PMH: Born in USA to Korean parents, both of Han Chinese ancestry.

Normal childhood development until lack of changes associated with puberty: no breast development, no menarche, no pubic or axillary hair prompted a pediatrician to initiate cyclic estrogen supplementation, followed by sequential progesterone. Thereafter, she had irregular menses, modest breast development, and a growth spurt.

By age 18 she was taller than her parents and older brother.



Hyperpigmentation of oral mucosa



No pubic or axillary hair.

Breast dvpt at Tanner stage II-III

Hght: 174 cm. Wght: 64 Kg. BMI: 21 Kg/m².

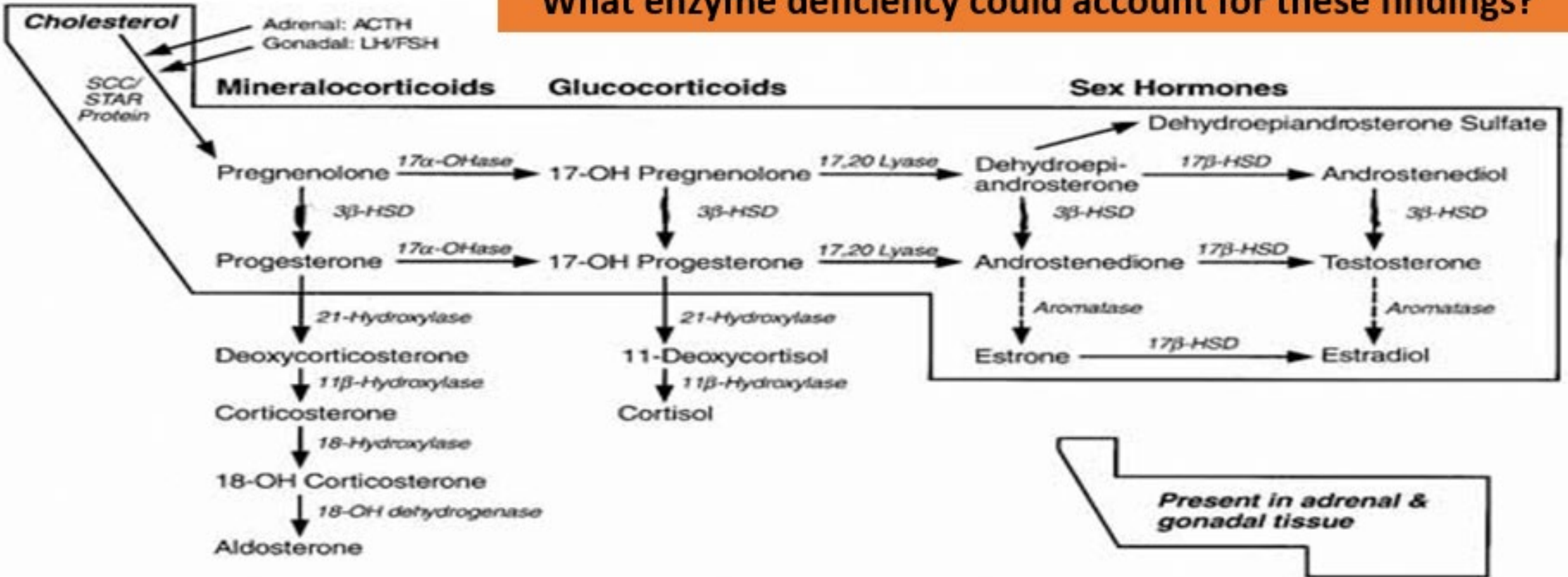
BP: 162/104 HR: 66 RR: 18 T: 36.8 C.

Long limbs in relation to torso (“Barbie” habitus).

<u>Test</u>	<u>Result</u>	<u>Ref. Range</u>
aldosterone	< 7-0 <u>pmol/L</u>	100-900 standing
renin (mass)	<2 <u>mU/L</u>	2-29
ACTH	500 ng/L	10-50
cortisol	18 <u>mmol/L</u>	200-700
FSH	49 U/L	1-8
LH	21 U/L	1-12
estradiol	< 30 <u>pmol/L</u>	> 85
progesterone	51 <u>nmol/L</u>	1-4.8
17-hydroxyprogesterone	< 0.3 <u>nmol/L</u>	< 0.3
<u>dehydroepiandrosterone</u>	< 0.5 <u>µmo/L</u>	1-11
testosterone	0.5 <u>nmol/L</u>	0.3-2.6
potassium	2.8 <u>mmol/L</u>	3.5-5.0
abdominal CT scan: atrophic uterus. bulky adrenal glands.		
ECG: Sinus 66, flattened low amplitude T-waves, U-waves, prolonged <u>QTc</u> .		

low renin hypertension
 very low aldosterone
 hypokalemia
 very low cortisol; high ACTH, adrenal hyperplasia
 very low estrogen, low-normal testosterone; high LH & FSH (gonadotropins)
 low dehydroepiandrosterone

What enzyme deficiency could account for these findings?



What steroidogenic enzyme deficiency could account for these findings?

A 21-hydroxylase deficiency

B 17-alpha-hydroxylase deficiency

C 17-beta-hydroxysteroid dehydrogenase deficiency

D 17,20 lyase deficiency

E 1-beta-hydroxysteroid dehydrogenase deficiency

Let's unpack this case:

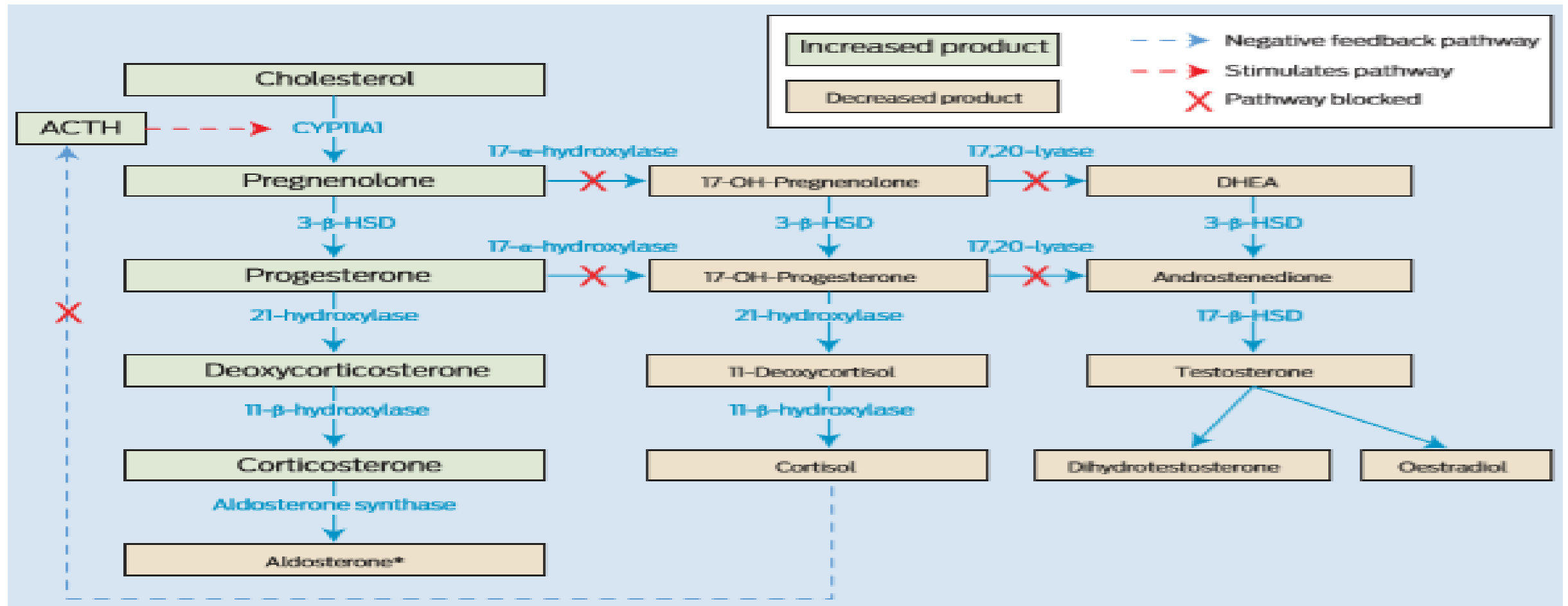
If it's 21-hydroxylase deficiency, we'd expect substrate diversion toward excess sex steroids, and how can you explain the hypokalemia and low-renin hypertension?

Test	Result	Ref. Range
aldosterone	< 7-0 <u>pmol/L</u>	100-900 standing
renin (mass)	<2 <u>mU/L</u>	2-29
ACTH	500 ng/L	10-50
cortisol	18 <u>mmol/L</u>	200-700
FSH	49 U/L	1-8
LH	21 U/L	1-12
estradiol	< 30 <u>pmol/L</u>	> 85
progesterone	51 <u>nmol/L</u>	1-4.8
17-hydroxyprogesterone	< 0.3 <u>nmol/L</u>	< 0.3
<u>dehydroepiandrosterone</u>	< 0.5 <u>µmo/L</u>	1-11
testosterone	0.5 <u>nmol/L</u>	0.3-2.6
potassium	2.8 <u>mmol/L</u>	3.5-5.0
abdominal CT scan: atrophic uterus. bulky adrenal glands.		
ECG: Sinus 66, flattened low amplitude T-waves, U-waves, prolonged <u>QTc</u> .		

There is no logical explanation for how 21-hydroxylase deficiency could account for the constellation of findings in this case.

Let's review the consequences of 17-alpha-hydroxylase deficiency:

- Which hormones will be deficient?
- Which hormones will be synthesized in excess?



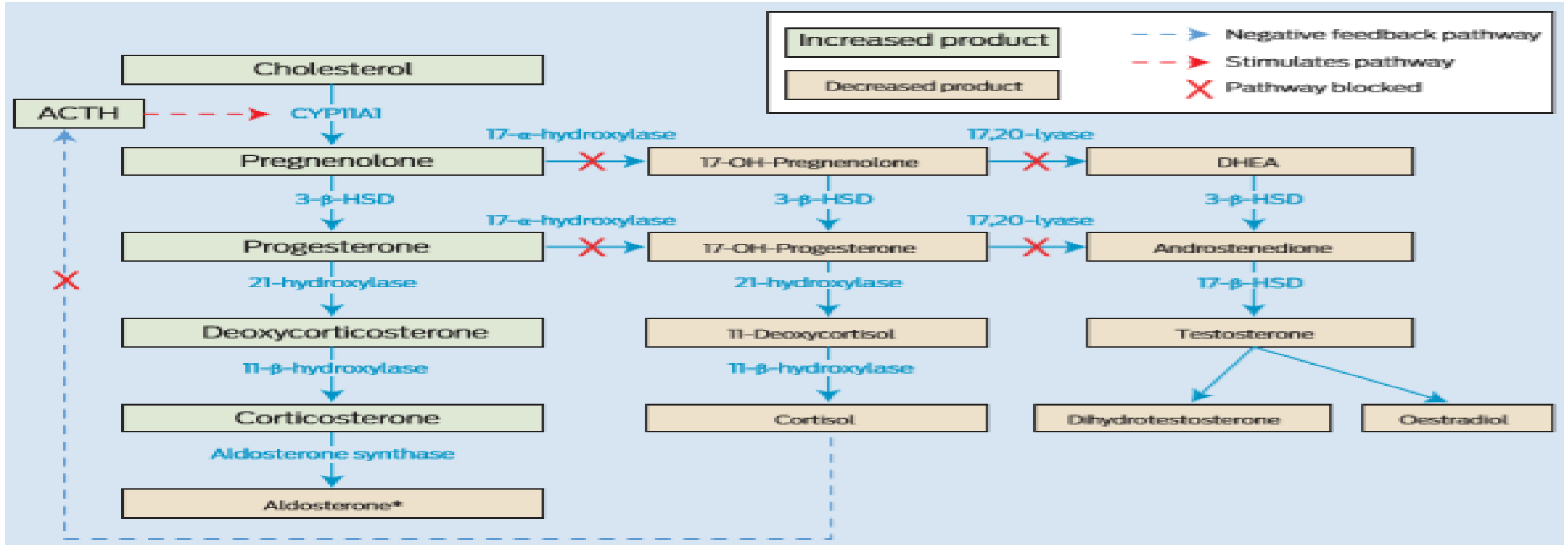
Let's review the consequences of 17-alpha-hydroxylase deficiency:

- Which hormones will be deficient?

gonadal sex steroids, adrenal cortical androgens & estrogens, cortisol, and aldosterone.

- Which hormones will be synthesized in excess?

**pregnenolone, progesterone, in both gonadal and adrenal cortical tissues
deoxycorticosterone, and corticosterone in the adrenal cortex.**



Let's unpack this case:

Why was ACTH markedly elevated?

Let's unpack this case:

Why was ACTH markedly elevated?

Lack of cortisol results in lack of feedback inhibition of pituitary ACTH release.

ACTH is the primary stimulus for adrenal steroidogenesis, except aldosterone which is regulated by angiotensin II.

Luteinizing hormone is the primary stimulus for gonadal steroidogenesis.

Let's unpack this case:

Why is ACTH excess associated with hyperpigmentation?

Let's unpack this case:

Why is ACTH excess associated with hyperpigmentation?

Lack of cortisol feedback inhibition disinhibits a pituitary gene that codes for the hormone precursor, pro-opiomelanocortin, from which ACTH, beta-endorphin and melanocyte stimulating hormone are all derived, so whenever the gene is disinhibited to produce excess cortisol, there will be excess MSH to stimulate melanocytes to induce pigmentation.

Pigmentation may be localized to oral mucosa and intertriginous skin (i.e., folds and creases) and areas subject to pressure (e.g., belt, bra, butt).

Let's unpack this case:

If it is 17-alpha-hydroxylase, how can you explain the hypokalemia and low-renin hypertension in the context of very low aldosterone?

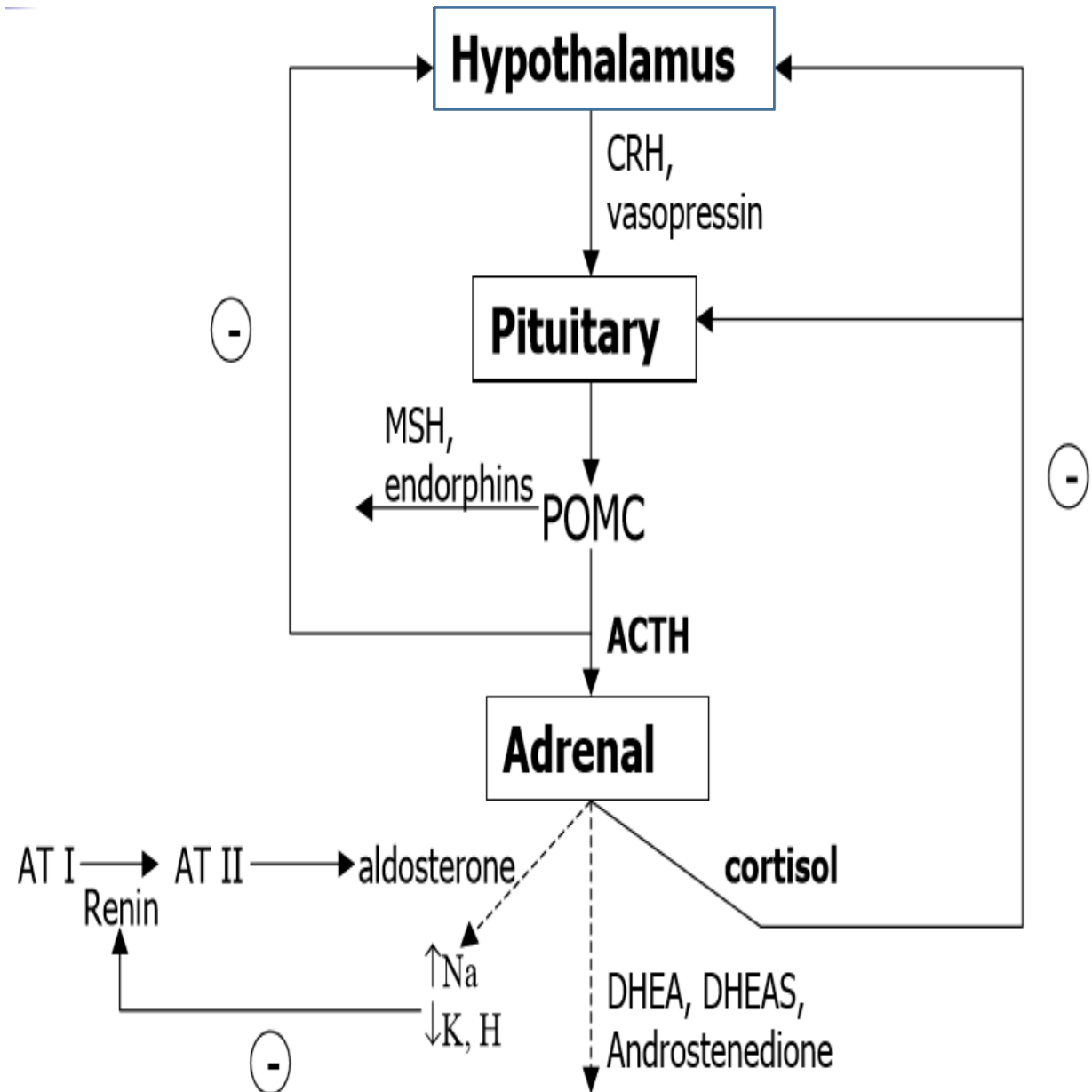
Let's unpack this case:

If it is 17-alpha-hydroxylase, how can you explain the hypokalemia and low-renin hypertension in the context of very low aldosterone?

The key is that deoxycorticosterone and corticosterone and 18-hydroxyl-corticosterone each have incremental mineralocorticoid activity, so aldosterone is usually suppressed due to salt retention and volume expansion, which via the macula densa will inhibit renin release from the juxtaglomerular apparatus.

No renin, no angiotensin II: angiotensin II is the principal regulator of aldosterone synthase (18-hydroxyl dehydrogenase) activity and aldosterone secretion from the adrenal zona glomerulosa.

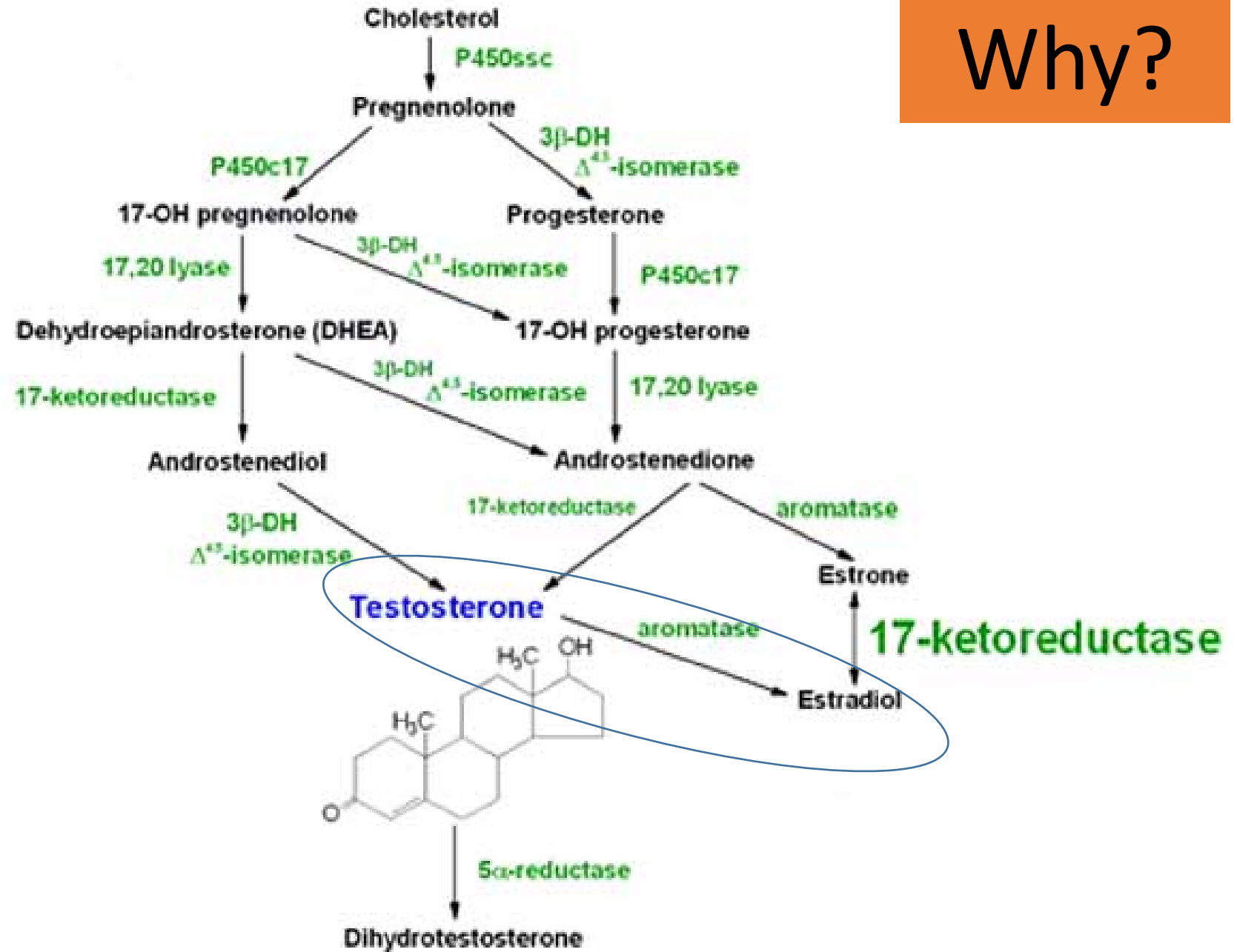
Remember: ACTH directly regulates cortisol production and release, but it is primarily angiotensin II that regulates aldosterone synthesis and release.



Like Barbie, the patient has long limbs in relation to the length of her torso.



Why?



Vertebral height is partially dependent on sex hormones (puberty), and since puberty was delayed, vertebral growth was diminished until the pediatrician started estrogen and progesterin at age 16 y.o.

The growing length of long bones is driven by somatotrophin (i.e., growth hormone) and somatomedins (insulin-like growth factors) until epiphyseal closure. Estrogens accelerate epiphyseal closure, which normally occurs after puberty. That is one factor for why females tend not to continue to grow taller for as long as males. Another factor, is that androgens potentiate the growth-promoting effect of the growth hormones.

The patient in this case had normal production of growth hormones, and she grew taller than her parents and brother with long legs that more than compensated for vertebral height being less than if she had normal sex hormone production.

In children of abnormally short stature who are growth hormone deficient, rhGH replacement on a background of uneven endogenous sex-hormones can result in scoliosis due to uneven vertebral height.





Treatment: physiologic corticosteroid replacement, titrated to optimize glucocorticoid/mineralocorticoid homeostasis.

- replacement reduces ACTH, and will therefore resolve the excess mineralocorticoid effects of progesterone over-production and diversion down the corticosterone pathway.
- Add spironolactone until BP and K⁺ normalize.
- replacement reduces ACTH, and will therefore prevent and reverse hyperpigmentation.

In this case, initial therapy is with estrogen alone to maximize breast growth and induce uterine/endometrial development. Low starting dose of estrogen because higher doses will cause premature epiphyseal closure. Predicted adult height is greater if puberty occurs later.

- After completion of breast development, a progestin is added to mimic the normal (regular) menstrual cycle and prevent the endometrial hyperplasia and irregular bleeding associated with estrogen alone once menses occur. Adding a progestin before breast development is complete is likely to reduce mature breast size.
- Later, contraceptives provide estrogen and progesterone in a combination that can be individualized to meet the replacement needs of the patient: After 6 mo. add progestogen (e.g., levonorgestrel) during the last 12-14 days of the menstrual cycle to prevent abnormal or excessive uterine bleeding (transforms proliferative into secretory endometrium).
- Low-dose testosterone might be considered to promote pubic hair.
- Fertility: exogenous gonadotropins or pulsatile gonadotropin releasing hormone agonists are options once tubal patency is confirmed and semen analysis is deemed adequate. They are effective for inducing ovulation in a high percentage of patients with congenital gonadotropin deficiency.

Take home points:

- diagnosis of congenital 17-hydroxylase deficiency during childhood can be missed, especially in XX females with partial enzyme insufficiency, because their external genitalia appear normal, and hypertension and hypokalemia are not routinely assessed in children.
- delayed puberty might be the first clue. Check BP and K⁺ in patients with delayed puberty.
- Untreated, 17-hydroxylase deficiency can lead to life-threatening hypokalemia, hypertension, osteoporosis and psychosocial issues.

Secondary Hypertension

Worked Case Examples

Case 3

ID: 32 y.o. medical student with a newborn

HPI: 18 month history of postural dizziness, and sudden, seemingly unprovoked episodes of anxiety accompanied by “pounding” headaches, palpitations, sweating, tremor, chest tightening, blurred vision and usually nausea. Symptoms generally subside rapidly, although headaches persist for hours.

She has certainly found it stressful to have interrupted medical school with this unplanned pregnancy. Treatment for panic disorder was initiated following referral to psychiatry, but she has since had a similar attack with near syncope. She is not feeling safe with the possibility of fainting and falling while caring for her new baby.

She wants to be worked up for a possible syndromic cardiac arrhythmia or maybe pheochromocytoma.

What constitutes a comprehensive initial work-up?


A all of the following

B ECG and ambulatory
(Holter) monitor

C lying & standing blood
pressures

D 24-hr urine &/or plasma
fractionated metanephrines

E TSH and T4



This presentation could point to more than 30 disease conditions.

If it is a pheochromocytoma, prompt diagnosis and management prevent a clinical catastrophe and provide clinical cure. Although approaches to diagnosis somewhat differ between expert camps (e.g., American Endocrine Society) and risk-stratified clinical scenarios (screening based on hereditary risk or incidentaloma vs high risk), but regardless of preferred selection and sequencing of tests, diagnosis of pheochromocytoma or paraganglioma requires both:

- biochemical proof of excess release of catecholamines, and
- anatomical localization of the tumor

Biochemical work-up options:

- 24-hr urine collection for fractionated metanephrines/normetanephrine corrected to 24-hr urine creatinine (Sn: 87.5%; Sp: 99.7%)
- plasma free metanephrines (Sn: 96%; Sp: 85%). Sp lower if the collection protocol is not followed.

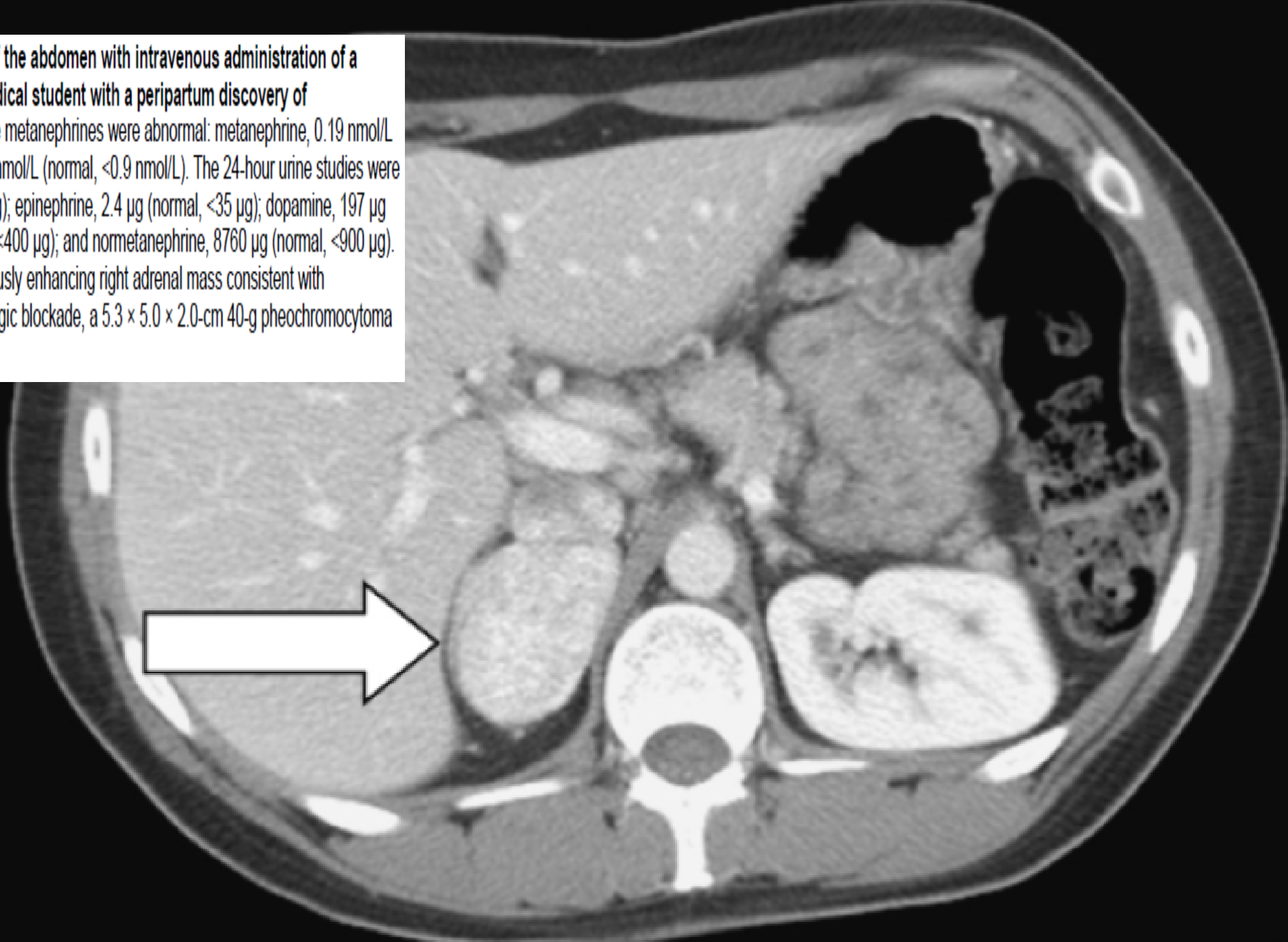
If elevated, proceed with imaging:

- abdominal contrast-enhanced CT (85-95% detection for adrenal masses > 1 cm)
- MRI (higher sensitivity than CT, and preferred option during pregnancy). pheochromocytomas appear hyperintense on T2-weighted images proportional to high water content

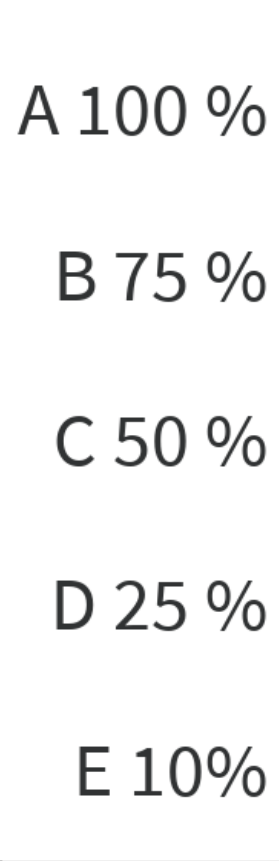
If abdominal imaging is negative in biochemically positive cases, radiolabeled metaiodobenzylguanidine (MBIG) scintigraphy scanning or positron emission tomography with 6-[18F]-fluorodopamine are highly specific.

- Neuman HPH, Young WF Jr, Eng C. Pheochromocytoma and paraganglioma. N Engl J Med 2019;381(6): 552-65. doi: 10.1056/NEJMra1806651
- Blake MA. Pheochromocytoma. Medscape eMedicine. Updated 10 August 2018. <https://emedicine.medscape.com/article/124059-workup#showall>

FIGURE 246-2 A computed tomographic scan of the abdomen with intravenous administration of a contrast agent in a 32-year-old second-year medical student with a peripartum discovery of pheochromocytoma. The fractionated plasma free metanephrines were abnormal: metanephrine, 0.19 nmol/L (normal, <0.5 nmol/L); and normetanephrine, 28.6 nmol/L (normal, <0.9 nmol/L). The 24-hour urine studies were abnormal: norepinephrine, 781 μ g (normal, <170 μ g); epinephrine, 2.4 μ g (normal, <35 μ g); dopamine, 197 μ g (normal, <700 μ g); metanephrine, 117 μ g (normal, <400 μ g); and normetanephrine, 8760 μ g (normal, <900 μ g). The axial image shows a typical 5-cm heterogeneously enhancing right adrenal mass consistent with pheochromocytoma (arrow). After α - and β -adrenergic blockade, a 5.3 \times 5.0 \times 2.0-cm 40-g pheochromocytoma was removed laparoscopically.



What were the odds that this was: (1) a malignant neoplasm, (2) associated with an inherited syndrome, (3) paraganglioma i.e., extraadrenal, (4) bilateral, (5) inoperable?



classical 'Rule of 10s':

- 10% are malignant
- 10 % familial (associated with multiple endocrine neoplasia (MEN IIa or IIb, von Hippel-Lindau syndrome, or neurofibromatosis)
- 10 % extraadrenal (i.e., paragangliomas)
- 10 % bilateral
- 10% are inoperable.

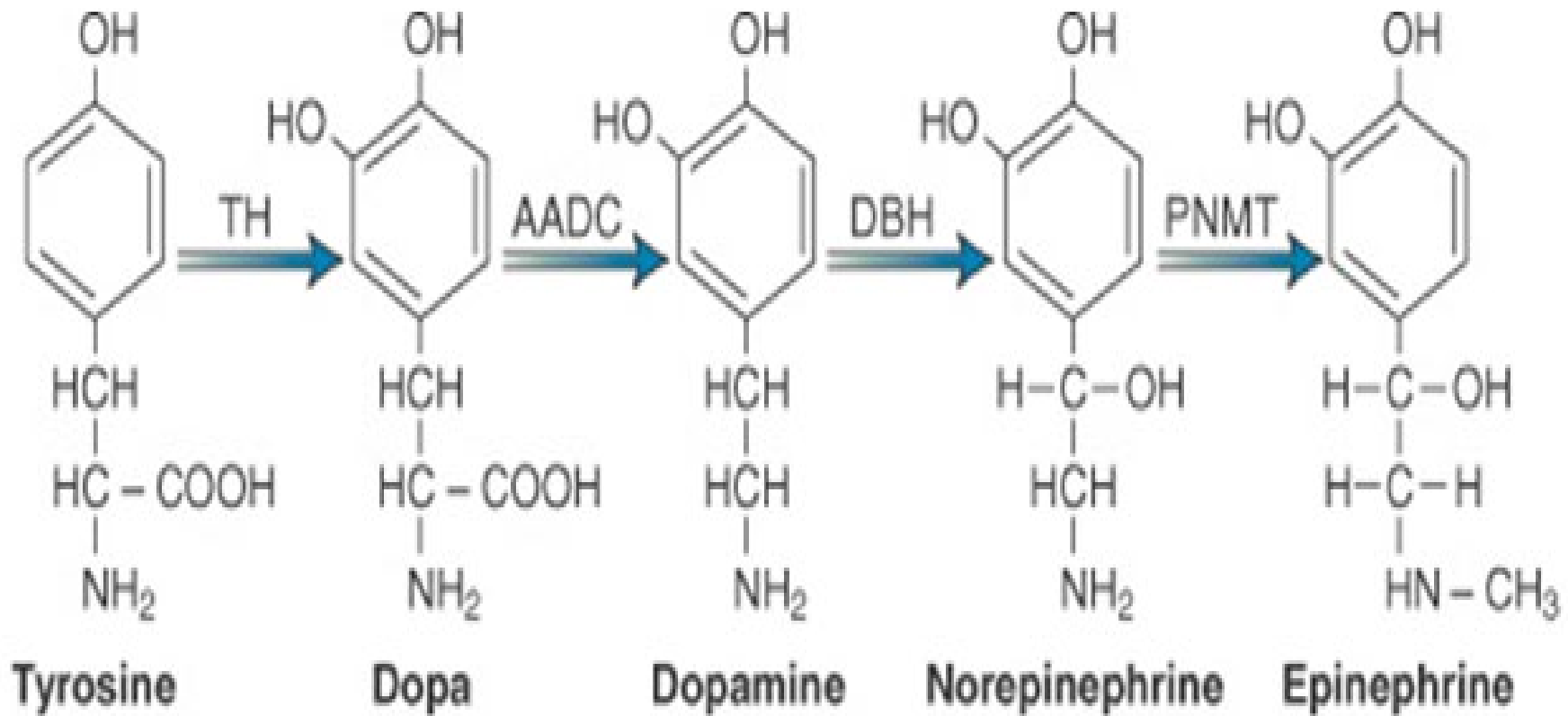
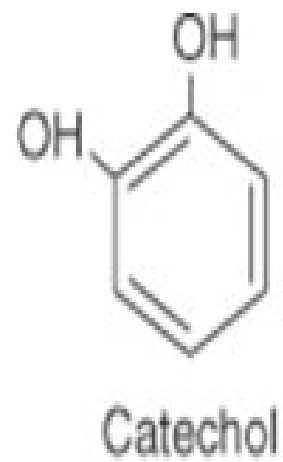


Mechanisms of Disease

Pheochromocytoma is a rare catecholamine-secreting tumor.
(Most are nonmalignant unilateral intra-adrenal tumors that are potentially curable with surgery)

Because of excessive autonomous secretion of catecholamines, pheochromocytomas may precipitate life-threatening hypertension and cardiac arrhythmias.

Let's review the synthesis and receptor-mediated effects of catecholamines as a basis for rational medical preparation prior to surgical resection:



A drug called metyrosine inhibits the rate-limiting step in catecholamine biosynthesis. Which enzyme does it inhibit?

A aromatic L-amino acid
(dopa) decarboxylase

B

dopa-beta-hydroxylase

C phenylethanolamine-N-methyltransferase

D tyrosine hydroxylase

E tyrosine
thyroperoxidase

metyrosine inhibits tyrosine hydroxylase, the rate-limiting step in catecholamine biosynthesis.

Indicated in pheochromocytoma patients awaiting surgery, for long-term management of patients with malignant pheochromocytoma, or in cases of pheochromocytoma in which surgery is contraindicated.

At doses of 1-4g/day, catecholamine synthesis is reduced by 35%-80%. Start 250 mg po qid, titrate up to 500-1000mg po qid.

Clinical effect gradual over 5-7 days.



Meanwhile, which of these drugs is immediately most important to prevent pre-op and intra-operative hypertensive crisis?

A a centrally-acting presynaptic alpha agonist e.g.,
clonidine

B a competitive alpha-adrenergic antagonist e.g.,
phentolamine or prazosin

C a beta-1-adrenergic antagonist e.g., propranolol
or esmolol

D a non-competitive postsynaptic alpha-adrenergic
receptor antagonist e.g., phenoxybenzamine

E a beta-2-adrenergic agonist e.g., albuterol or
fomoterol

phenoxybenzamine is a long-acting **non-competitive alpha- adrenergic receptor antagonist** used to produce and maintain chemical sympathectomy.

- hypotension and orthostatic hypotension are problematic because phenoxybenzamine lowers supine and upright blood pressure.
- reflex tachycardia is also problematic, and may require the addition of a beta blocker

In the context of autonomous release of catecholamines from a pheochromocytoma, would it matter whether you choose a competitive or non-competitive alpha adrenergic antagonist?

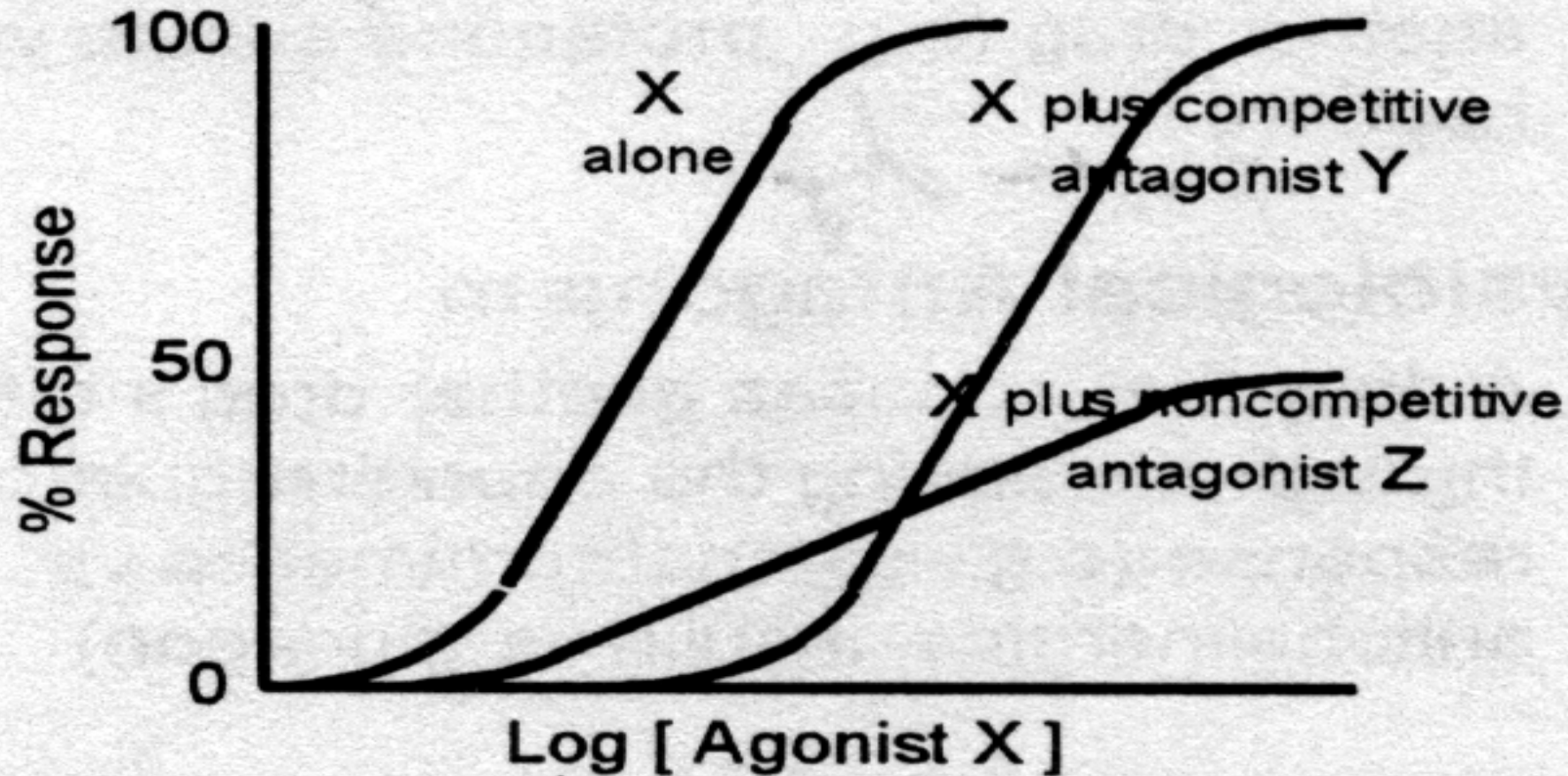
A Yes, because excessive catecholamine release would overwhelm competitive antagonism, but not non-competitive antagonism

B No, because they act at the same receptors

C No, because the effect of autonomous surge of catecholamine can always be suppressed by increasing the dose of a competitive antagonist

D Yes, because excessive catecholamine release would overwhelm non-competitive antagonism, but not competitive antagonism

Competitive antagonists cause a parallel rightward shift in the apparent potency of an agonist without changing the maximum effect that can be achieved with a higher dose of the agonist. Pheochromocytomas can automatically release overwhelming concentrations of norepinephrine and epinephrine. A **noncompetitive antagonist** can't be pushed off the receptor, so the maximum effect is not going to be reached no matter how much catecholamine is released by the tumor.





Which receptors must be blocked to prevent catecholamine-evoked tachyarrhythmias?



A postsynaptic
alpha-1-adrenergic

B beta-1-adrenergic

C presynaptic
alpha-1-adrenergic

D beta-2-adrenergic

E muscarinic (M2)
cholinergic

Both alpha- and beta- adrenergic receptor antagonists are indicated in pre-operative management of pheochromocytoma, but it matters which order they are initiated:

Remember: A (alpha) comes before B (beta).

If the vasodilatory beta-adrenergic effect in skeletal muscle vascular beds is blocked by a beta-blocker prior to alpha-blockade, the unopposed alpha-adrenergic increase in vascular resistance can potentially exacerbate hypertension.

Surgical resection of the tumor is the treatment of choice for pheochromocytoma and usually results in cure.

- Laparoscopic adrenalectomy should be performed for most adrenal pheochromocytomas, with open resection reserved for paragangliomas and large/invasive pheochromocytomas
- partial adrenalectomy is also an option for certain patients

Careful preoperative management is required to control blood pressure and heart rate/rhythm, and prevent intraoperative hypertensive crises, plus a high-sodium diet with high fluid intake to prevent severe hypotension after removal of the tumor.

Secondary Hypertension

Worked Case Examples

Case 4

Presenting Concern

- **46 y.o. ♀ with sudden onset dyspnea**

History of Present Illness

- Difficult to control hypertension (taking three antihypertensive drugs).
- During past 3 weeks: daytime ankle swelling, bedtime cough, and morning headaches.
- Emergency room visit 4 months ago for racing heart; sent home on a beta-blocker.

Past Medical History

Past Medical History

- Longstanding hypertension, treated with perindopril 5 mg once daily, indapamide 1.25 mg once daily for last 3-4 years, added amlodipine 5 mg once-daily x 4 months. Was told by an internist that there's a significant white coat component (trends 148/90 @home, 156-170/90-94 in clinic). An ambulatory BP monitoring report is on file (dated 4 months ago, just before amlodipine was added).
- Benign supraventricular tachycardia: metoprolol 150 mg BID x 4 months.

Past Surgical History: nil

Family/Social History: nothing remarkable.

Ambulatory Blood Pressure Report

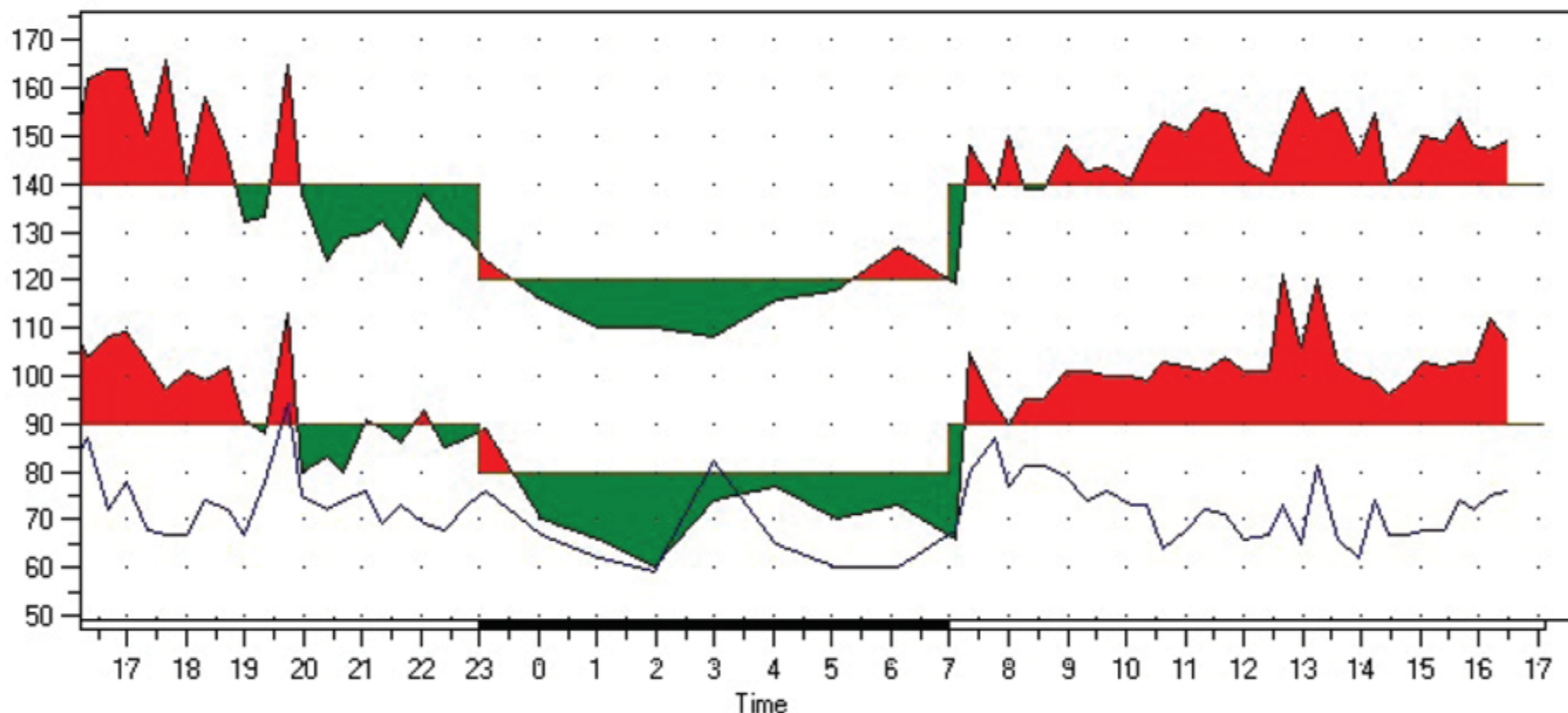
Patient Name: XXXXXX-XXXXXX Patient ID: 98-719-Ptc45 Test Date: 04-APR-2019 / Report Date: 29-APR-2019

Start Time: 16:13 04-APR-2019 End Time: 16:30 05-APR-2019 Duration: 24h17m Samples: 60/60 (100%)

Summary:

mmHg-bpm

ABP data



Summary:

Average awake: 146/99 mmHg. HR 73 bpm sBP High: 166 mmHg. dBP High: 121 mmHg. sBP Low: 119 mmHg. dBP Low: 66 mmHg.

Average asleep: 126/72 mmHg. HR 66 bpm sBP High: 134 mmHg. dBP High: 89 mmHg. sBP Low: 108 mmHg. dBP Low: 62 mmHg

Overall BP Load: 63% Sys, 72%Dia > 140/90 mmHg while awake, and 120/80 mmHg while asleep

Clinical Interpretation: Stage 2 hypertension |

Physical Examination

Vital Signs:

196/100 36.9 °C (98.4 °F)_{oral}/94/22

SpO₂ 94% on O₂@2 Lpm/nasal cannula

- jugular venous pressure 5 cm (elevated)
- bounding carotid pulse
- Gr 2/6 mid-peaking systolic murmur heard @ LSB, suprasternal notch and below left scapula
- rales (crackles) lower lung fields bilaterally
- femoral pulses present but weak, pedal pulses absent
- mild lower leg edema



Which of the following hypertension definitions can be applied based on H&P?

A unconfirmed (suspected) hypertension

B white-coat hypertension

C primary hypertension

D hypertensive urgency or emergency

E secondary hypertension

This patient presents with hypertensive urgency.

History of longstanding treatment-resistant hypertension, confirmed Stage 2 (ABPM).

Vital Signs: **196/100** 36.9 °C (98.4 °F)_{oral}/94/22 SpO₂ 94% on O₂@2 Lpm/nasal cannula

hypertensive urgency (> 180 / > 120 mmHg, severe asymptomatic hypertension), often headache, but no other signs or symptoms of acute end-organ dysfunction.

hypertensive emergency (severe symptomatic hypertension, no specific threshold, but usually > 180 / > 120 mmHg), associated with signs of acute progressive target organ dysfunction: encephalopathy, papilloedema, retinopathy, nephropathy, chest pain, pulmonary edema, aortic dissection, arterial aneurism.

Blood pressure categories, ACC/AHA 2017 clinical practice guidelines and diagnostic thresholds:

- **normal** (<120/<80mmHg), **elevated** (120-129/>80mmHg)
- **hypertension:**
 - stage 1 (130-139 / 80-89 mmHg),
 - stage 2 (≥ 140 / ≥ 90 mmHg)
 - diabetes &/or chronic kidney disease (≥ 130 / ≥ 80 mmHg)
 - elderly isolated systolic hypertension (< 160 mmHg)

White coat effect was clearly demonstrated, but white coat hypertension was definitively excluded by the ABPM: A substantial minority of people will consistently have a pressor or depressor reaction to being in a clinical environment.

- **White coat hypertension** (syn. isolated clinic hypertension) describes individuals with arterial pressure that is persistently in the hypertensive range when measured in a clinical environment, if otherwise consistently normal average blood pressure measurements are obtained away from that setting.

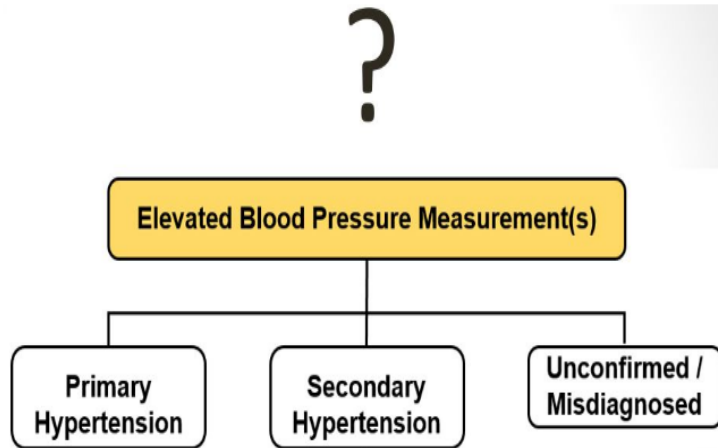
Moved to quiet environment.

Guided relaxation provided by nurse.

Amlodipine increased to 10 mg daily.

Consider stopping perindopril (pros & cons)

What category?



A unconfirmed hypertension

B true hypertension, category not yet determined

C misdiagnosed hypertension

D primary hypertension

E secondary hypertension

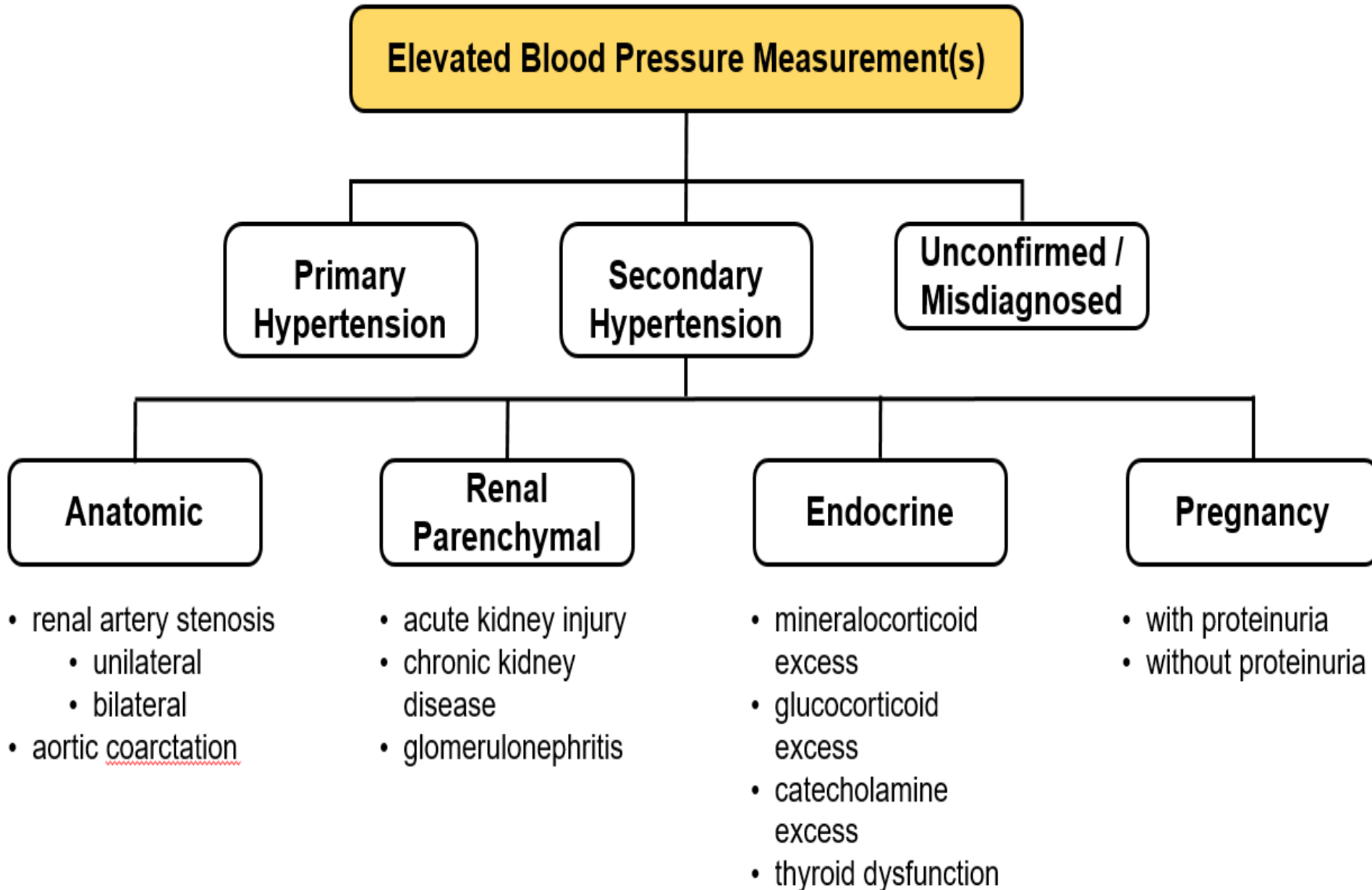
True hypertension, category not yet determined

Secondary hypertension means confirmed sustained blood pressure elevation secondary to an identifiable and potentially remediable etiology. [Case: not yet Dx]

Clues that sustained blood pressure elevation might denote secondary rather than primary hypertension:

- treatment-refractory hypertension: drugs for primary hypertension are not effective for treating secondary forms of hypertension, so an inadequate response to combining three or more antihypertensive drugs should prompt work-up for secondary forms of hypertension
- abrupt onset of hypertension
- onset in patients under 30 years of age, especially if female (onset of primary hypertension is typically gradual after age 50, so a young woman on no drugs with no family history of hypertension has a fairly high probability of fibromuscular dysplasia causing renal artery stenosis)
- recent marked blood pressure increase in an older patient with previously well-controlled primary hypertension (rapid persistent worsening of hypertension after age 55 suggests atherosclerotic renal artery stenosis, especially men at higher composite cardiovascular disease risk)
- consider potential for commonly prescribed drugs to induce or aggravate hypertension:

Enough clues are leaning toward a secondary cause to justify a systematic work-up.



Clues are leaning toward secondary cause. Based on H&P, which type seems more likely?

A anatomic

B renal
parenchymal

C endocrine

D pregnancy

anatomic: only a vascular defect could account for the carotid-femoral pulse pressure differential. The congestive hemodynamic features (dyspnea, decreased Hb sat., creps, lower leg edema, ECG: LV strain, and mild renal insufficiency) are consequences.

Although pregnancy would not explain the above features of the case, pregnancy could be an exacerbating condition that would magnify risk for vascular catastrophe stemming from a vascular defect.

Kidney failure (renal parenchymal diseases) would not explain this presentation, particularly because urea and creatinine were only upper normal.

No features consistent with glucocorticoid, mineralocorticoid, thyroid or catecholamine excess.

Which anatomic cause of hypertension seems most likely?

Anatomic

- renal artery stenosis
 - unilateral
 - bilateral
- aortic coarctation

A brain injury
(Cushing reflex)

B unilateral renal
artery stenosis

C bilateral renal
artery stenosis

D aortic
coarctation

E obstructive
sleep apnea

Coarctation of the aorta is a constricted aortic segment, most commonly located in the thoracic aorta distal to the origin of the left subclavian artery at about the level of the ductal structure.

- Poststenotic dilatation immediately distal to the coarctation is usually present (murmur/bruit).
- Coarctation of the thoracic aorta essentially diverts cardiac output to the upper body, and proportionally deprives the lower arterial tree. It imposes substantial afterload on the left ventricle, and explains the pulse pressure differential between upper and lower limbs.
- Plasma renin activity is consistently elevated. Activation of the renin-angiotensin system secondary to reduction of renal blood flow appears to explain most of the hypertension.

further work-up

blood chemistry: creatinine and urea near ULN, otherwise wNL

ECG: increased S waves in leads V5 and V6, LV strain/borderline posterobasal LV hypertrophy

Echocardiography delineates intracardiac anatomy and allows assessment of associated significant intracardiac anomalies. The suprasternal notch 2-dimensional echocardiographic view allows evaluation of the aortic arch to assess the transverse aortic arch, isthmus, and severity of coarctation. Doppler echocardiography is used to measure the gradient at the site of coarctation and to identify the pattern of diastolic runoff typically seen in patients with severe obstruction.

Laboratory and Test Results

Diagnostic Studies

CXR: pulmonary edema

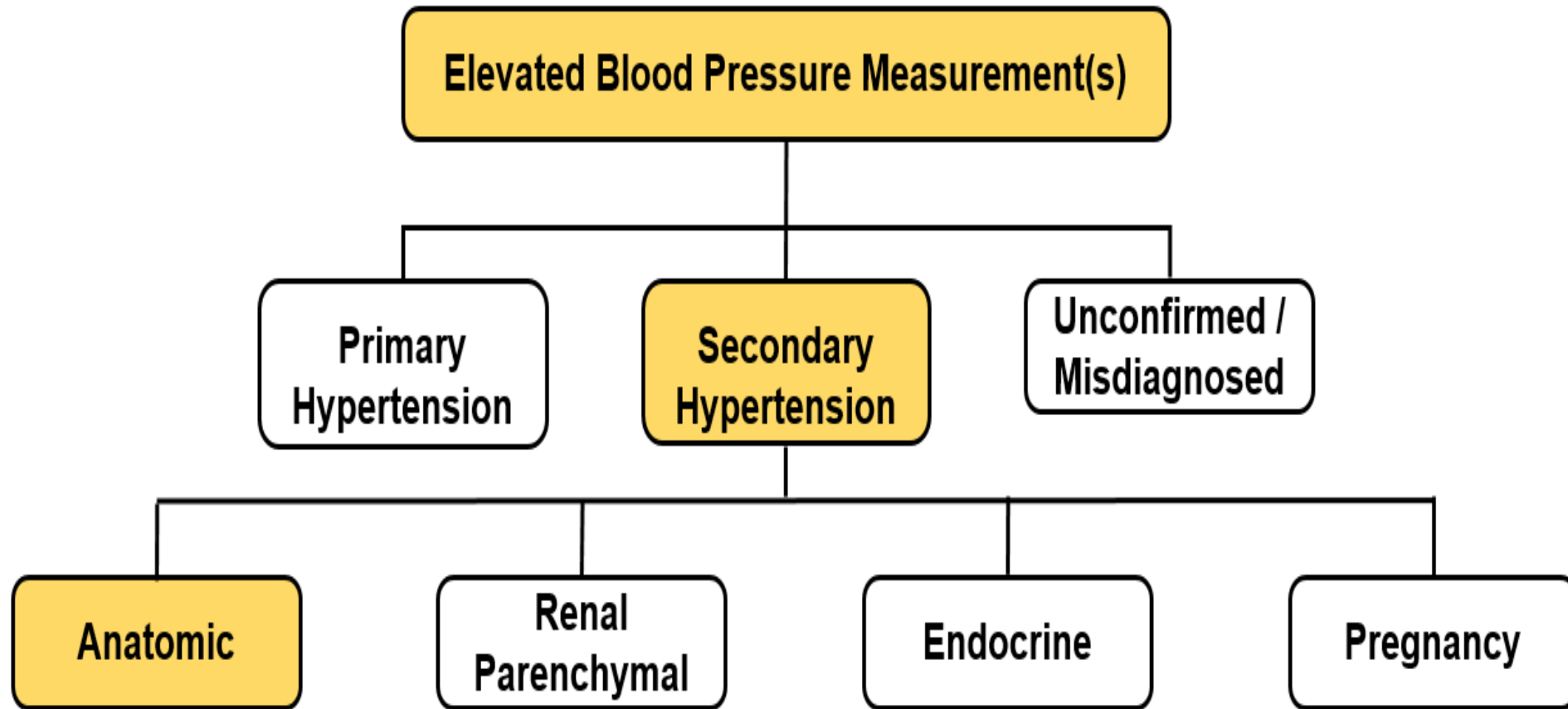
ECG: LBBB, LV strain pattern, no LVH

Transthoracic echocardiogram/Doppler: narrowing of aorta distal to the left subclavian artery (10 mm at narrowest point) with postductal dilatation.

Laboratory data:

- troponin slightly elevated


compare arterial pressures in upper & lower limbs: upper 28 mm Hg > lower



- renal artery stenosis
 - unilateral
 - bilateral
- aortic coarctation

What is the Final Diagnosis ?

What are the pertinent findings from the history, physical examination, and laboratory data?



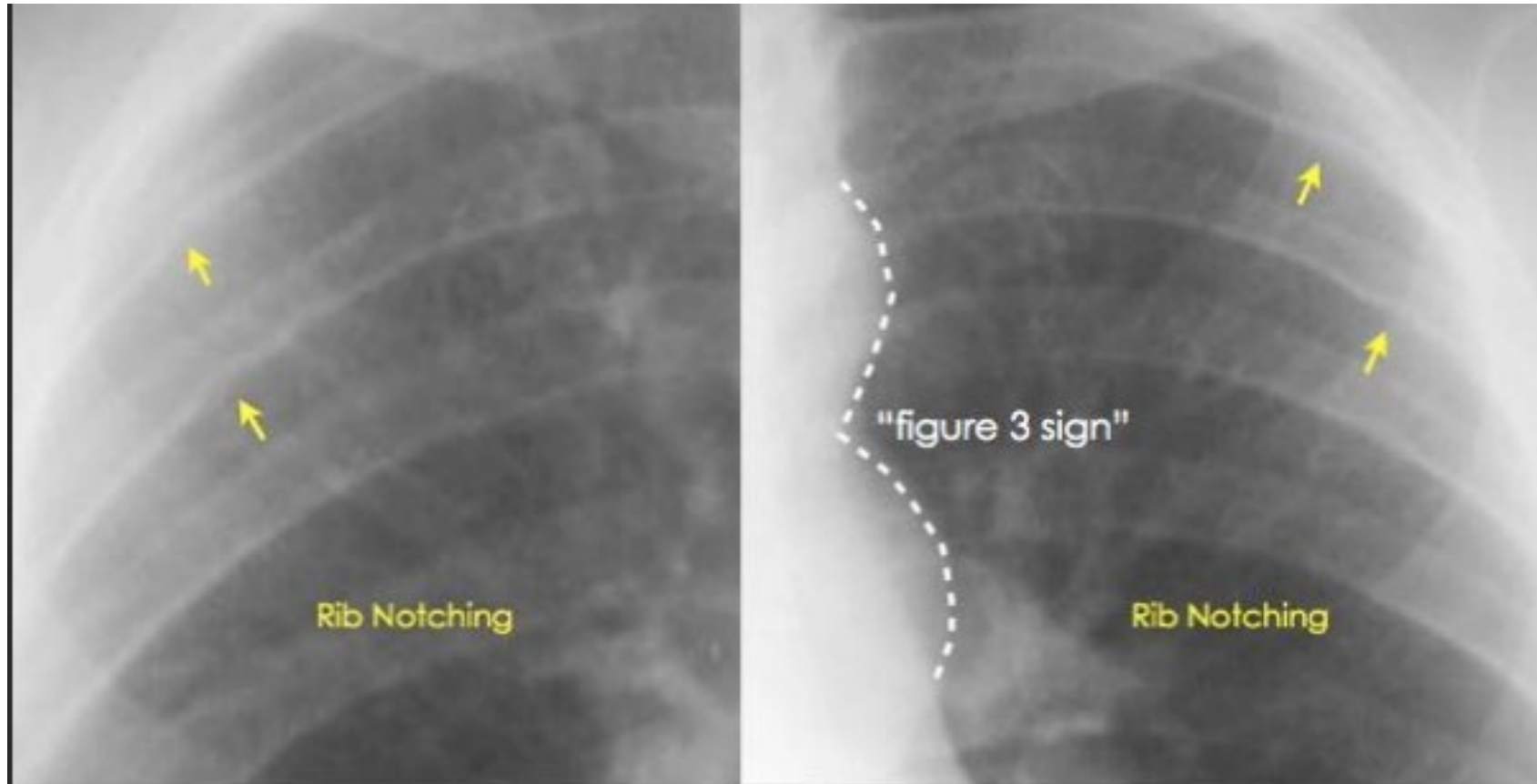
Classically, aortic coarctation manifests in early infancy because closure of the ductus arteriosus causes sudden hemodynamic compromise.

Undiagnosed adults are commonly hypertensive and resistant to BP-lowering drugs, but remain asymptomatic until heart failure (sudden onset dyspnea, ankle swelling), aortic dissection, or extremity claudication ensues.

Suspicious findings that merit investigation:

- Continuous or systolic murmurs from co-existing heart defects (PDA, VSD, aortic stenosis).
- brachial-femoral pulse delay
- systolic BP differences between upper limbs (hypertension) and lower limbs (diminished or unobtainable).

**CXR might show notching of the posterior 1/3 of 3rd-8th ribs caused by erosion by large collateral arteries.
Postcoarctation dilatation producing a figure three sign.**



Disposal & Outcome:

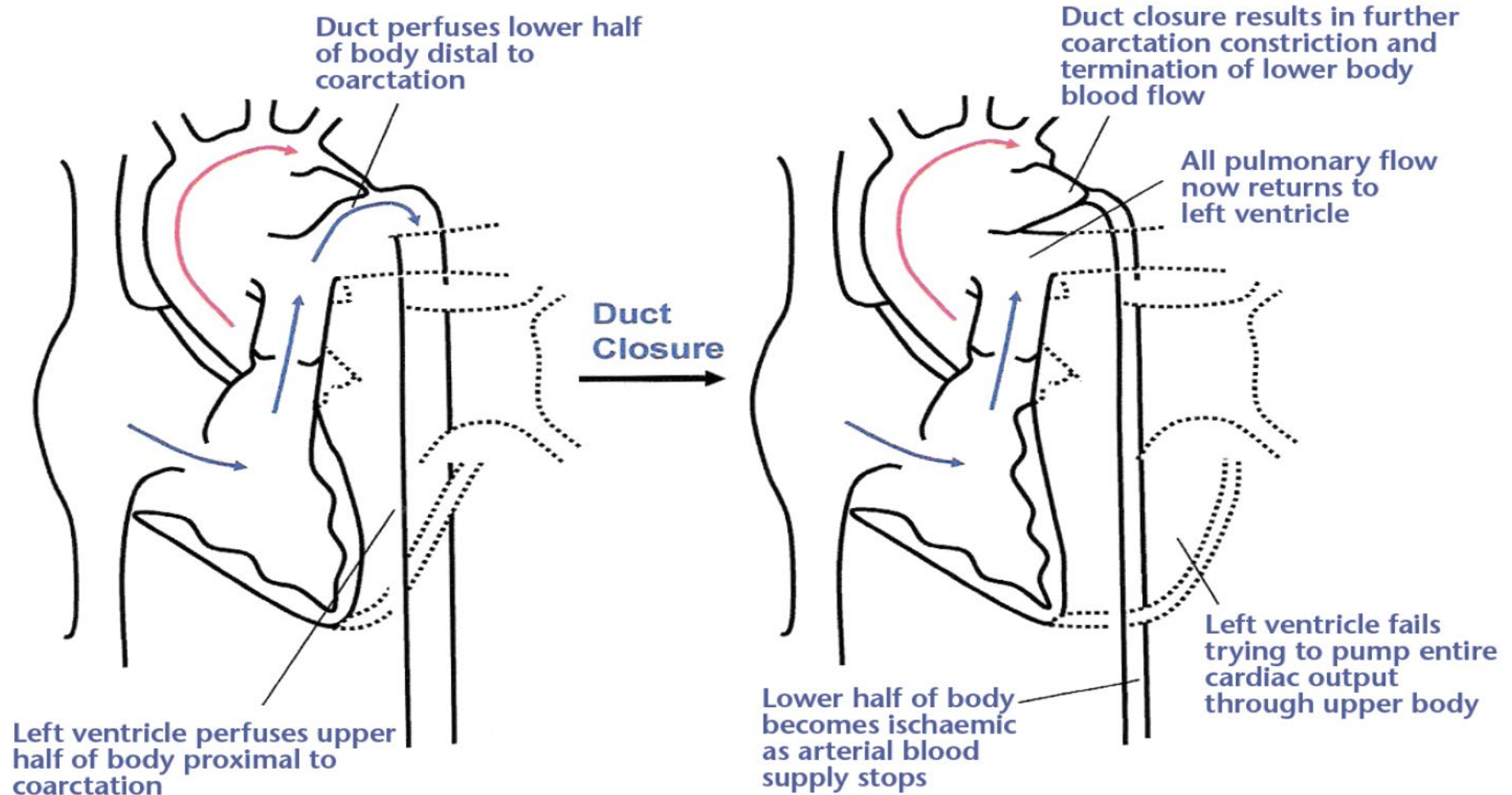
Following diuresis with i.v. bumetanide, perindopril and metoprolol were discontinued, replaced by ivabradine (selective Na_{if} channel inhibitor for rate control) and sacubitril + valsartan (combination neprilysin {inhibits endopeptidase catalyzed break down of natriuretic peptides} and AT1RA, titration protocol to optimize BP).

A cardiovascular MRI was arranged to determine the location and severity of coarctation, and evaluate collateral flow.

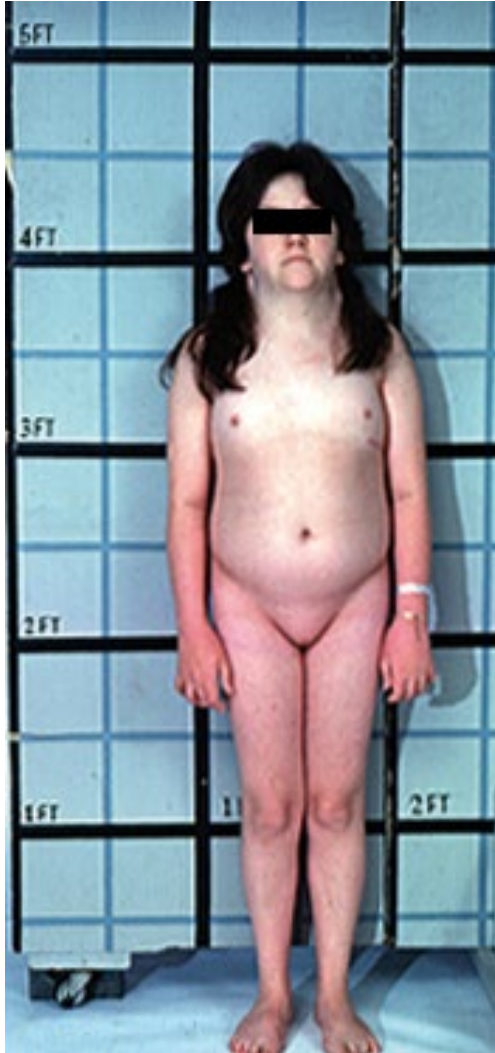Successful percutaneous transluminal angioplasty with stent placement resulted in resolution of heart failure, hypertension, and the pressure gradient between upper vs lower limbs resolved. She will be followed closely for stent-associated aneurysm, aortic dissection, re-coarctation

infantile (juxtaductal or preductal) coarctation of aorta

Babies may be asymptomatic for a few hours to days, but patency of the ductus arteriosus can be critical for lower body perfusion, so with normal closure of the ductus within the first 2-14 days of life, babies manifest rapid hemodynamic deterioration, with tachypnea, irritability, lower limb cyanosis, hypoperfusion of kidneys with excess renin secretion and acidosis.



**2 males : 1 female
(if female, suspect Turner syndrome)**

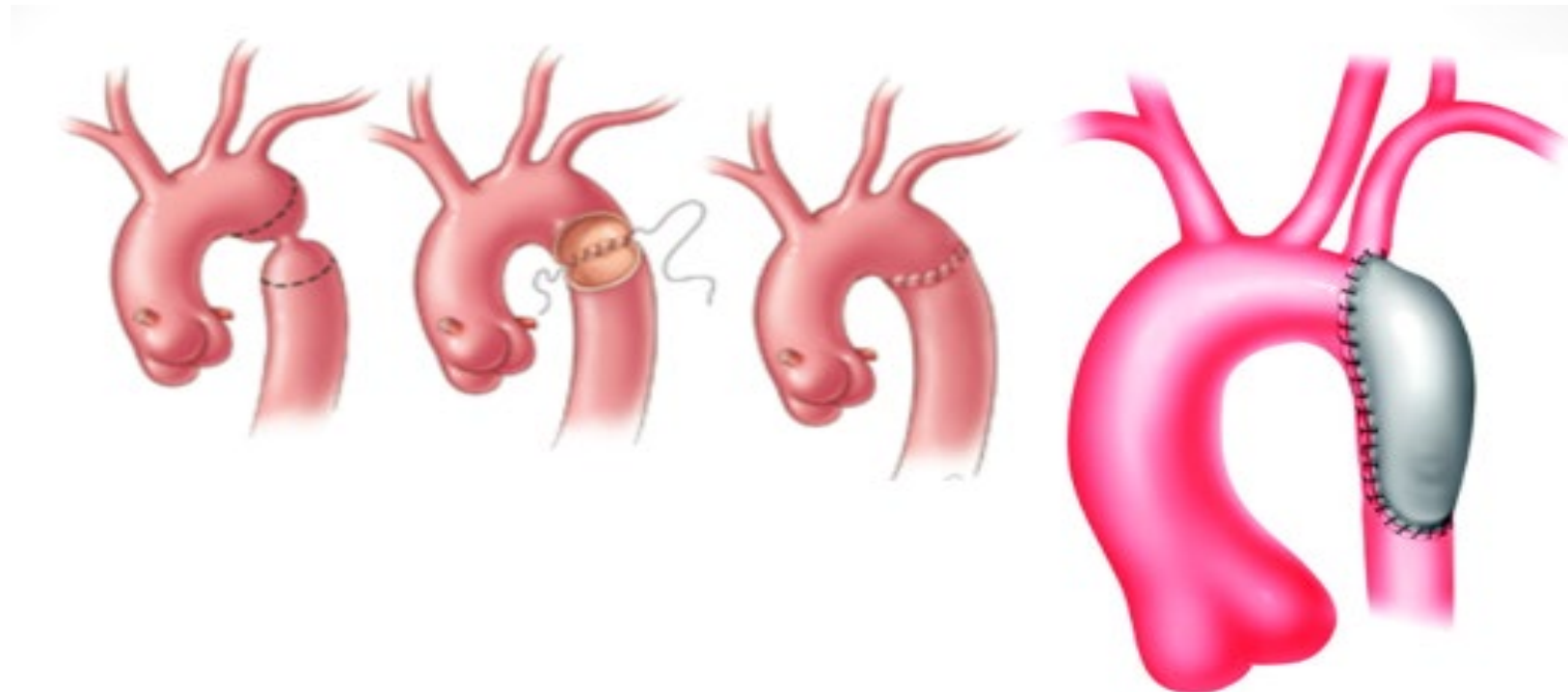


**Infantile form (preductal) COARCTATION
of AORTA**

- Associated with presence of patent ductus arteriosus
- Presents with lower part of the body cyanosis, upper extremities are ok
- **XO's (Turner syndrome) frequently have it with shortening of 4th metacarpal bone and horse-shoe kidney!!!**

Treatment Approaches:

- intubate and mechanically ventilate
- prostaglandin E1 infused i.v. to open and maintain patency of the ductus arteriosus
- norepinephrine and dobutamine inotropic support perfusion and counter PGE1-induced hypotension
- surgical: end-to-end anastomosis, subclavian flap





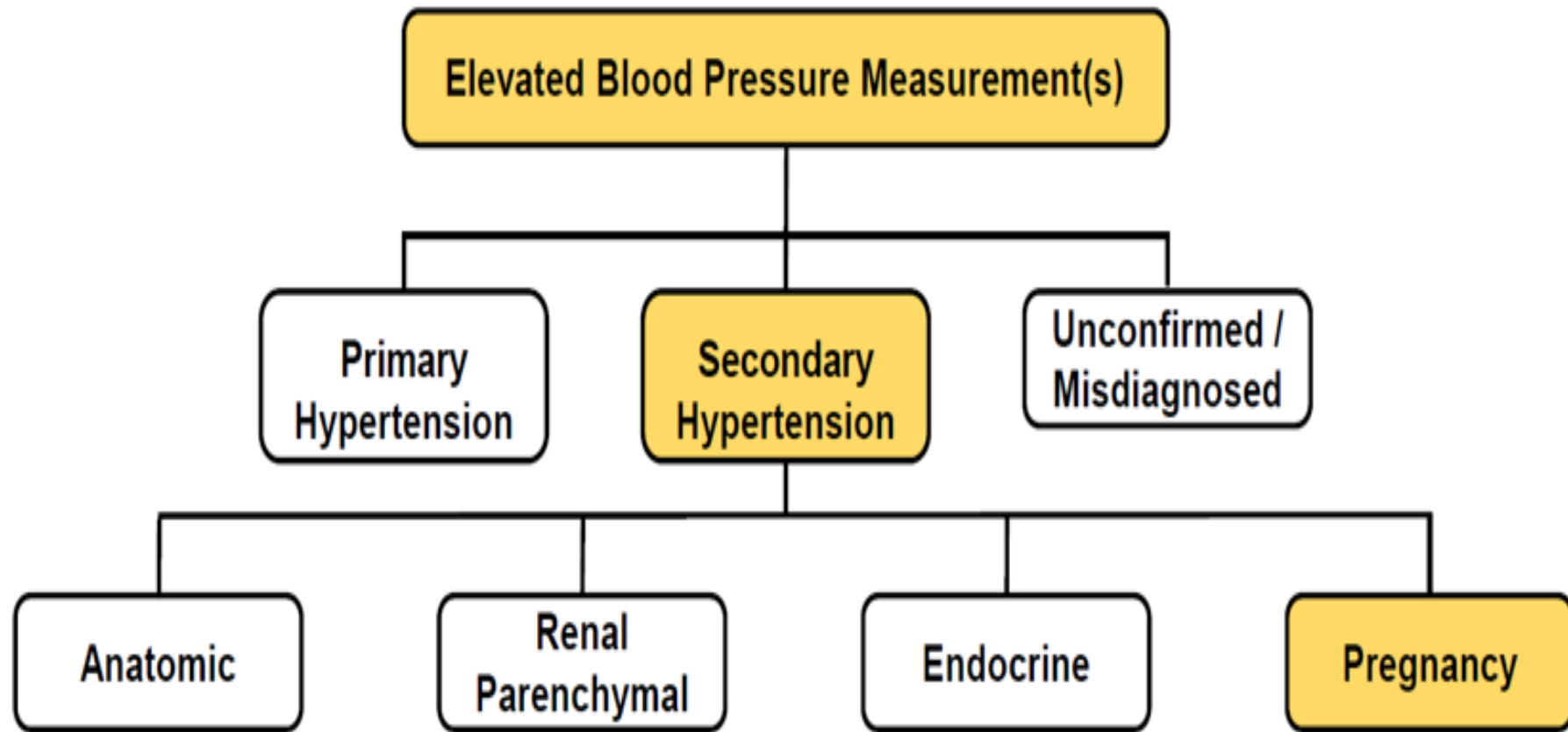
Take home points

- coarctation of the aorta is usually diagnosed in early infancy with closure of ductus arteriosus, causing sudden hemodynamic compromise
 - more common in males; so, if female r/o Turner syndrome
- adult patients are uncommon, and usually asymptomatic until late cardiovascular complications ensue (ruptured cerebral aneurysm):
 - Look for: heart murmurs, diminished lower extremity arterial pulses and pressures, CXR: rib notching, 3-sign

Secondary Hypertension

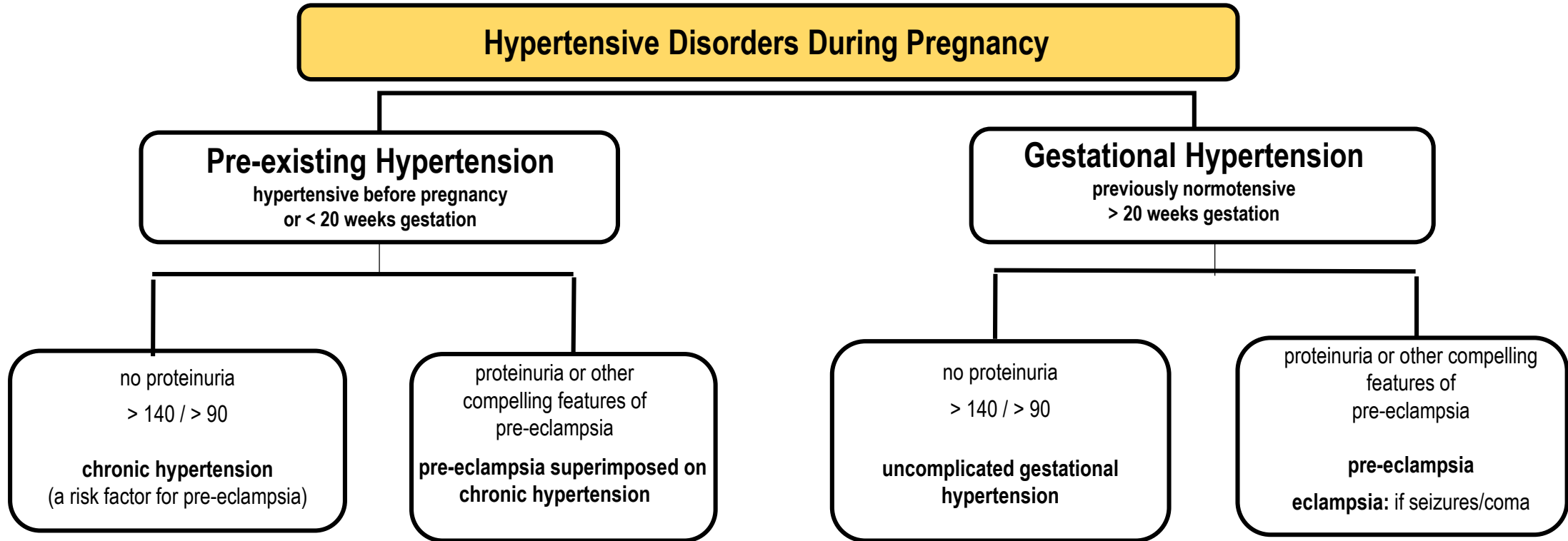
Worked Case Examples

Case 5



- with proteinuria
- without proteinuria

4 categories of hypertensive disorders during pregnancy



proteinuria: ≥ 0.3 g/24 hr
other compelling features of pre-eclampsia

maternal

- focal neurological features: persistent unusual headache, visual disturbances, severe nausea & vomiting
- pulmonary features: chest pain, dyspnea, pulmonary edema
- liver features: elevated transaminases (AST, ALT, LDH), serum albumin < 20 g/L
- renal features: elevated serum creatinine
- thrombocytopenia: < $100 \times 10^9/L$
- hypertensive urgency/emergency
- suspected placental abruption, persistent abdominal pain

fetal

- oligohydramnios
- intrauterine growth restriction
- absent or reversed end-diastolic umbilical arterial flow
- intrauterine fetal demise

Ms. J. is a 35 y.o. Gravida 3, Para 2, Term 1, Premature 0, Abortions 1, Live 1. Grp O Rh+
She presents today for 35-37 week antenatal visit. Planned vaginal delivery.

Hx current pregnancy: unplanned, uneventful. Switched from perindopril and indapamide to long-acting nifedipine when pregnancy was confirmed at about 8-weeks, HTN remained well-controlled.

OB Hx: 1st pregnancy age 22, previous marriage, uneventful, SVD; 2nd pregnancy at age 25, spontaneous abortion at 17 wks.

Pre-visit work-up:

- Group A Strep negative, plasma glucose within normal range, hematology normal, urine protein 2+ dipstick
- ultrasound remains consistent with EDC 20 Nov 2019 (34 Weeks, 5 Days gestation), decreased fetal growth velocity to 44th-centile since 28-week ultrasound 55th-centile, along with lower umbilical artery pulsatility index: an apparently healthy fetus approx. 3100 g, 43 cm.

Today: maternal wght: 80 Kg, seated resting BP 164/98 and 158/100, mild ankle edema persists, new finger swelling and periorbital puffiness.

FHR 154, normal fetal movement, cephalic presentation stationed above pelvic inlet.



What category of hypertension during pregnancy is illustrated in this case?



A chronic hypertension

B pre-eclampsia superimposed
on chronic hypertension

C uncomplicated gestational
hypertension

D pre-eclampsia

E eclampsia

Switched from perindopril and indapamide to long-acting nifedipine when pregnancy was confirmed at about 8-weeks, HTN has remained well-controlled.

Today, proteinuria, non-dependent edema, BP around 160/100.

Recommendation:

- start BP-lowering measures within 30-60 minutes, treat to target 140/85.
 - 1st-line options: i.v. labetalol (unless asthma), i.v. hydralazine, immediate-release oral nifedipine
- admit to quiet unit, close maternal and fetal monitoring, standby for possible C-section

Maternal risk incl. stroke, eclampsia, death.

Delivery halts the progression of preeclampsia, usually with rapid resolution of high blood pressure, proteinuria and edema. But best interests of mother and fetus are at odds, because delivery before 37 weeks gestation carries considerable risk of neonatal morbidity,

A recent prospective randomized controlled trial has shown that between 34-37 weeks gestation, if maternal blood pressure and laboratory markers of organ function are stable, expectant delivery is a reasonable option, but immediate delivery is warranted if maternal blood pressure rises (160/110) or worrisome fetal or maternal status.

- Chappell LC, et al. Planned early delivery or expectant management for late preterm pre-eclampsia (PHOENIX): A randomized controlled trial. LANCET 2019;S0140-6736(19)31963-4 [epub] [https://doi.org/10.1016/S0140-6736\(19\)31963-4](https://doi.org/10.1016/S0140-6736(19)31963-4).
- Staff AC. Long-term cardiovascular health after stopping pre-eclampsia. LANCET 2019;S0140-6736(19)31993-2 [epub] [https://doi.org/10.1016/S0140-6736\(19\)31993-2](https://doi.org/10.1016/S0140-6736(19)31993-2).