

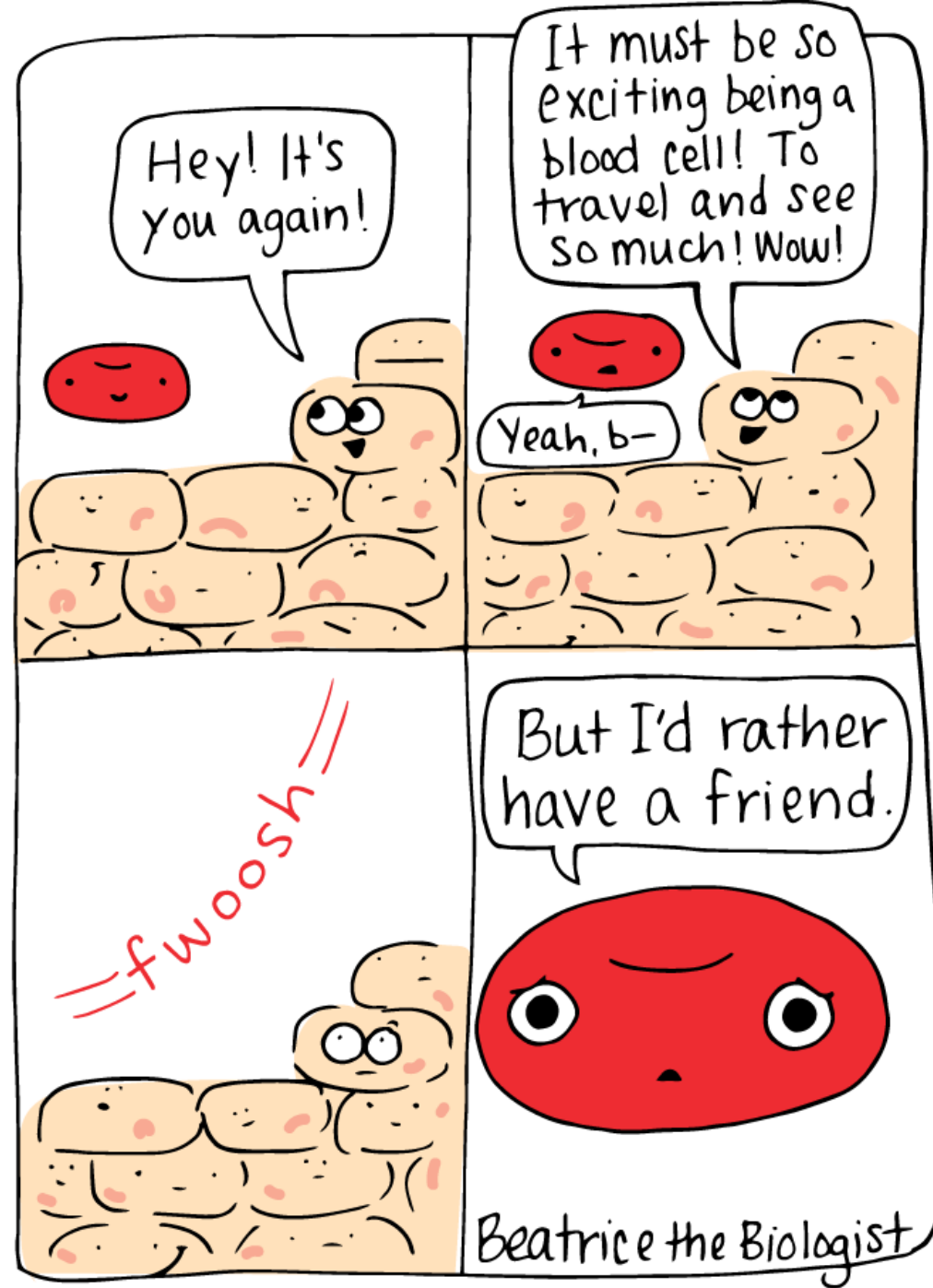
CBCs and Peripheral Blood Smears

Daniel Bustamante, M.D.

4/3/19

Objectives

- CBCs and differential
 - Methodology
 - Cost
 - Components
 - Clinical application
- Peripheral Blood Smear
 - Methodology
 - Cost
 - Technique
 - Clinical application
- Case Examples



Hey! It's you again!

It must be so exciting being a blood cell! To travel and see so much! Wow!

Yeah, b-

fwoosh

But I'd rather have a friend.

Beatrice the Biologist

Complete Blood Count with Differential

- The complete blood count (CBC) is a test that evaluates the cells that circulate in blood. Blood consists of three types of cells suspended in fluid called plasma: white blood cells (WBCs), red blood cells (RBCs), and platelets (PLTs)
- They are produced and mature primarily in the [bone marrow](#) and, under normal circumstances, are released into the bloodstream as needed.
- A CBC is typically performed using an automated instrument that measures various parameters, including counts of the cells that are present in a person's sample of blood.
- **White Blood Cells**
 - [neutrophils](#), [lymphocytes](#), [basophils](#), [eosinophils](#), and [monocytes](#).
 - Infections, allergies, leukemia, medications, autoimmune, etc
- **Red Blood Cells**
 - Nutritional, medications, bleeding, MPNs, etc.
- **Platelets**

Complete Blood Count with Differential

- [When is it ordered?](#)
- Routine health examination
- A CBC may be ordered when a person has any number of [signs](#) and [symptoms](#) that may be related to disorders that affect blood cells
 - Fatigue or weakness or has an infection, inflammation, bruising, or bleeding, a health practitioner may order a CBC to help diagnose the cause and/or determine its severity.
- When a person has been diagnosed with a disease known to affect blood cells, a CBC will often be ordered on a regular basis to monitor their condition
- Some therapies, such as chemotherapy, can affect [bone marrow](#) production of cells. Some medications can decrease WBC counts overall.

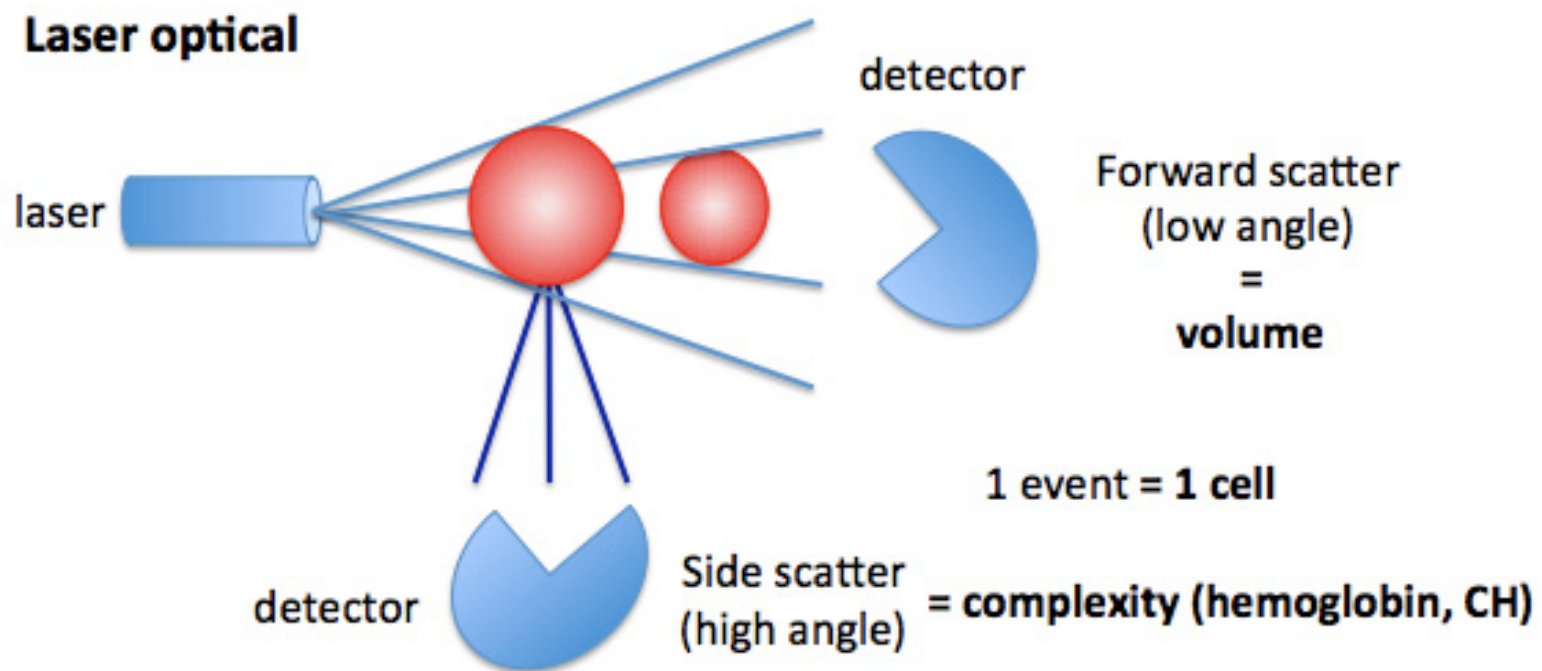
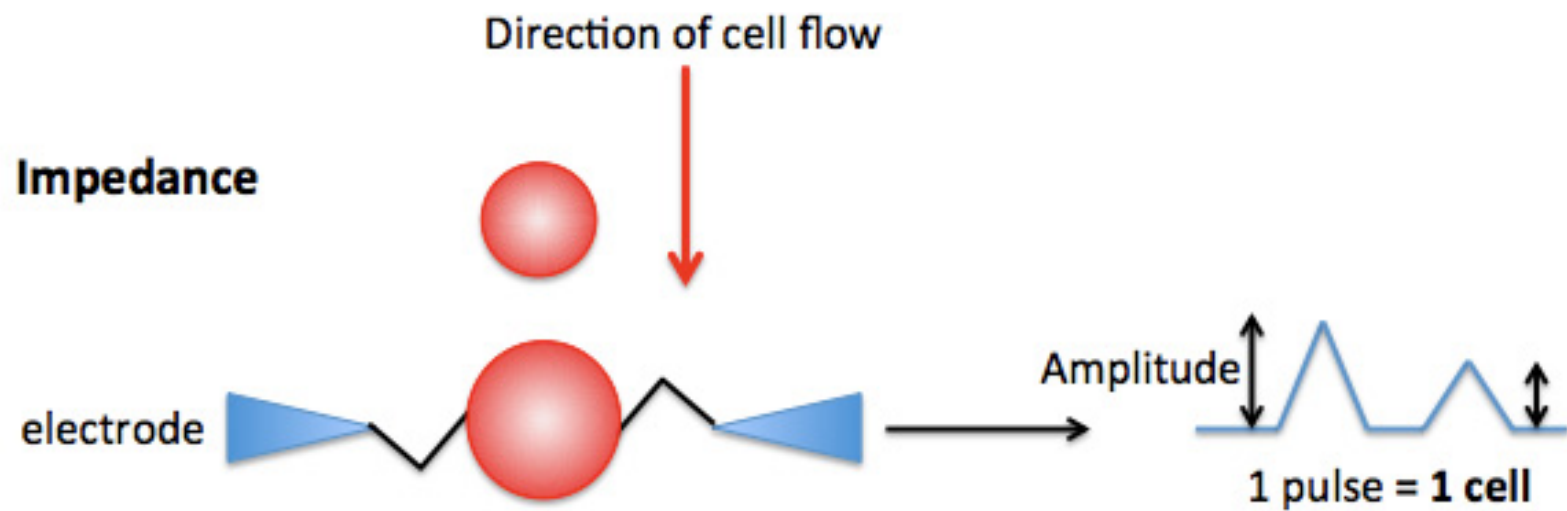
CBC Cost

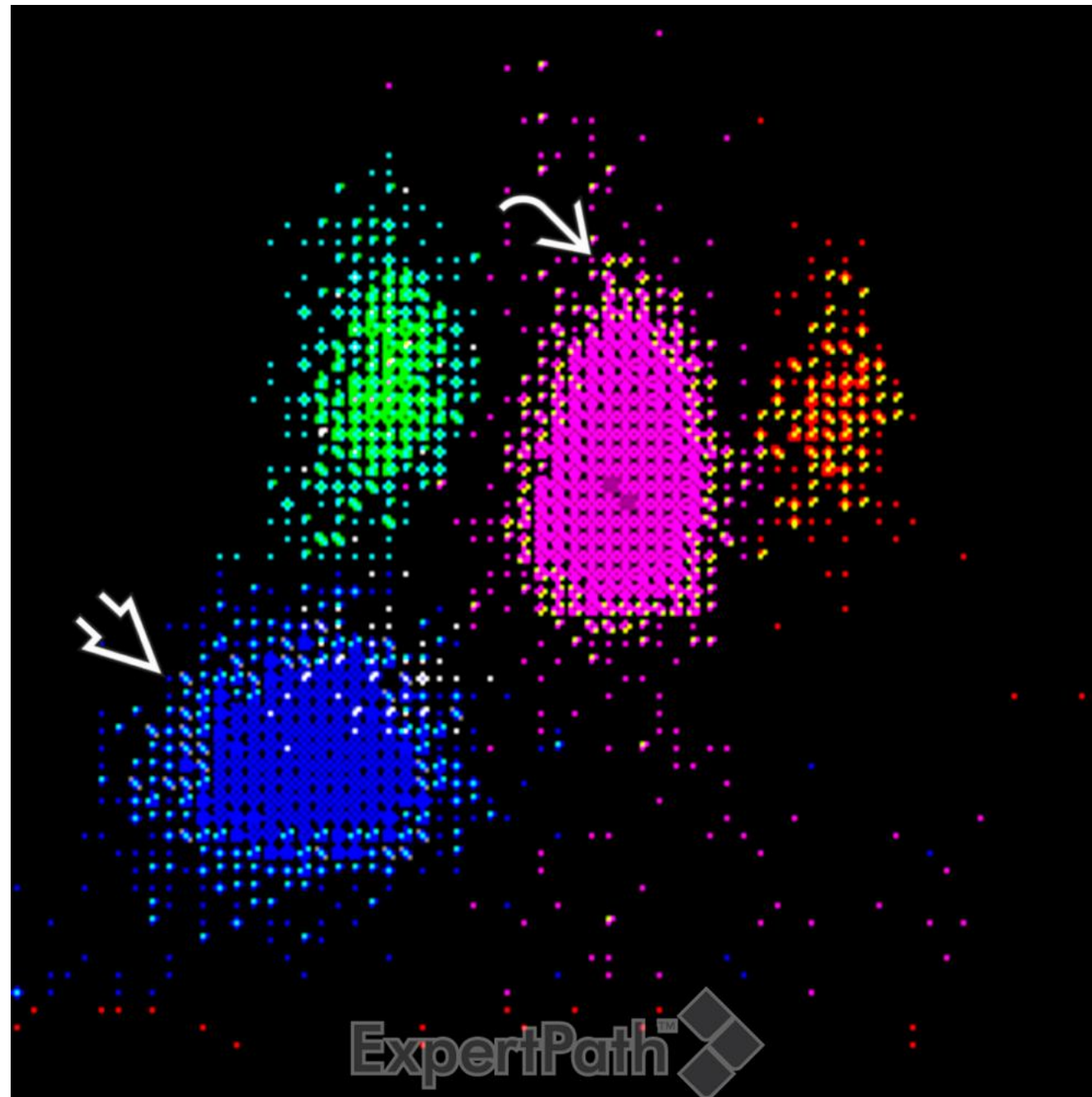
- CPT 85025

How much a CBC blood test cost?

On average, a CBC blood test is going to cost anywhere from \$15 to \$45 for the test alone.

This won't include any doctor office visit fees if you were to visit your doctor to have the test done. The price will depend on where you have the test performed and if any other tests are performed with it. For instance, a test taken at the hospital will be the most expensive option, costing more than \$85, while an online lab can be less than \$50 when the lab, such as Quest Diagnostics or LabCorp, mails them the results.





Based on size and cytoplasmic granularity, differential counts are performed. Lymphocytes (white open arrow) are small and agranular, whereas neutrophils are larger and granular (white curved arrow).

Component	Your Value	Standard Range	Units	Flag
White Blood Cell Count	5.4	4.0 - 11.0	K/uL	
Red Blood Cell Count	5.20	4.40 - 6.00	M/uL	
Hemoglobin	16.0	13.5 - 18.0	g/dL	
Hematocrit	47.2	40.0 - 52.0	%	
MCV	91	80 - 100	fL	
MCH	30.8	27.0 - 33.0	pg	
MCHC	33.9	31.0 - 36.0	g/dL	
RDW	12.7	<16.4 -	%	
Platelet Count	149	150 - 400	K/uL	L
Differential Type	Automated			
Neutrophil %	56	49.0 - 74.0	%	
Lymphocyte %	23	26.0 - 46.0	%	L
Monocyte %	13	2.0 - 12.0	%	H
Eosinophil %	7	0.0 - 5.0	%	H
Basophil %	1	0.0 - 2.0	%	
Abs. Neutrophil	3.1	2.0 - 8.0	K/uL	
Abs. Lymphocyte	1.2	1.0 - 5.1	K/uL	
Abs. Monocyte	0.7	0.0 - 0.8	K/uL	
Abs. Eosinophil	0.4	0.0 - 0.5	K/uL	
Abs. Basophil	0.0	0.0 - 0.2	K/uL	



Additional information

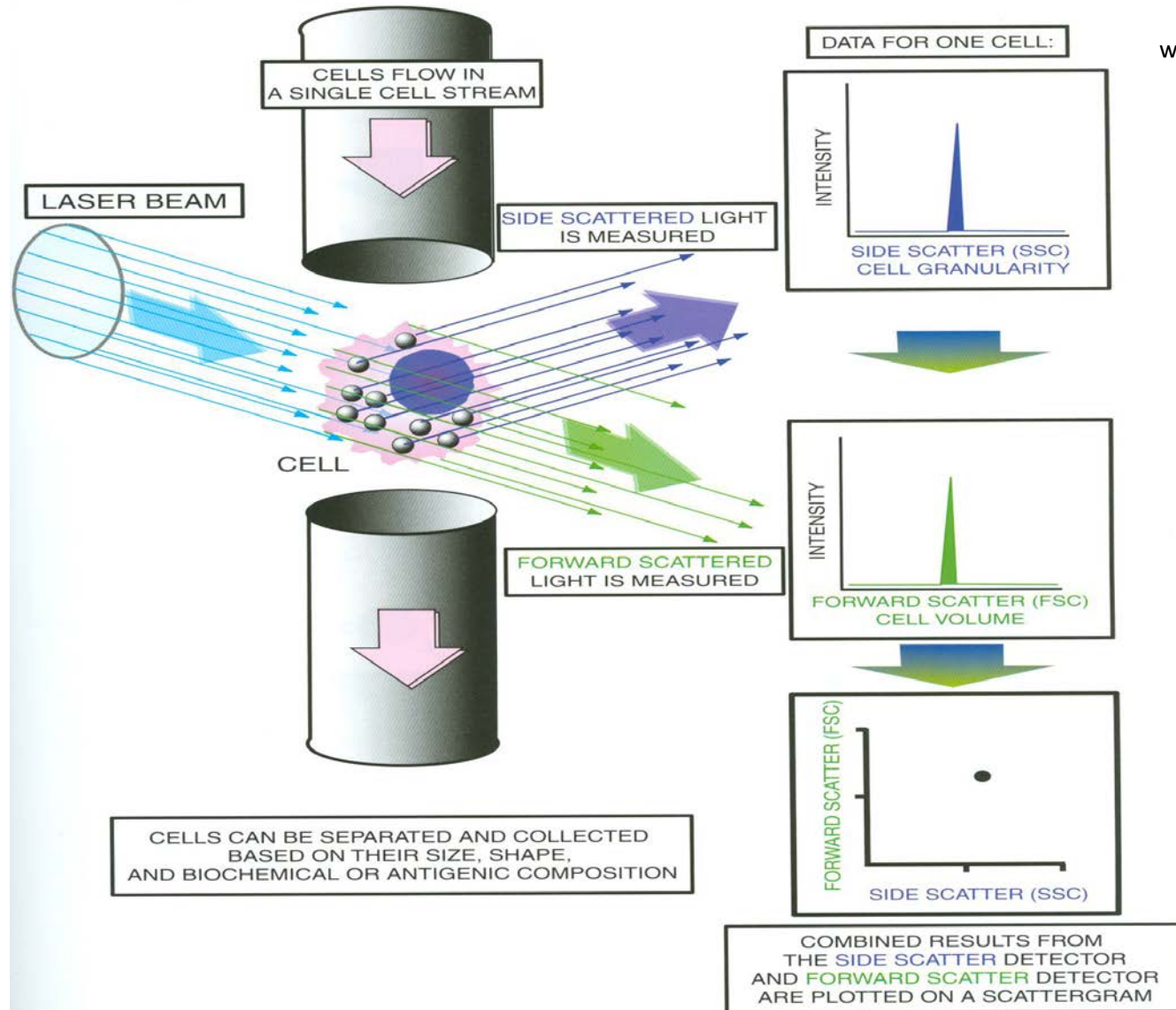
- Procedures performed in Hematopathology
 - Bone marrow biopsy
 - Lumbar puncture
- **Laboratories performed in Hematopathology**
 - CBC & Peripheral Blood Smear
 - ***Flow Cytometry***
 - Cytogenetic studies
 - Additional molecular studies (FISH & PCR)



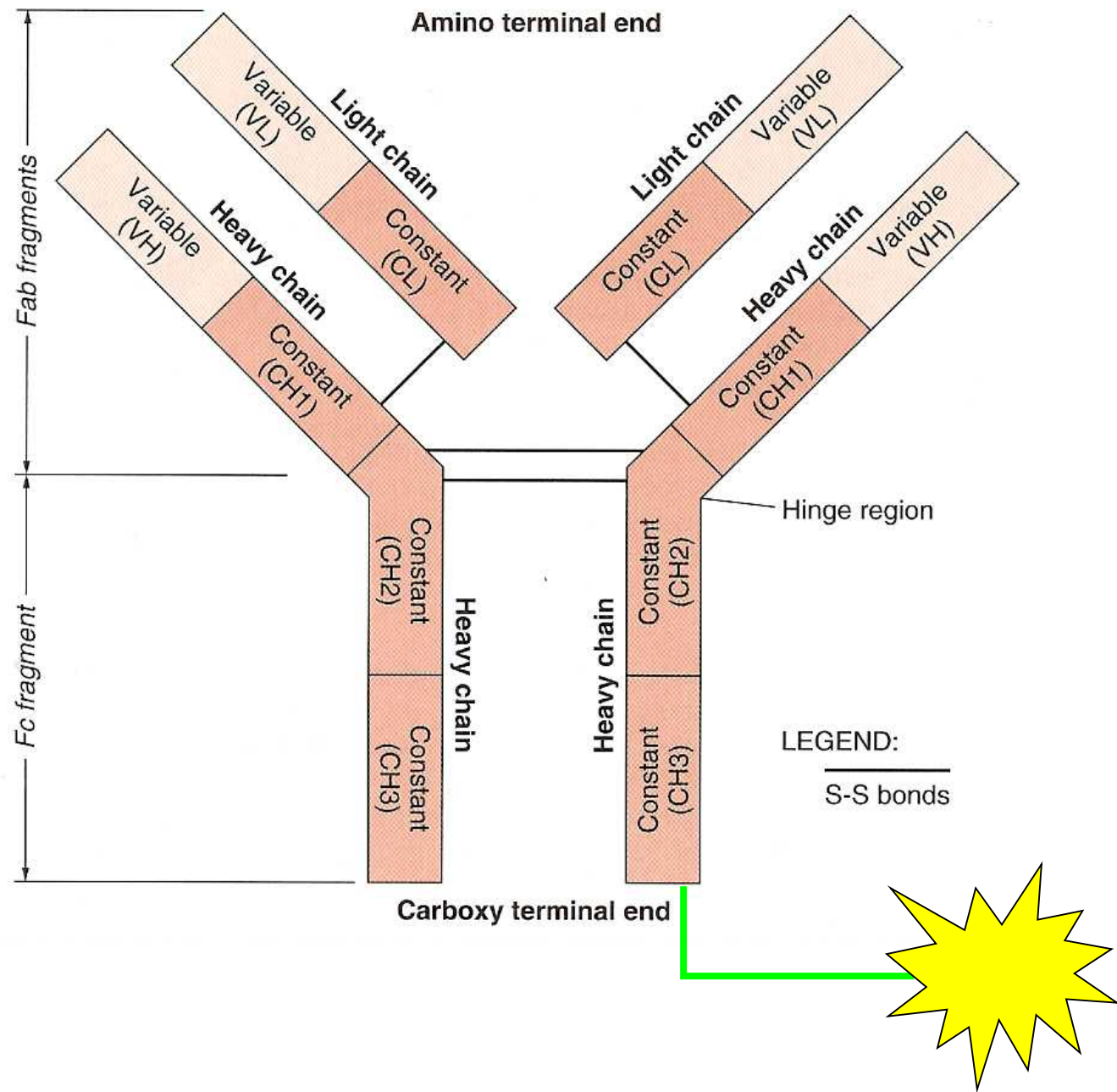
Flow Cytometry

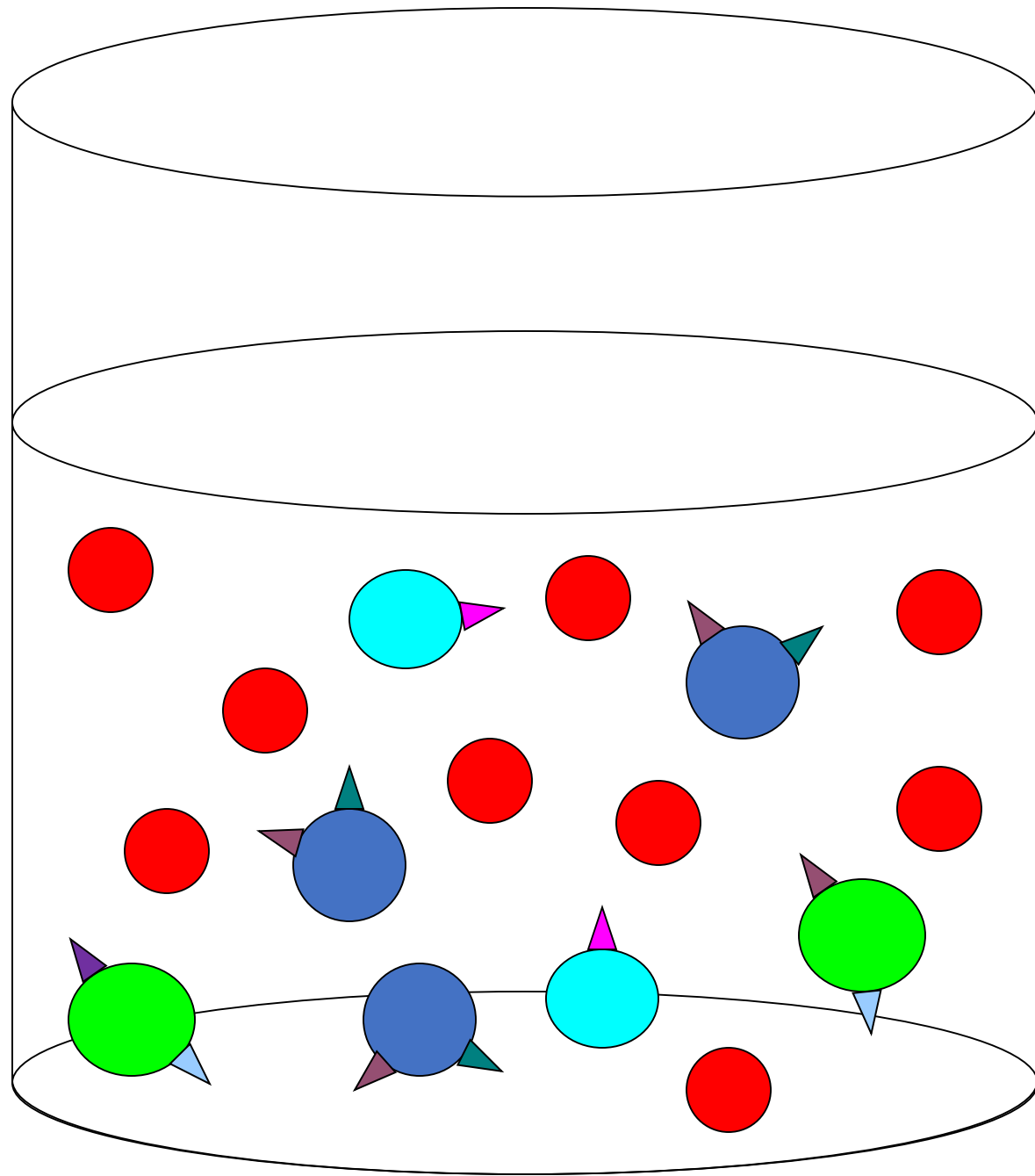
- **Flow cytometry is a method by which the antigenic profile of cells can be analyzed.**
 - Also evaluates cell size and internal granularity (just like the CBC).
 - Forward scattered light correlates with cell size
 - Side scattered light correlates with internal granularity
- Flow cytometry is **particularly helpful in determining the lineage and the stage of development when diagnosing leukemia.**

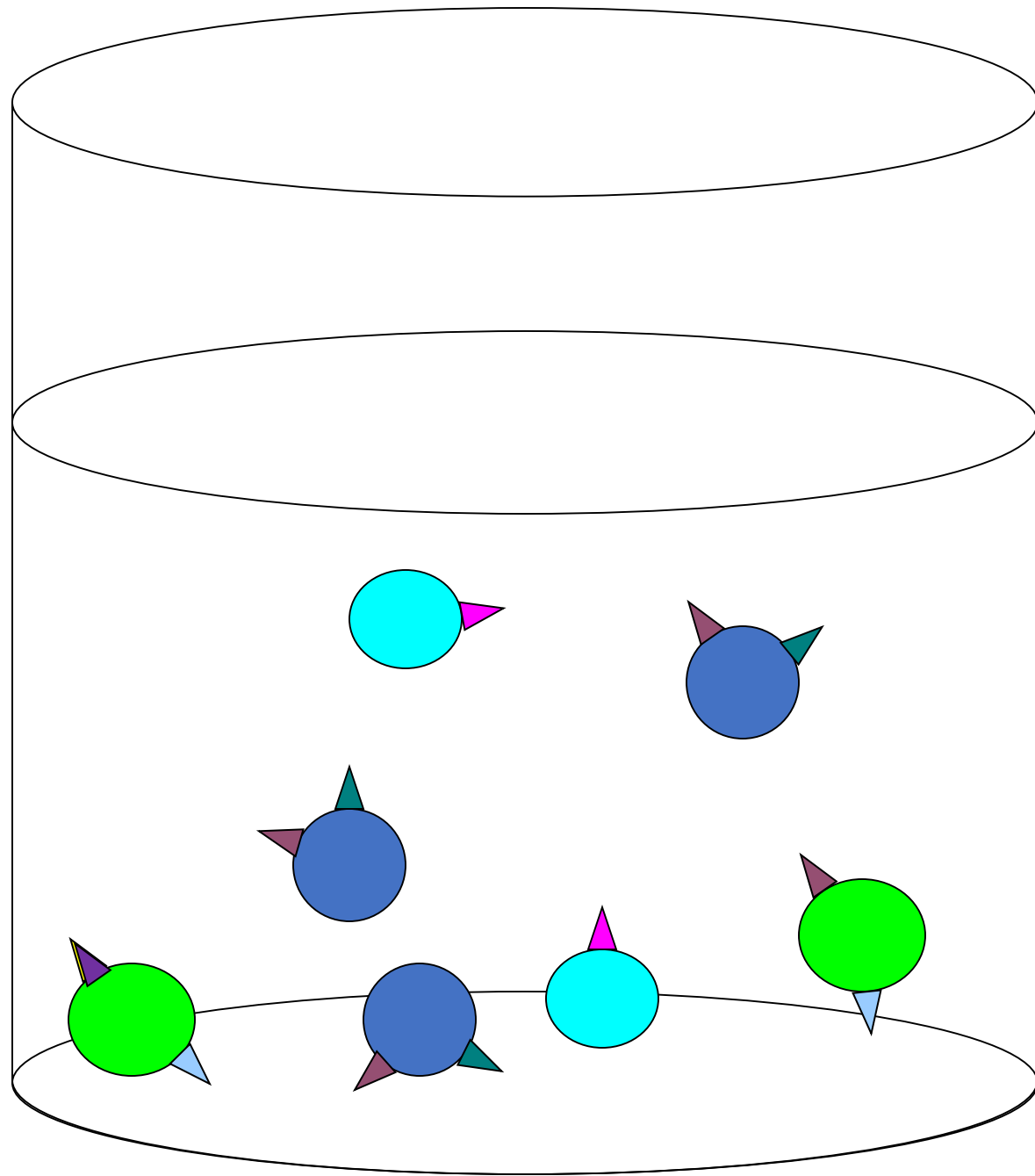
FLOW CYTOMETRY: BASIC PRINCIPLES

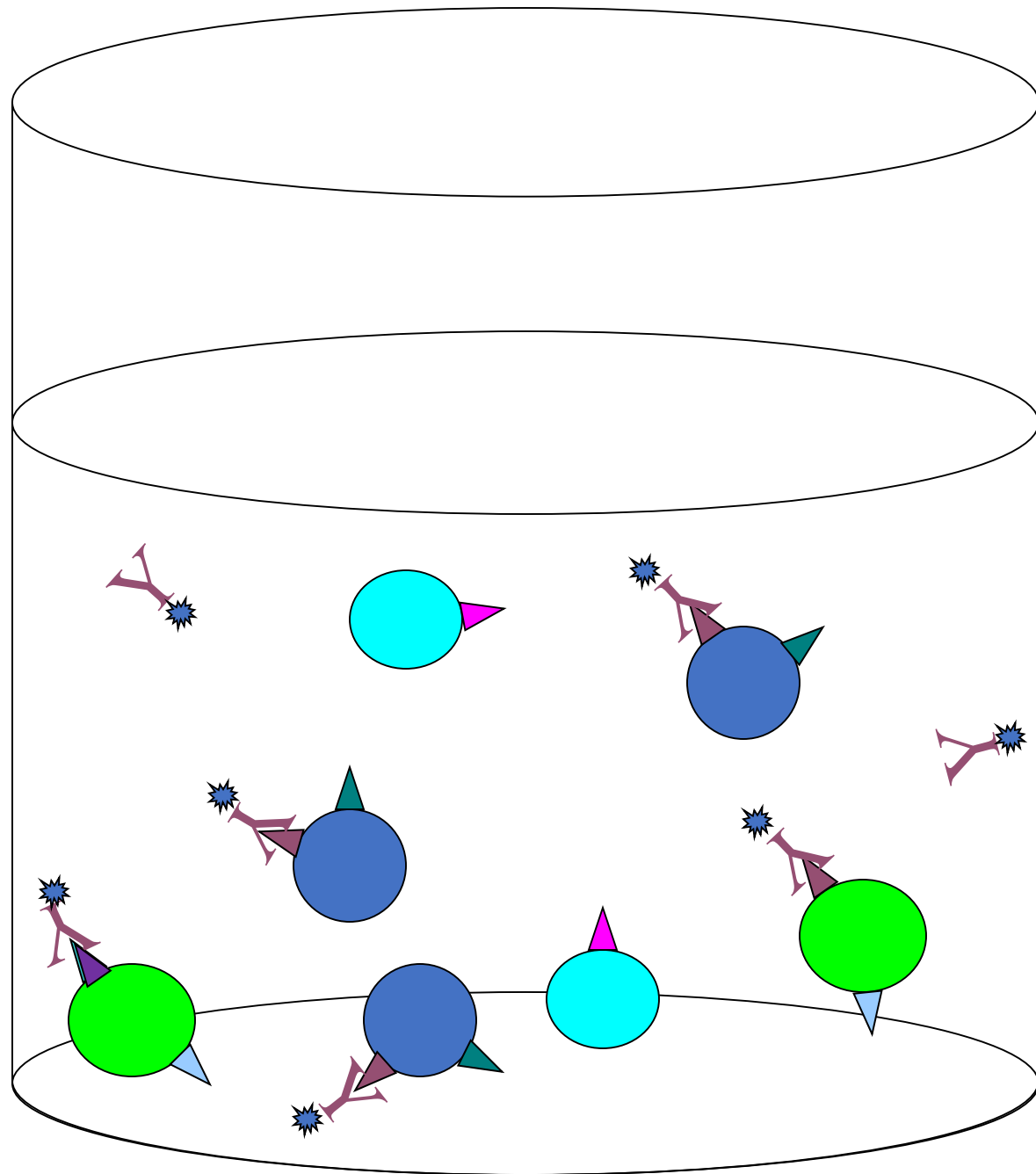


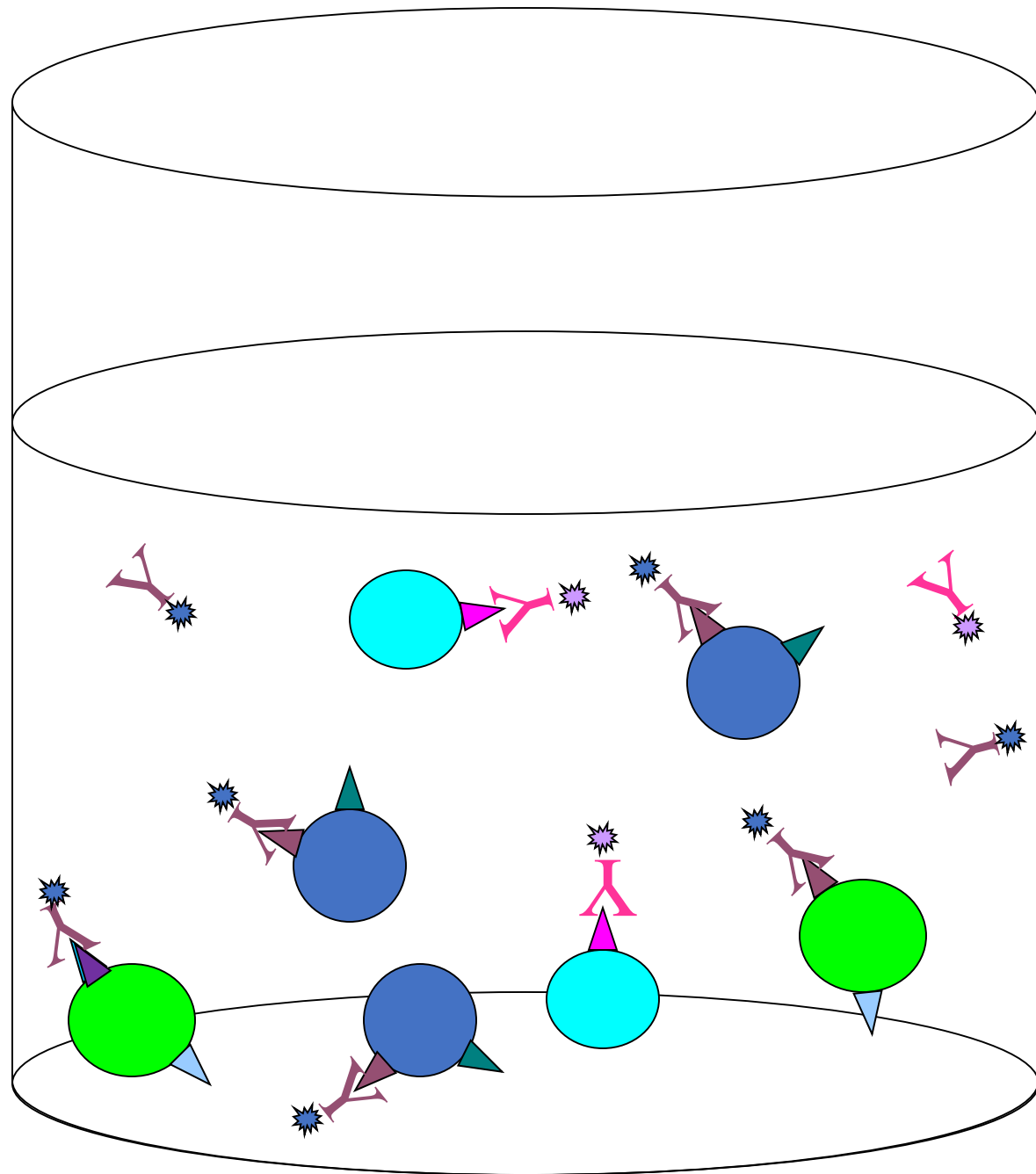
www.waisman.wisc.edu/cmnm/images/flowcyto.jpg

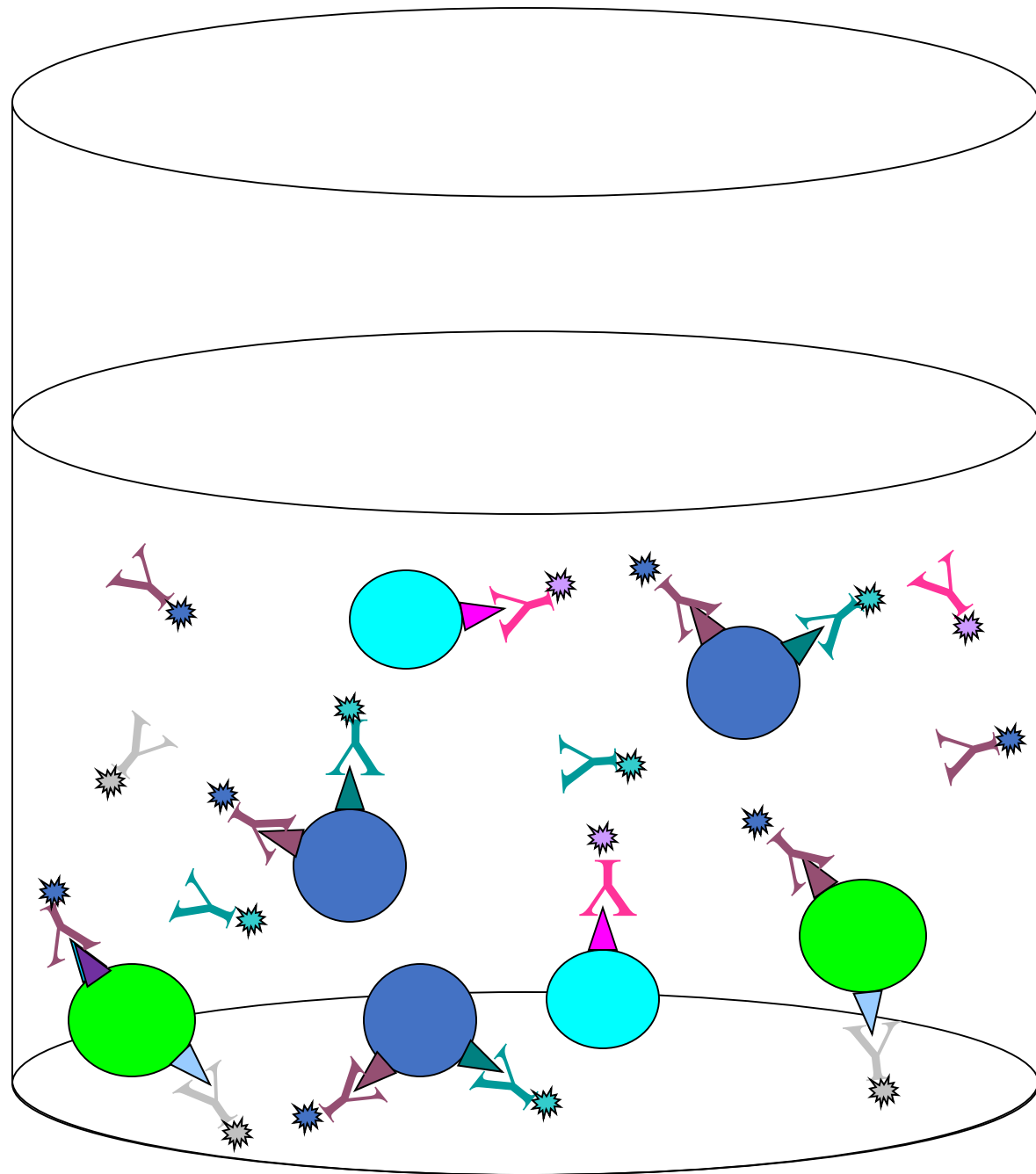


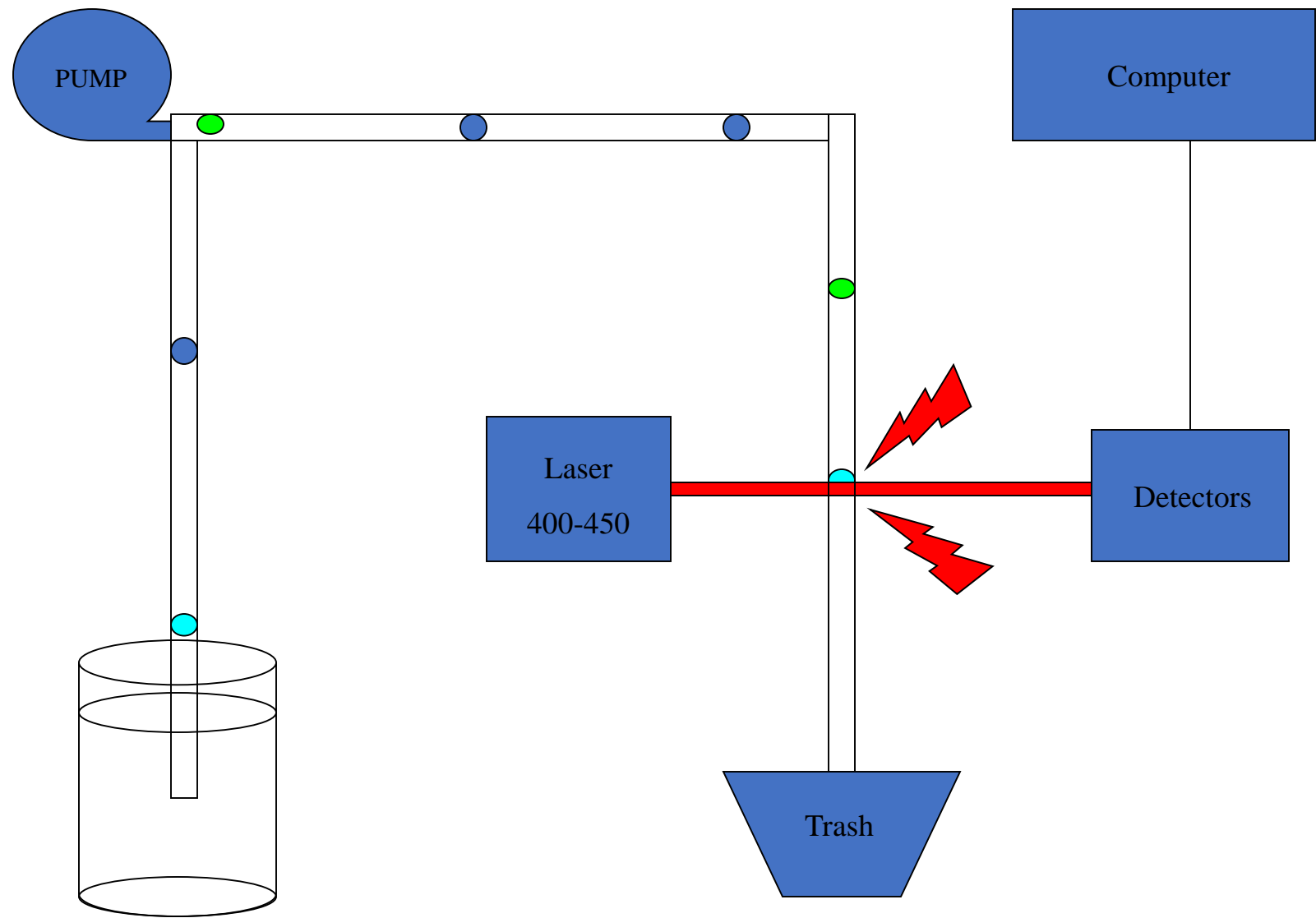


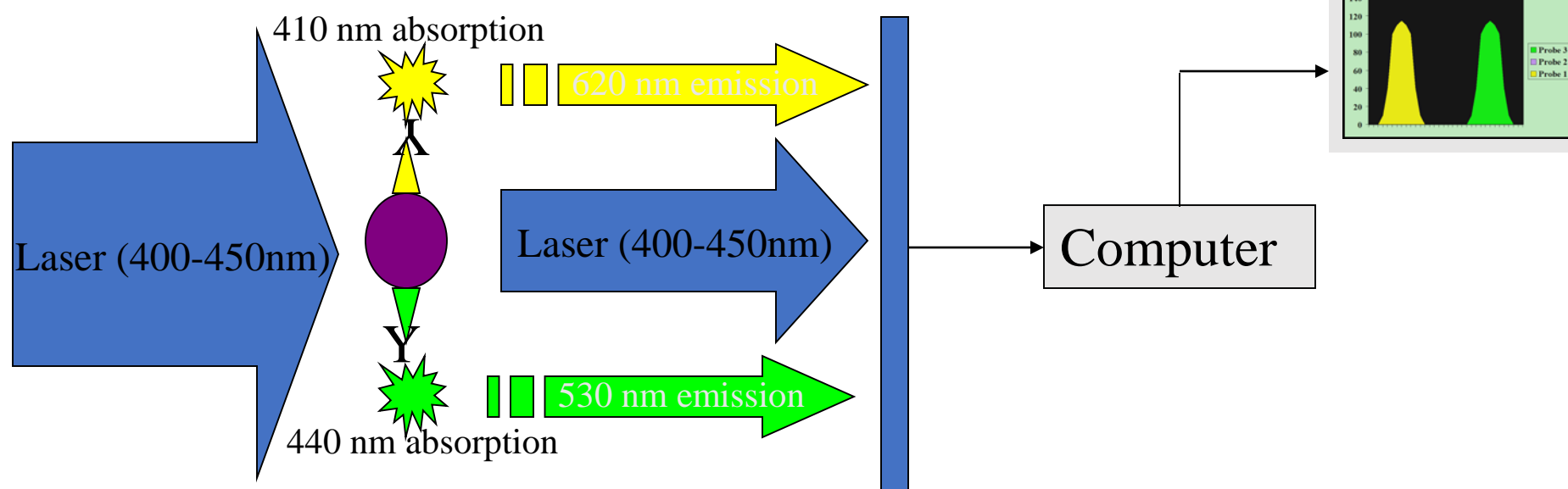
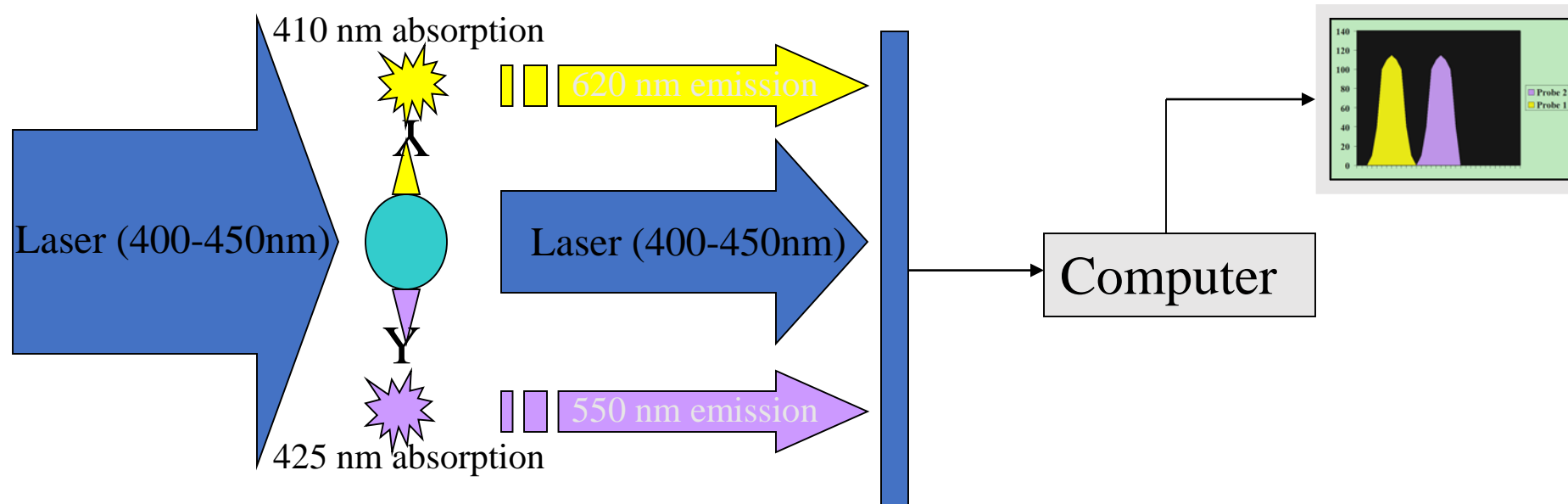




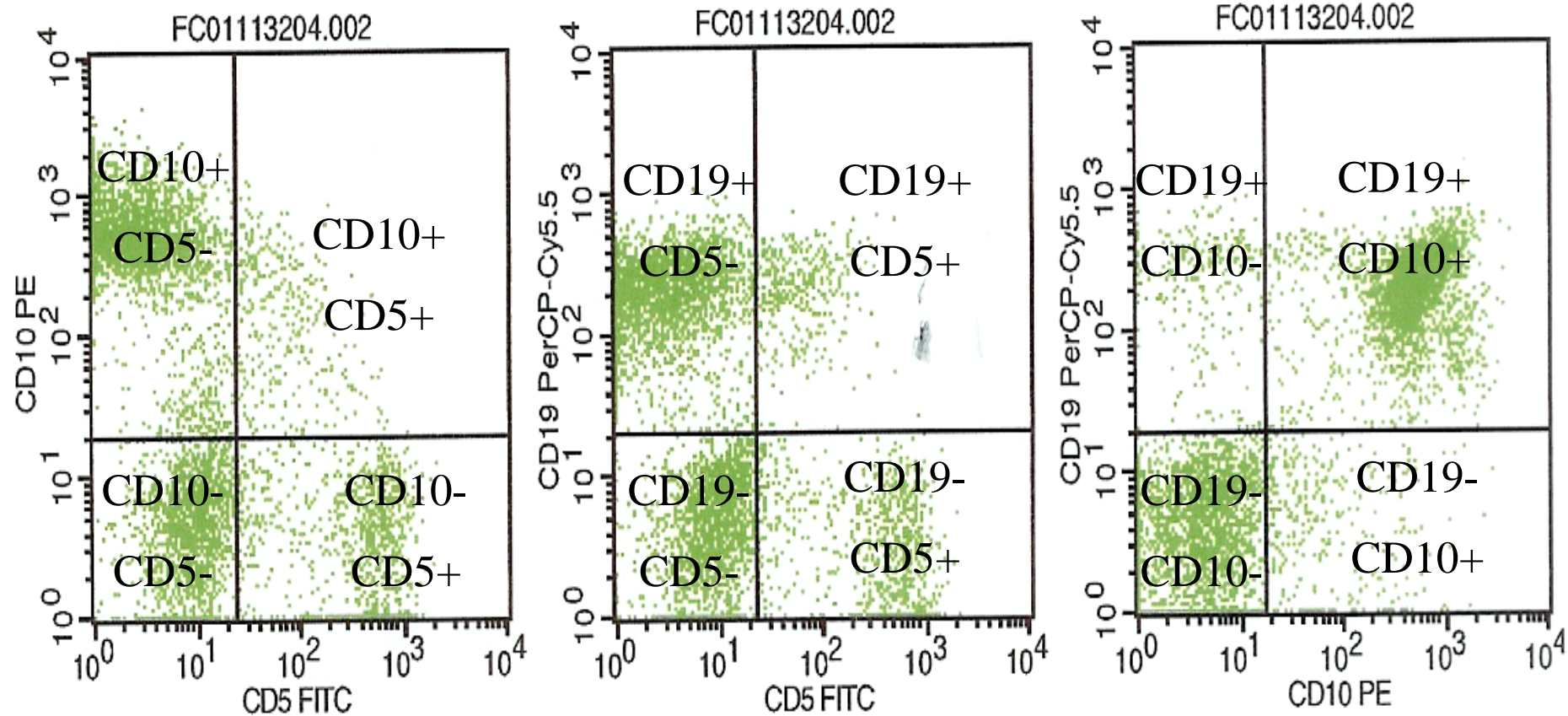








2. Analyze antigenic profile

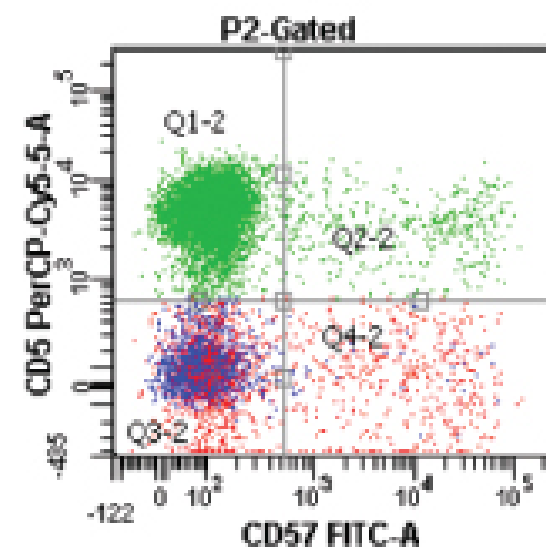
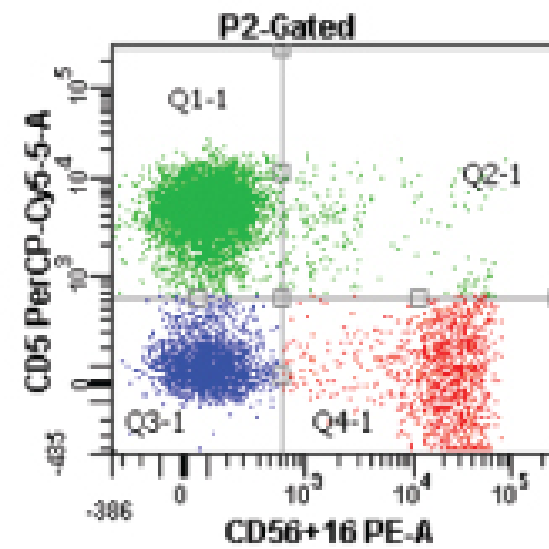
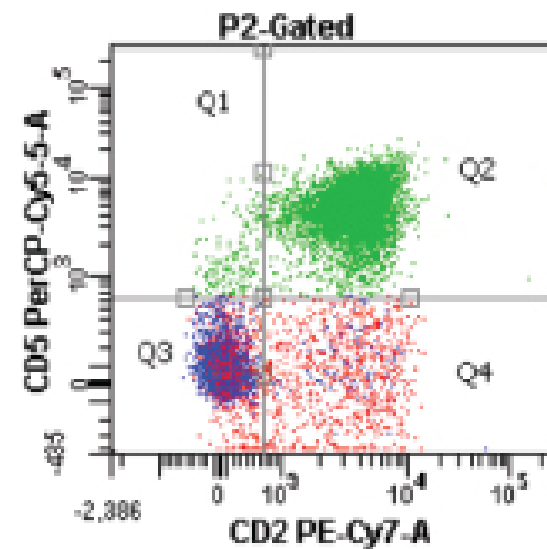
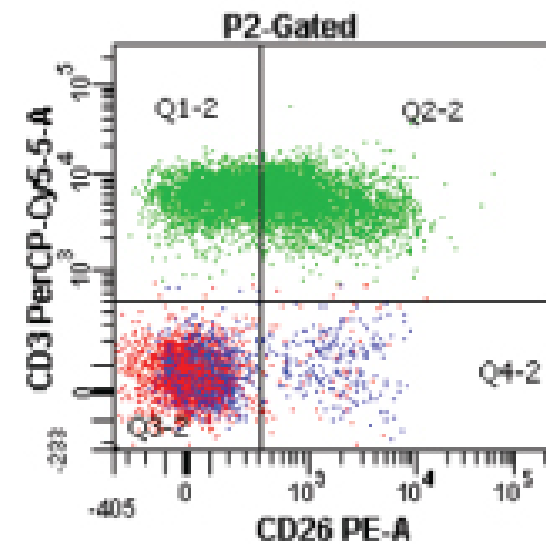
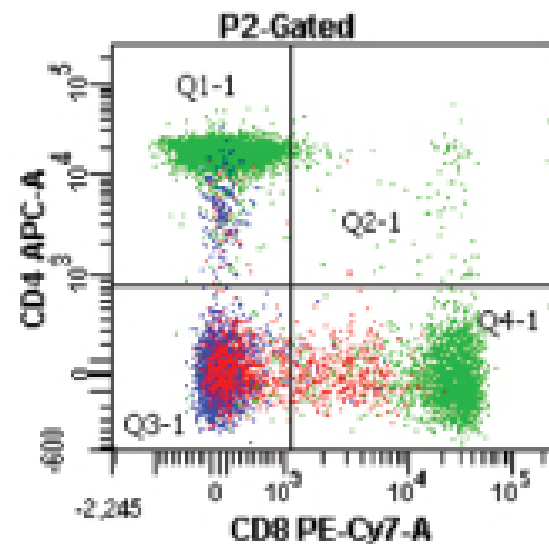
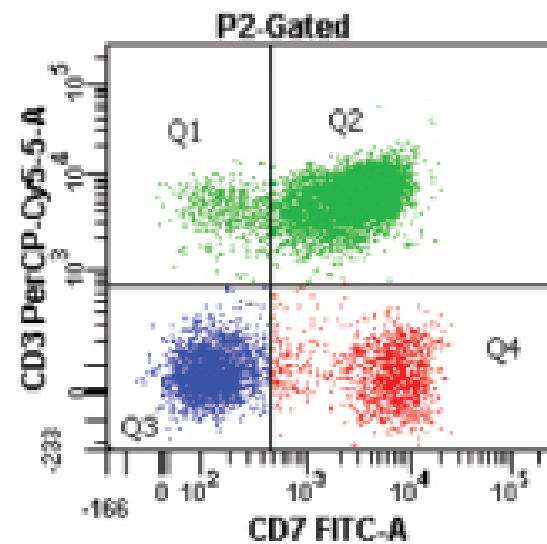


Different population of cells:

HEMATOGONES: CD5⁻, CD10⁺, CD19⁺ (60% of total cells gated)

T CELLS: CD5⁺, CD10⁻, CD19⁻ (10 % of total cells gated)

UNCLASSIFIED CELLS: CD5⁻, CD10⁻, CD19⁻ (30% of total cells gated).



Cell Surface Markers

- **Cell surface markers** are protein molecules on cell membranes. They can give **information concerning the lineage, function, or stage of development** of a given cell population. These markers can be detected with specific monoclonal antibodies.

Representative CD Markers you need to know

Cell Type	Markers
Immature blast	CD 34
Immature myeloblast	CD13, CD33, MPO
B cell lymphoblast	TdT, CD19
T cell lymphoblast	TdT, CD3
T cell	CD3, CD5, & CD7
B cell	CD19, CD20

GLASBERGEN

© Randy Glasbergen.
www.glasbergen.com

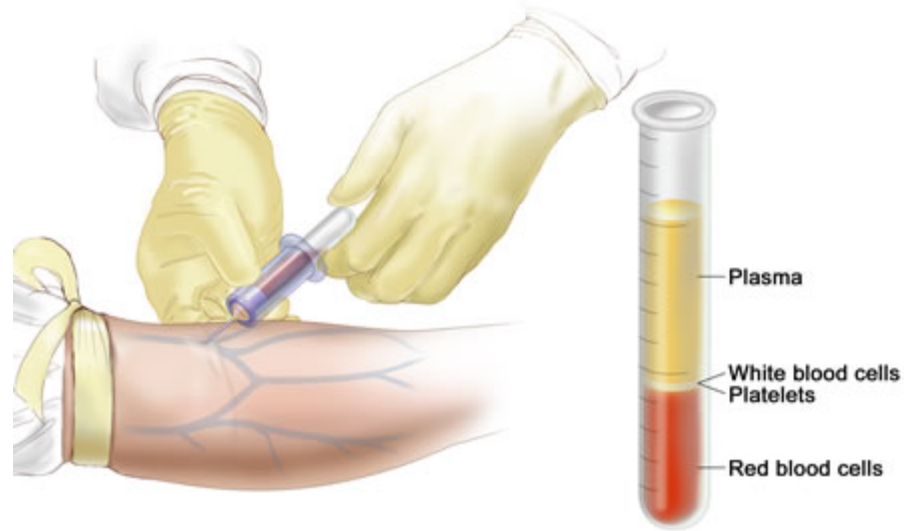


**“The red circles are your red blood cells.
The white circles are your white blood cells.
The brown circles are donuts. We need to talk.”**

Peripheral Blood Smear Review

- https://youtu.be/O3d_4dkVVSE
- <https://youtu.be/89VRmOJ10iA>

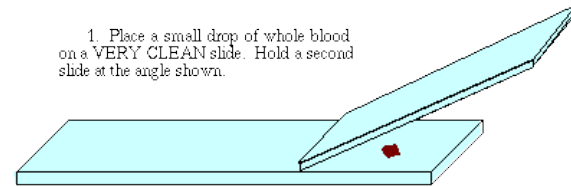
CBC & Peripheral Blood Smear



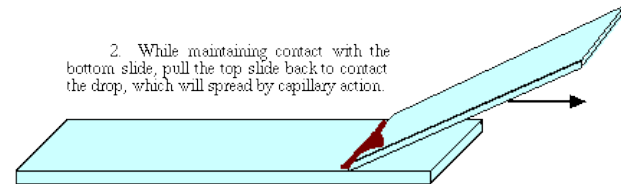
© 2007 Terese Winslow
U.S. Govt. has certain rights



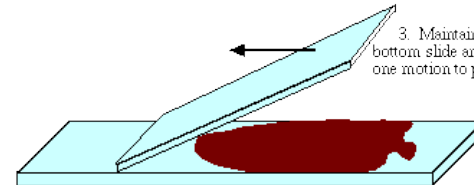
1. Place a small drop of whole blood on a VERY CLEAN slide. Hold a second slide at the angle shown.



2. While maintaining contact with the bottom slide, pull the top slide back to contact the drop, which will spread by capillary action.



3. Maintain firm contact with the bottom slide and push the top slide in one motion to produce the smear.



Peripheral Blood Smear Review

- When do I see them?
- When are they made?

PB Smear Review Cost

- CPT 85060

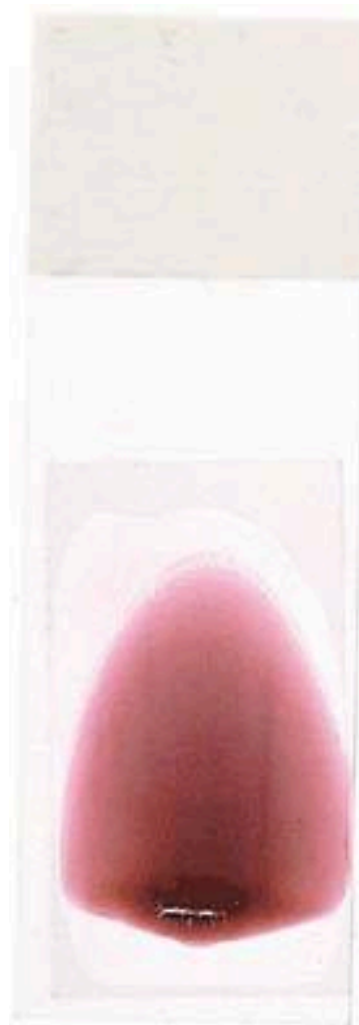
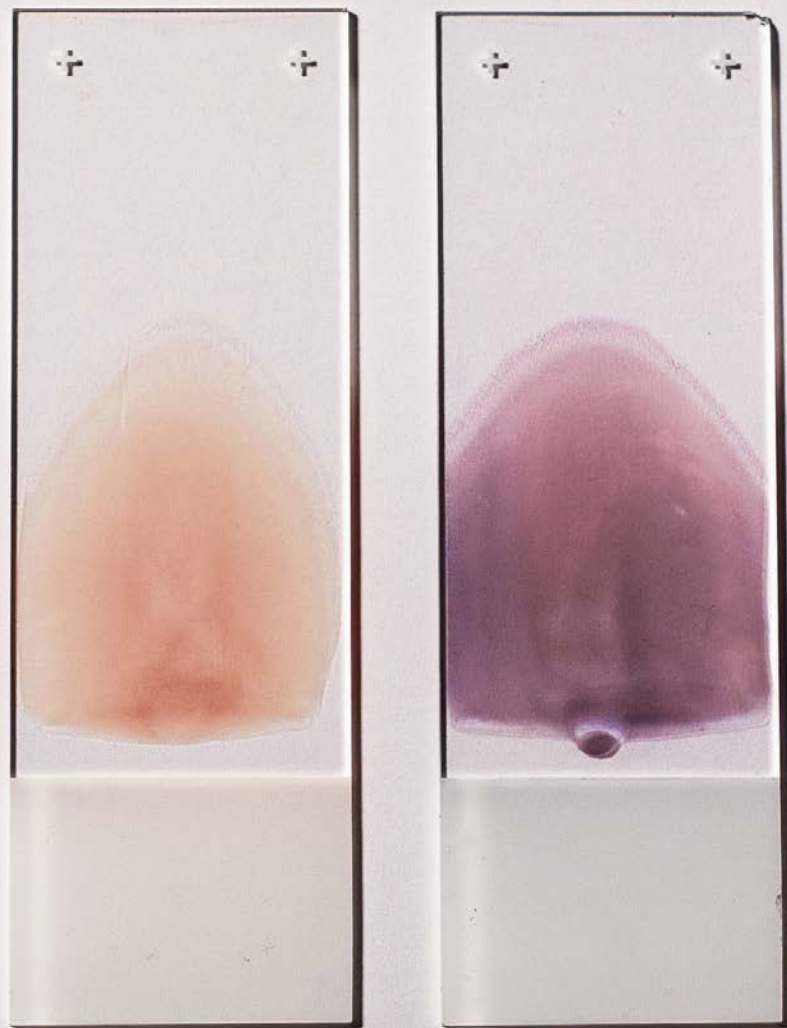
Peripheral Blood Smear Pathology Interpretation

How Much Does a Peripheral Blood Smear Pathology Interpretation Cost?


On MDsave, the cost of a Peripheral Blood Smear Pathology Interpretation is \$37. Compare local prices, save money, and book your procedure — all in one place with MDsave. [Read more about how it works.](#)

MDSAVE
NATIONAL AVERAGE

\$37



Polycythemia



Normal

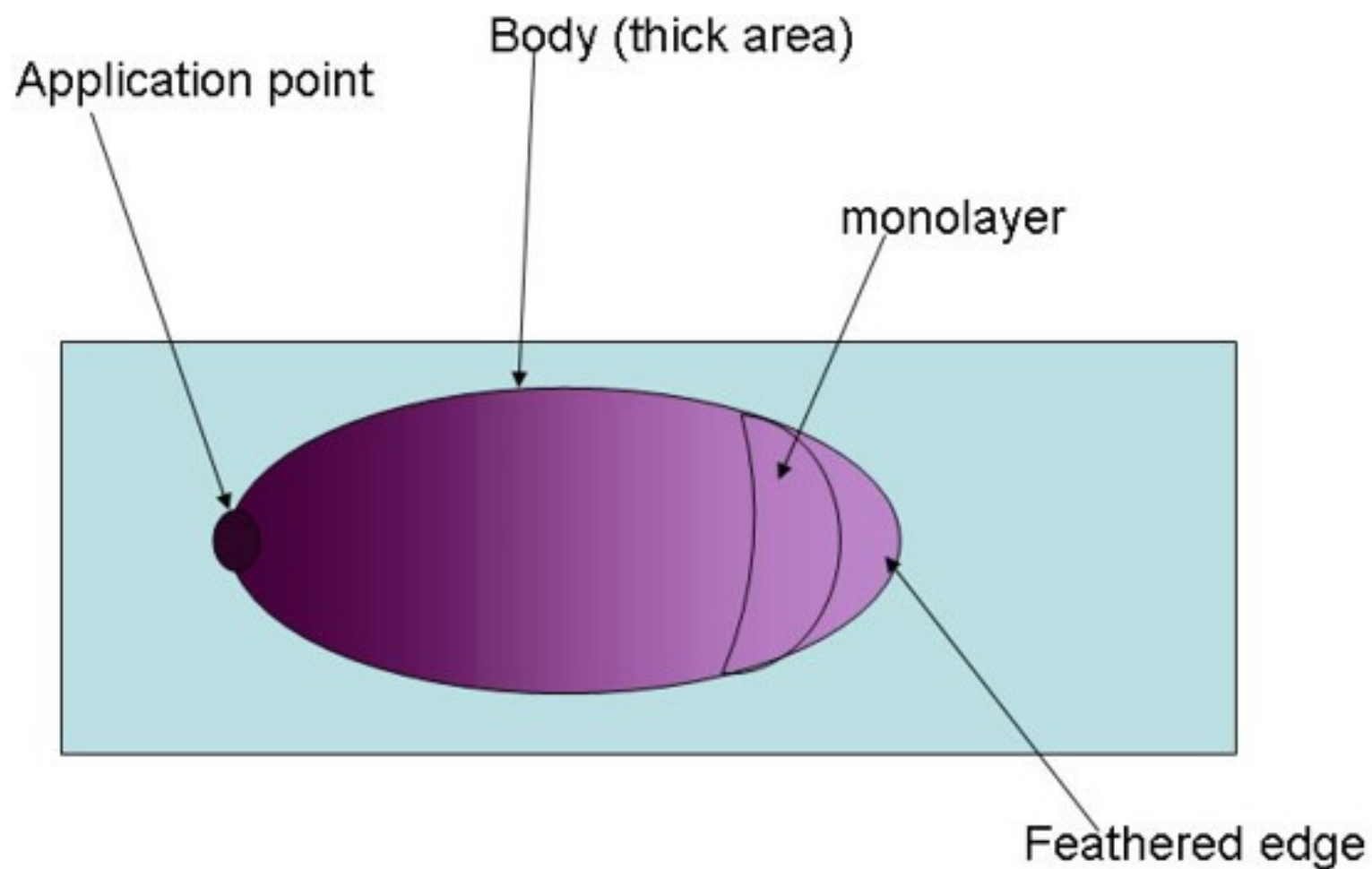


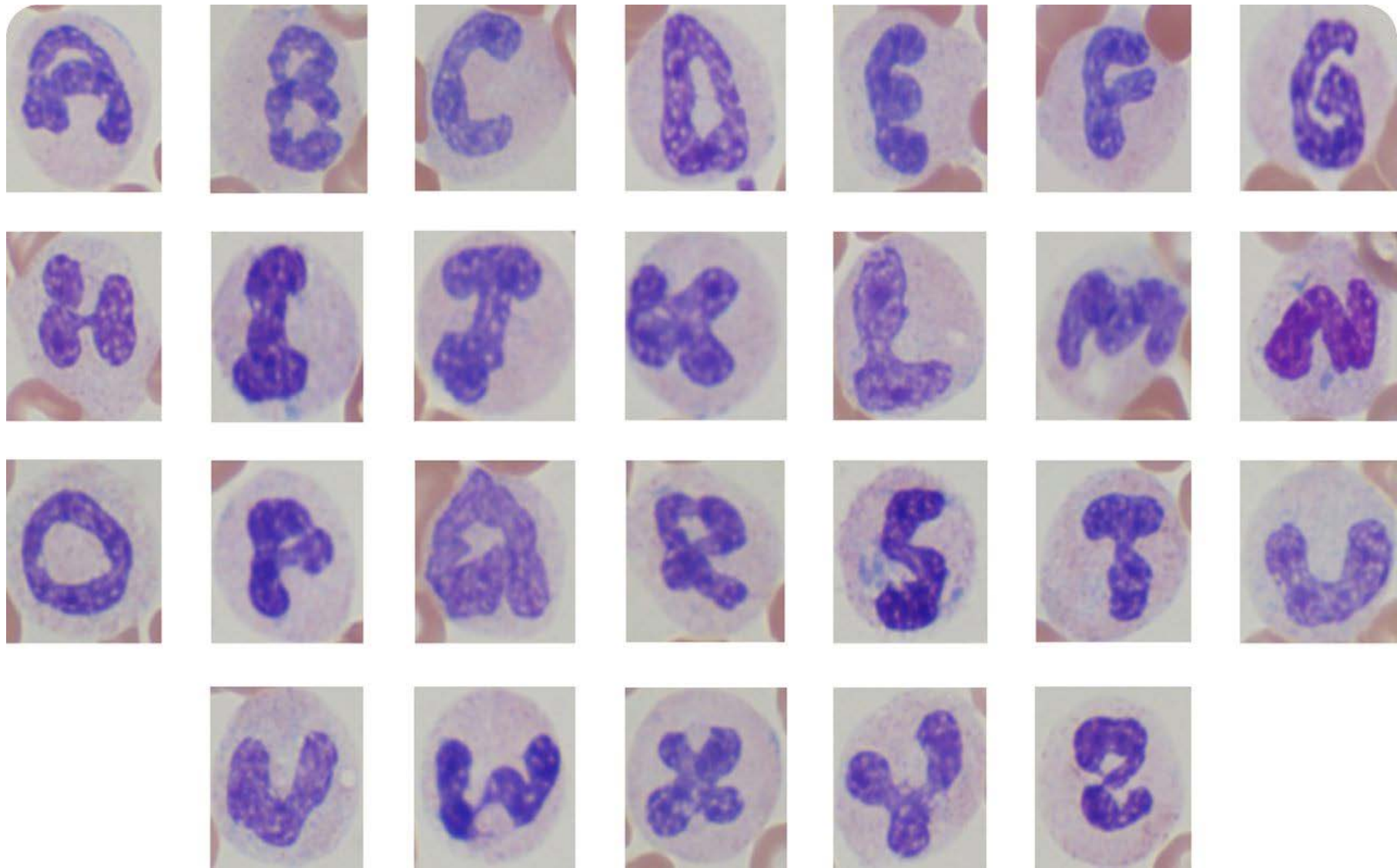
Anemia



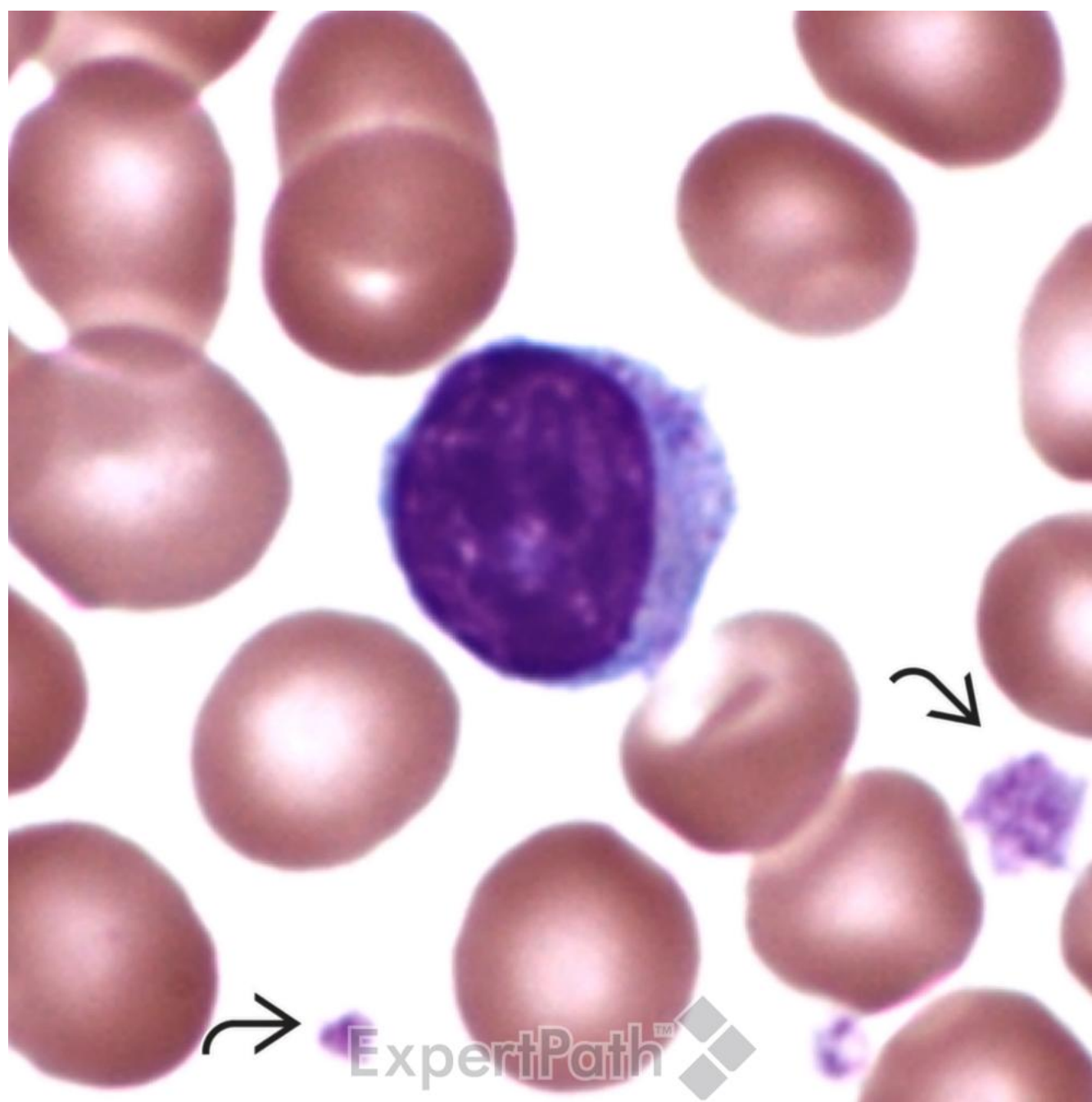
Gammopathy

Zones of a blood smear

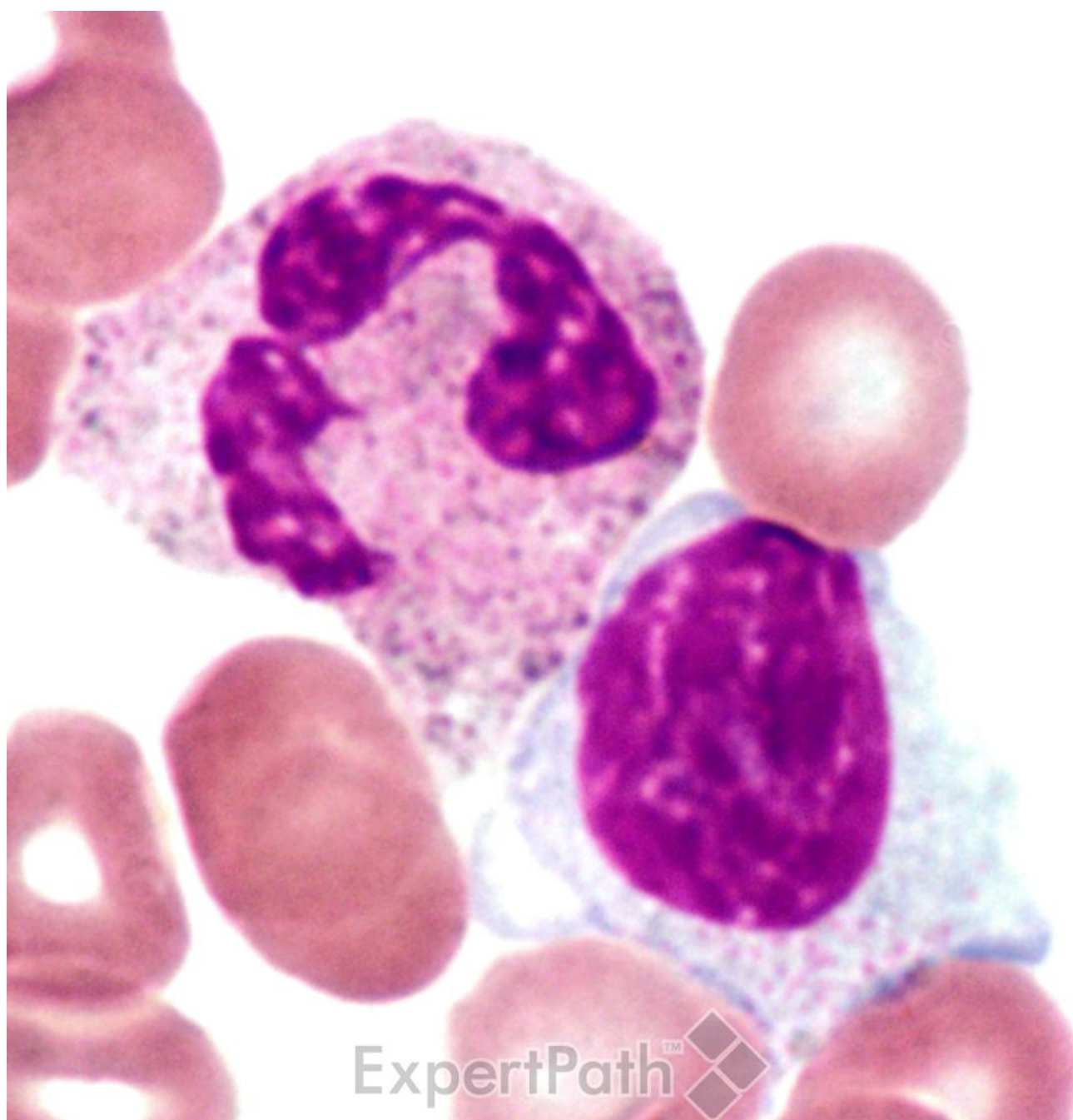




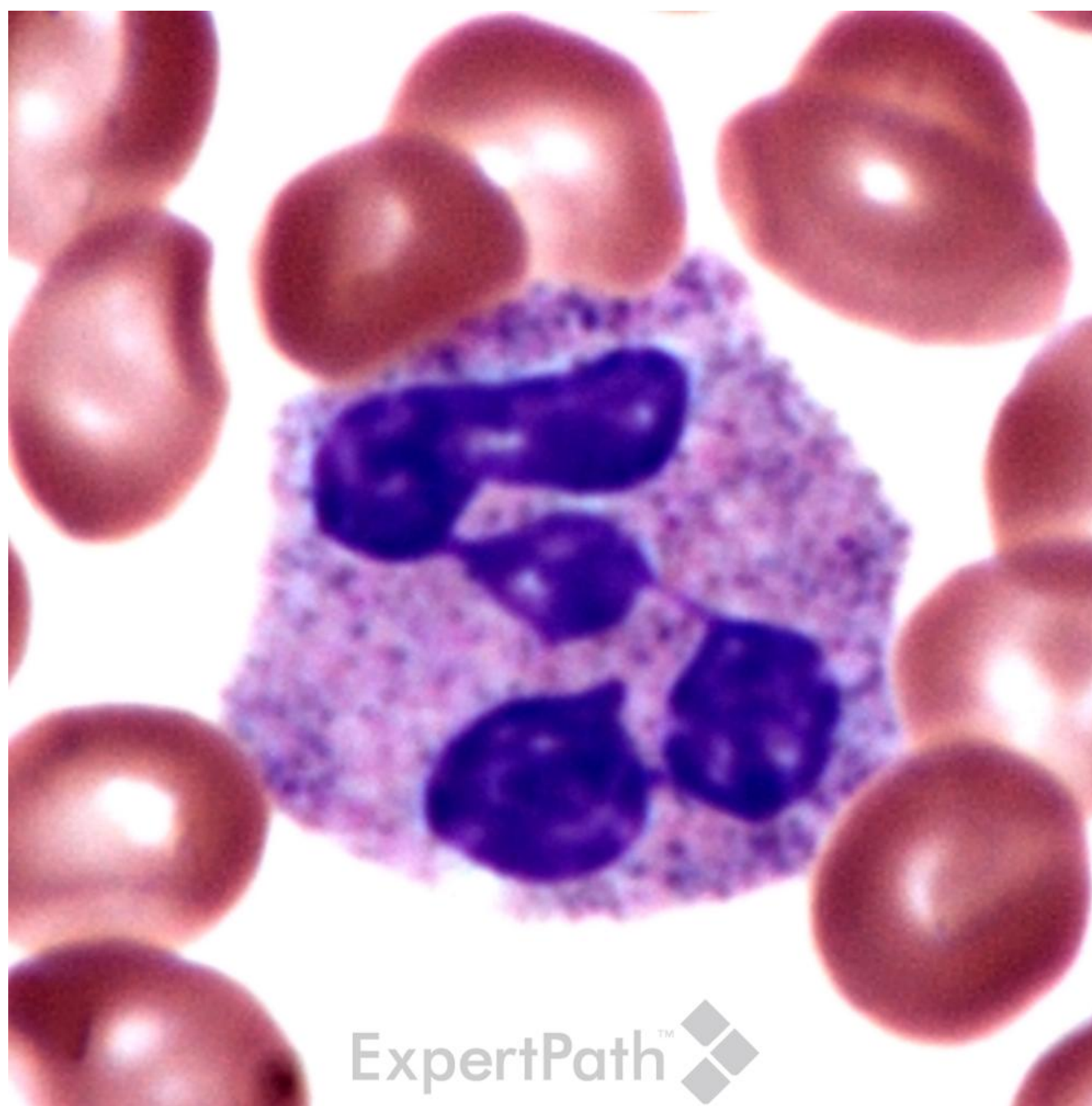
Neutrophil alphabet. Adam S. Morgan, David T. Yang Blood 2013
121:3546; doi:10.1182/blood-2012-12-472357



This peripheral blood smear from a normal adult woman shows uniform erythrocytes with a normal central pallor, normal platelets, and a nonactivated lymphocyte. There is some variation in platelet size (black curved arrow), but all are well granulated.

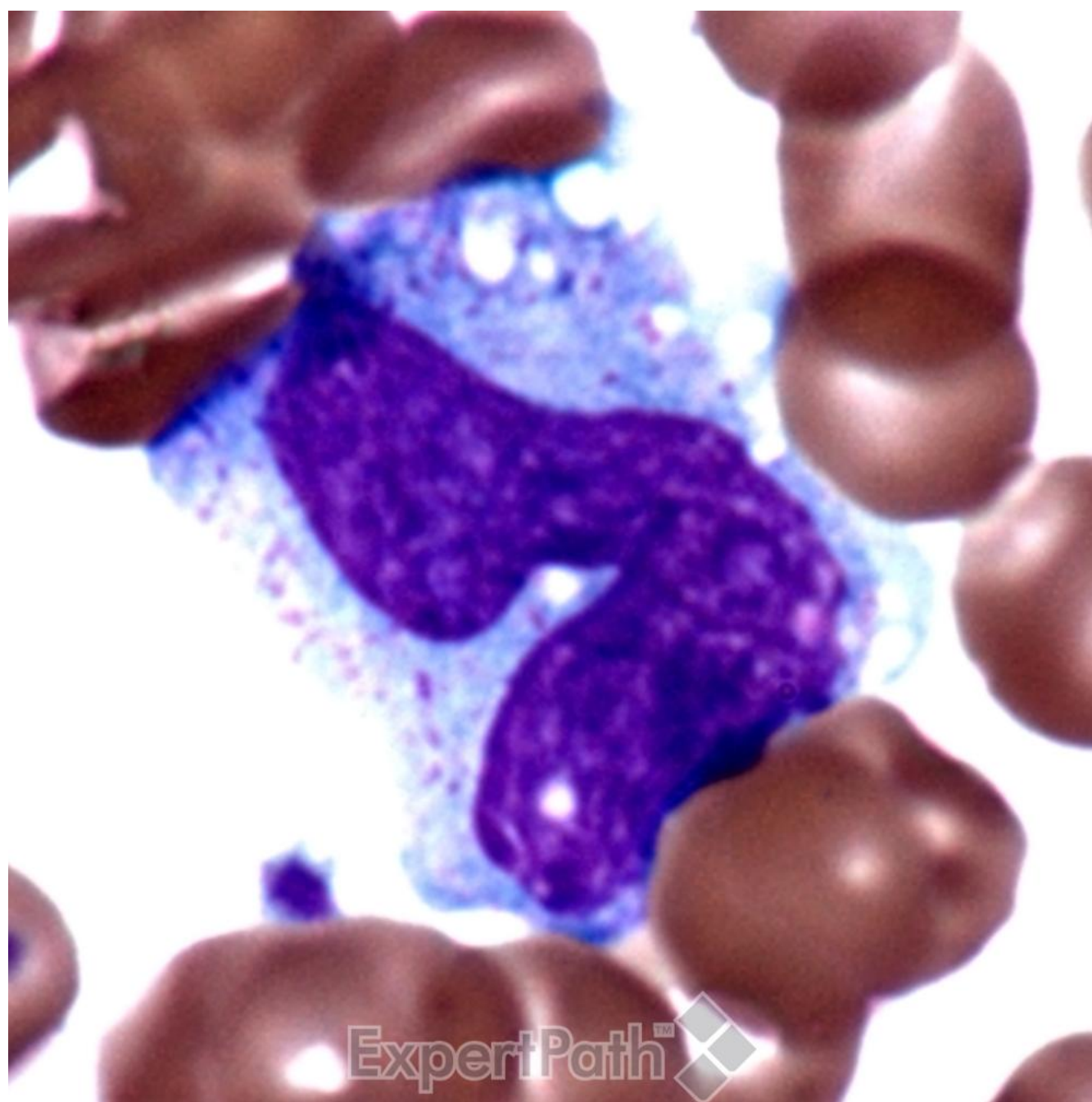


A normal neutrophil and a large granular lymphocyte are evident at high magnification on this blood smear from an adult. Large granular lymphocytes are present in low numbers in blood; cells with this morphology are either NK cells or cytotoxic/suppressor T cells.

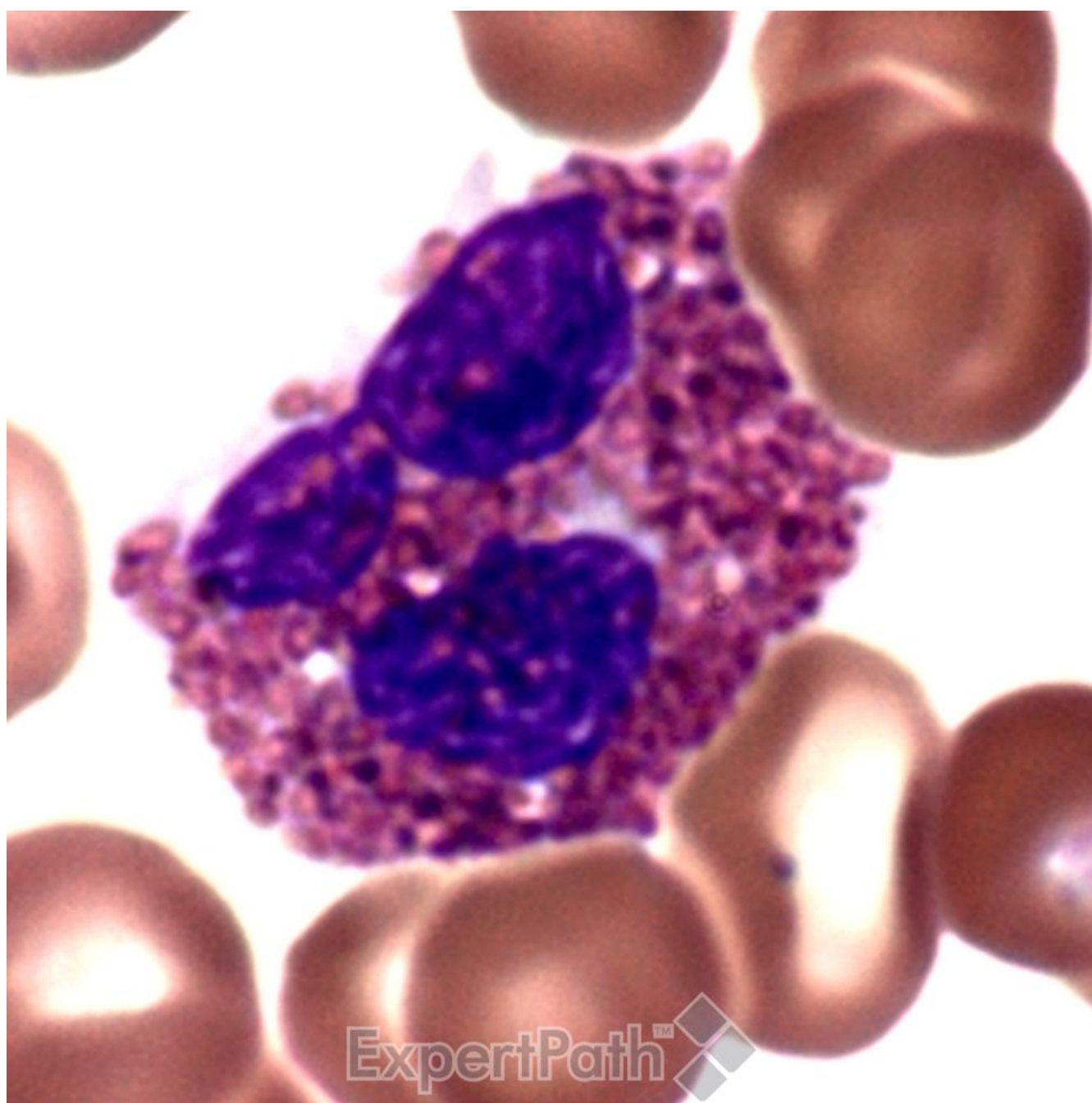


ExpertPath™

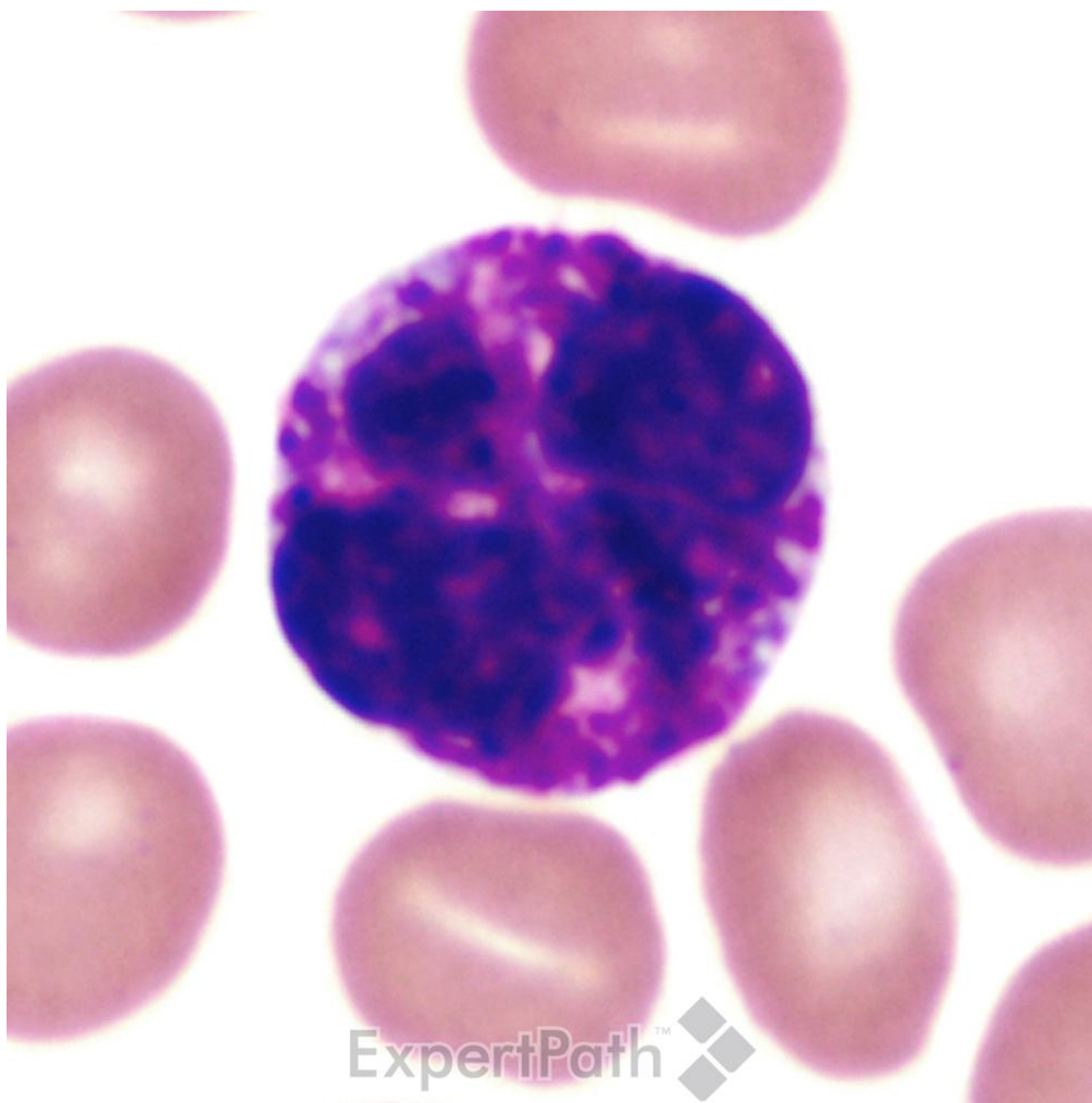
Normal neutrophil nuclear segmentation and normal granulation of the cytoplasm are evident in this circulating neutrophil. Neutrophils typically have 3-5 nuclear lobes with a thin strand of chromatin connecting these lobes. The cytoplasm has a pinkish tint from secondary granules.



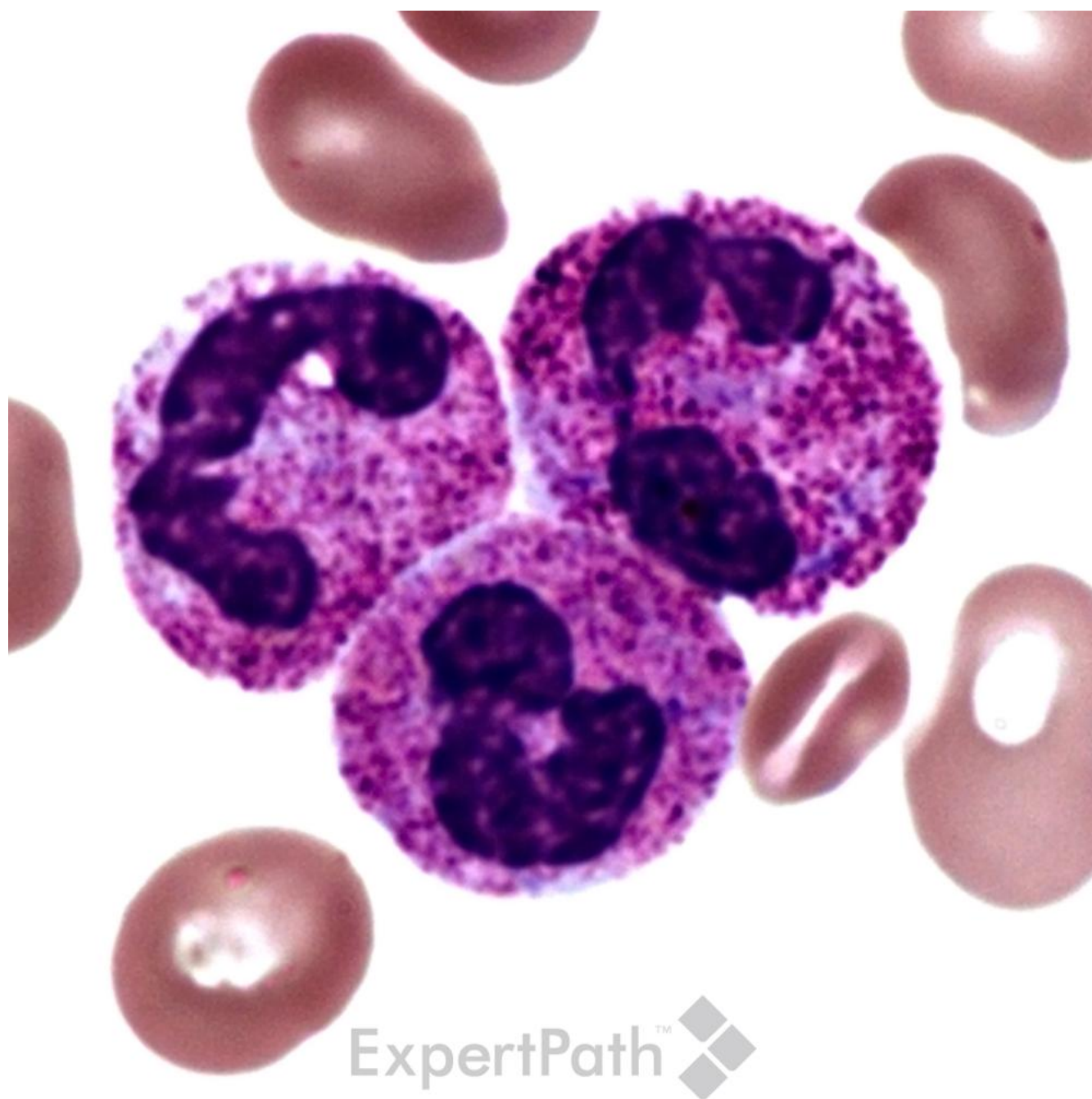
A monocyte is characterized by large size, blue-gray cytoplasm with occasional granules and vacuoles, and a somewhat folded nucleus. The nuclear chromatin has a hills and valleys appearance.



Eosinophils are recognized by the distinctive eosinophilic, refractile appearance of the secondary granules as shown on the blood smear. Eosinophils typically have 2 nuclear lobes, but sometimes 3, as illustrated here.

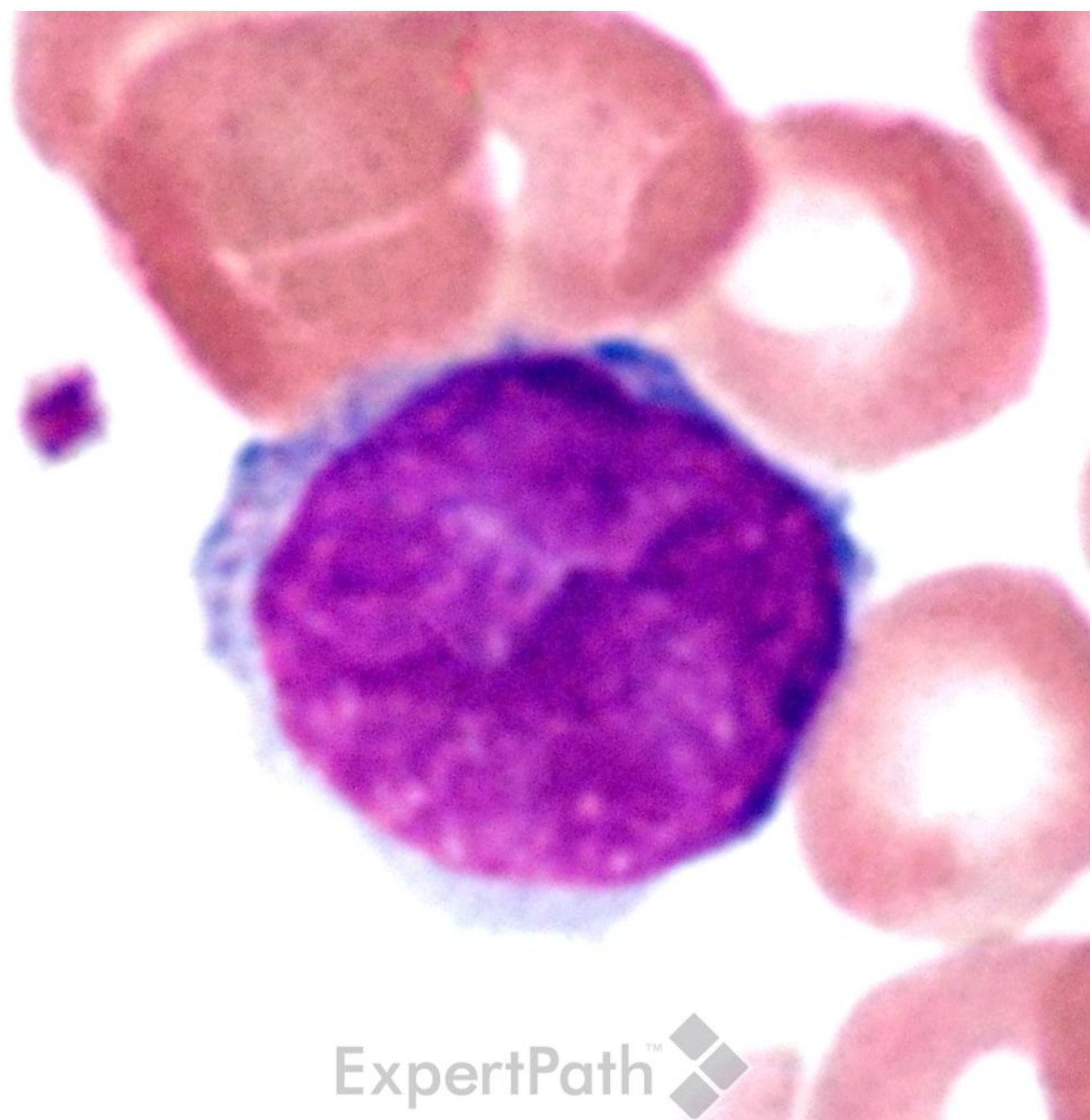

Basophils are the least numerous WBC in the blood. The secondary granules of basophils are dark and coarse. These granules often overlie the nucleus, which typically shows 3-4 nuclear lobes. Note the adjacent normal RBCs.



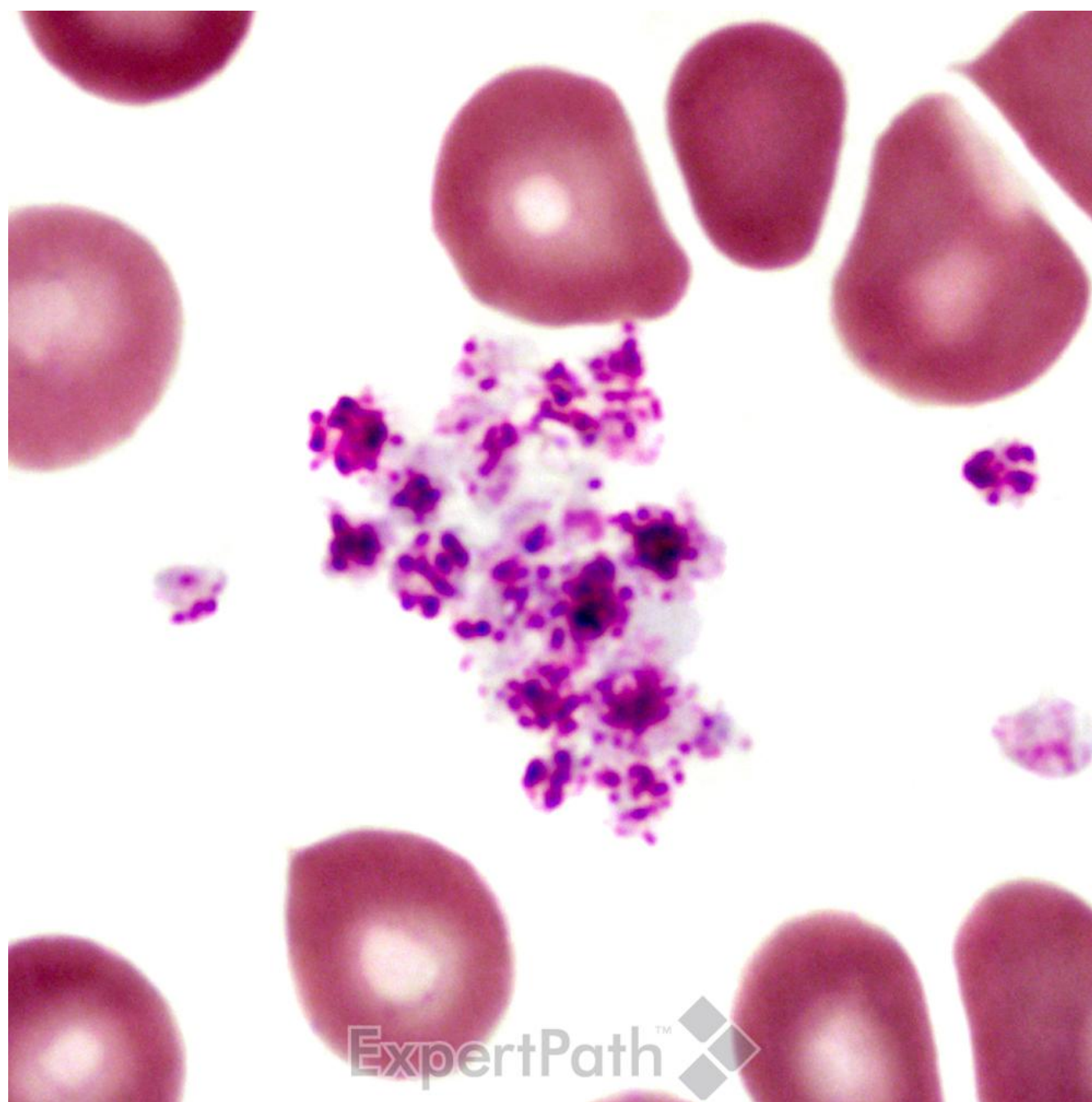
ExpertPath™

Toxic neutrophils, as illustrated here, can mimic basophils because of the prominent basophilic granulation that characterizes an activated neutrophil. This appearance is due to staining changes in the activated secondary granules.



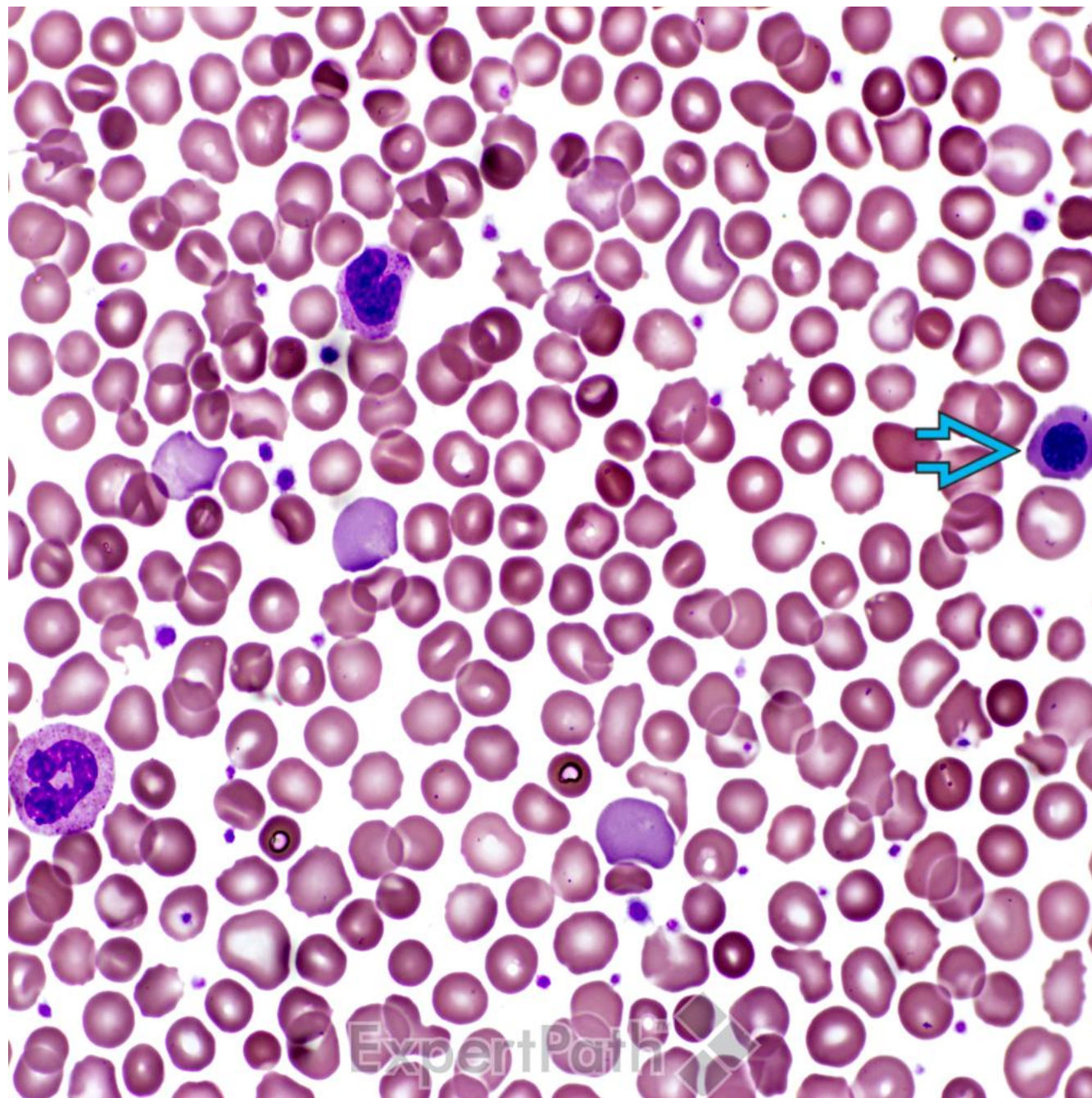
ExpertPath™

Immature lymphocytes are physiologic in infants and young children, even though they are reminiscent of lymphoblasts. These cells have dispersed chromatin and scant cytoplasm. Hematopoietic parameters are normal, a finding useful in the distinction from leukemia.

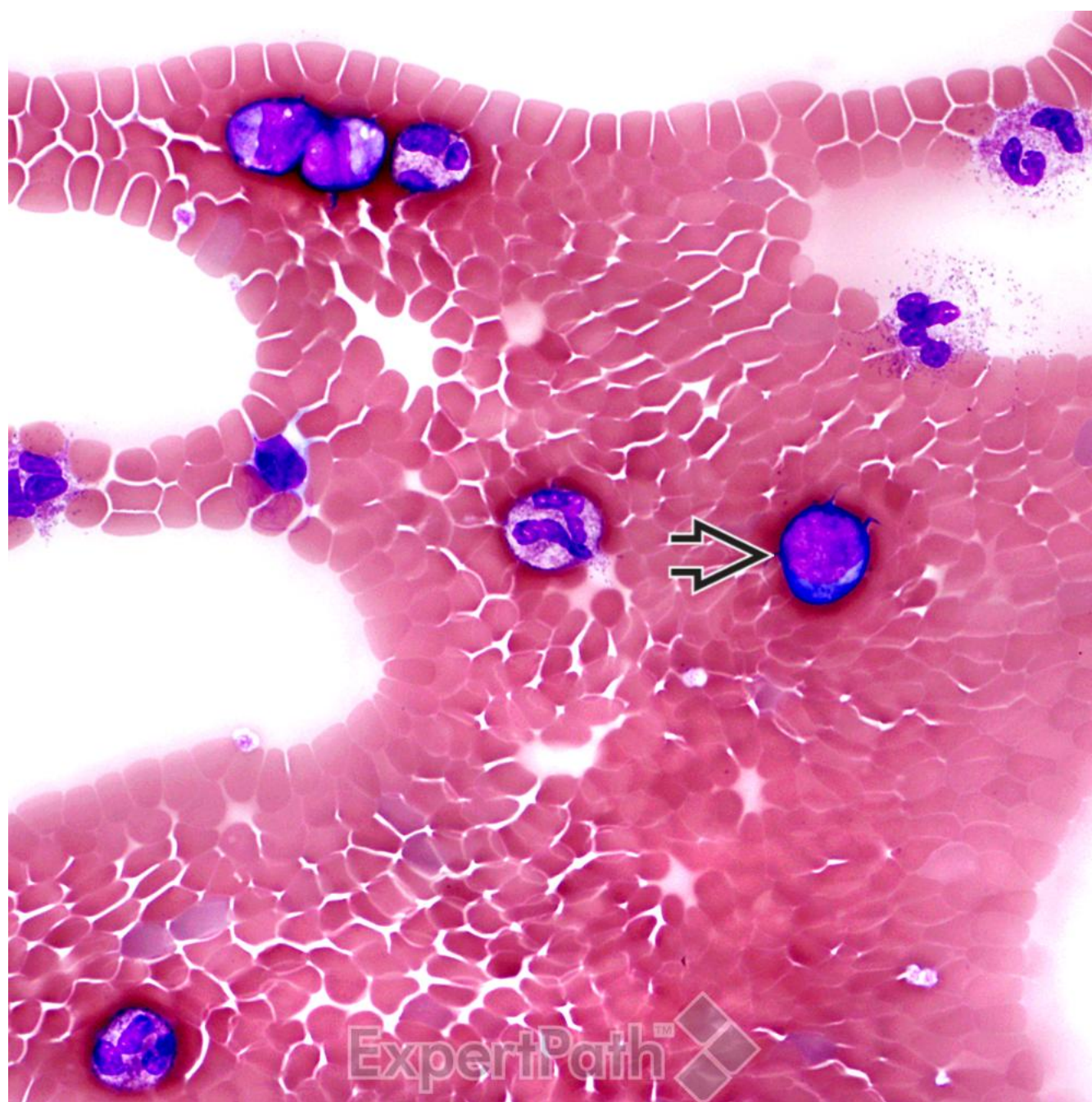

ExpertPath™

Platelet clumping is a common artifact in peripheral blood and may interfere with accurate platelet counts. Manual scanning for platelet clumps is recommended on blood smears when thrombocytopenia is detected by automated counting.



This blood smear from a term newborn shows a high number of erythrocytes and many reticulocytes, which is physiologic for this age. A leukocytosis with left shift is also physiologic for age, as are nucleated red blood cells (cyan open arrow). The leukocytosis, polychromasia, and NRBCs should all decline shortly after birth in



It is important to scan the feather edge of a smear during manual morphologic review to detect cells and even microfilarial worms that have been "dragged" to this portion of the blood smear. Larger cells, such as this immunoblast (black open arrow), are often pulled to the feather edge in the preparation of blood smears as



1

2

3

4

5

6

7

8

9

10

11

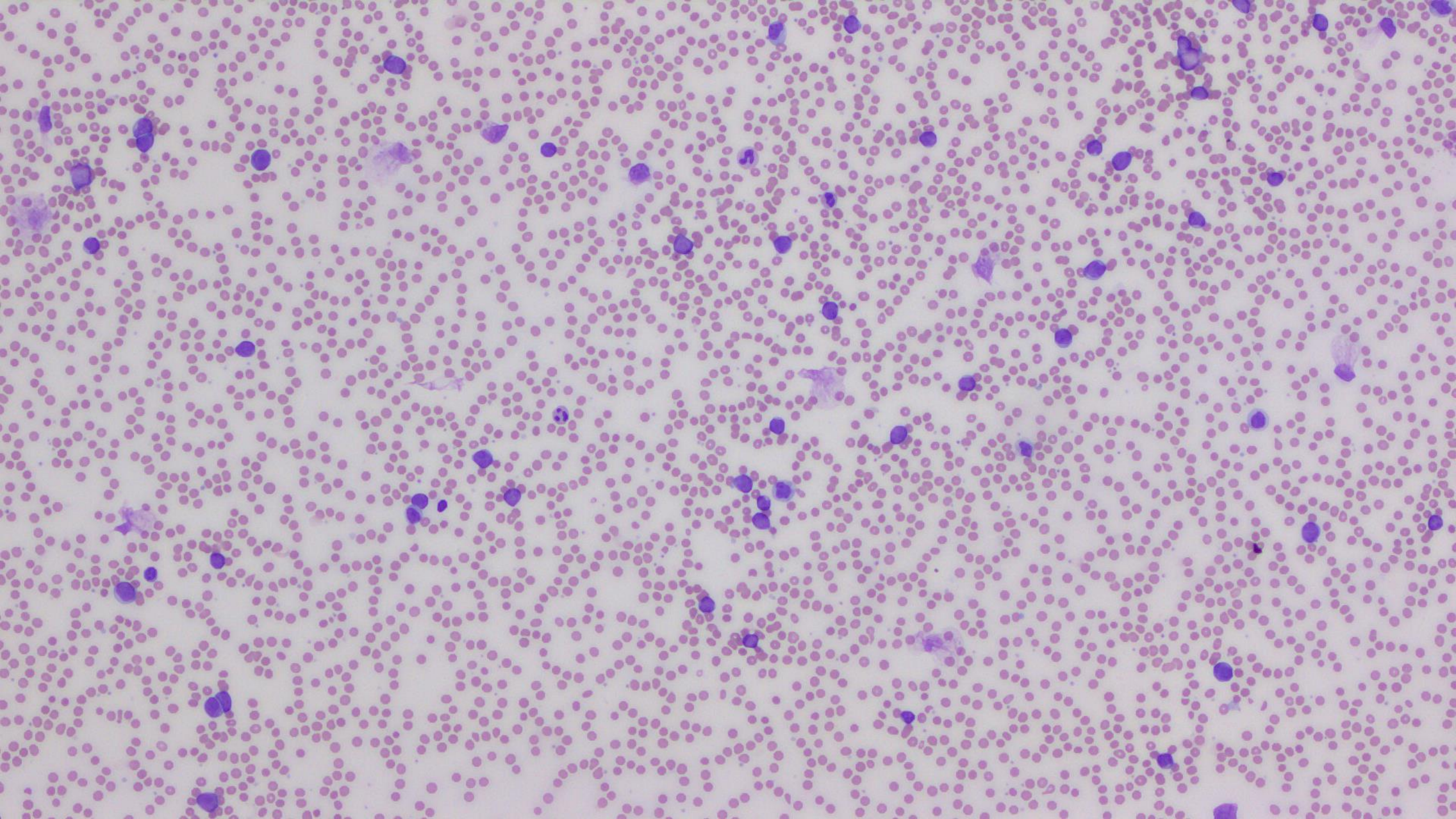
12

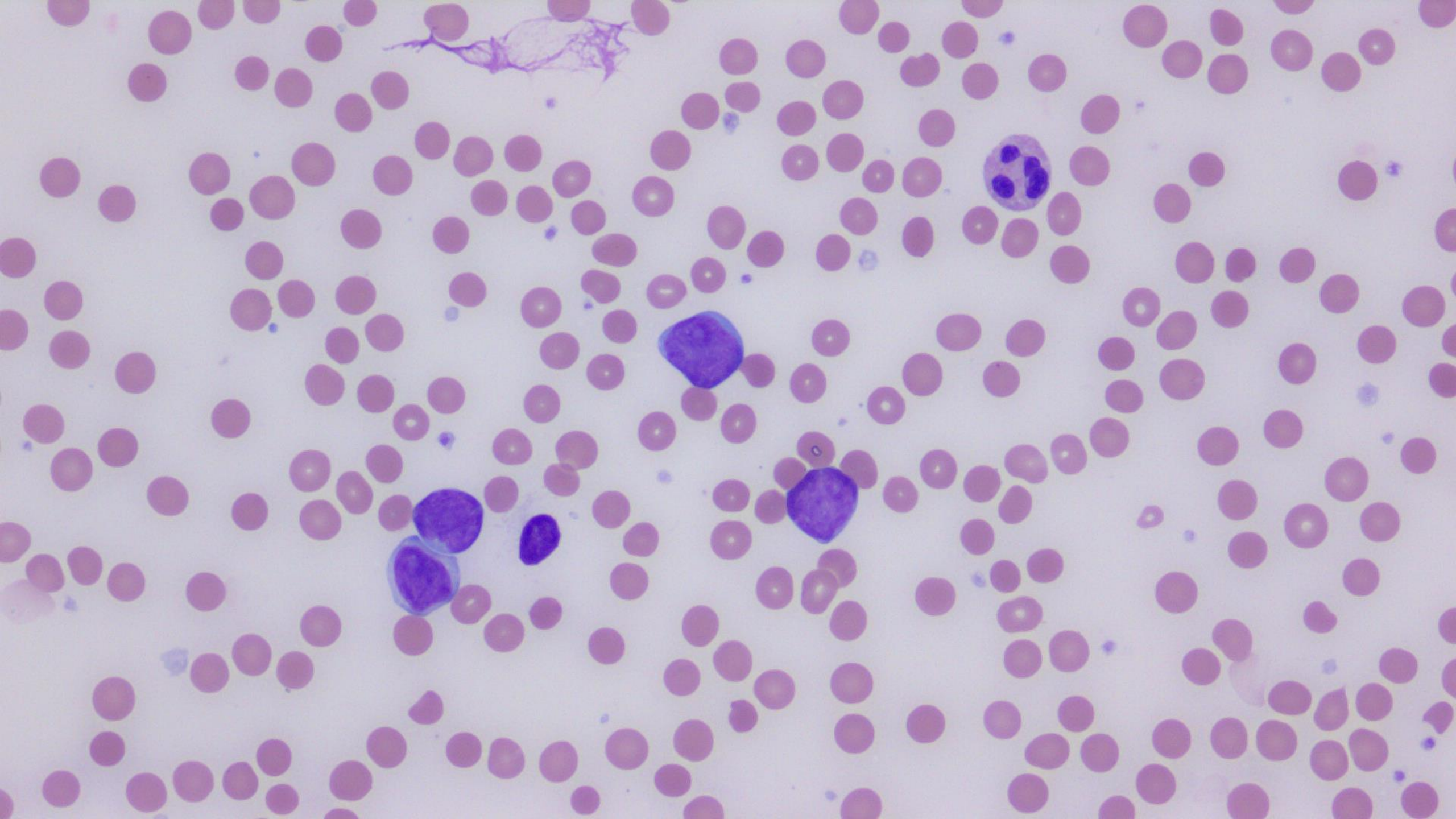
Baker's Secret

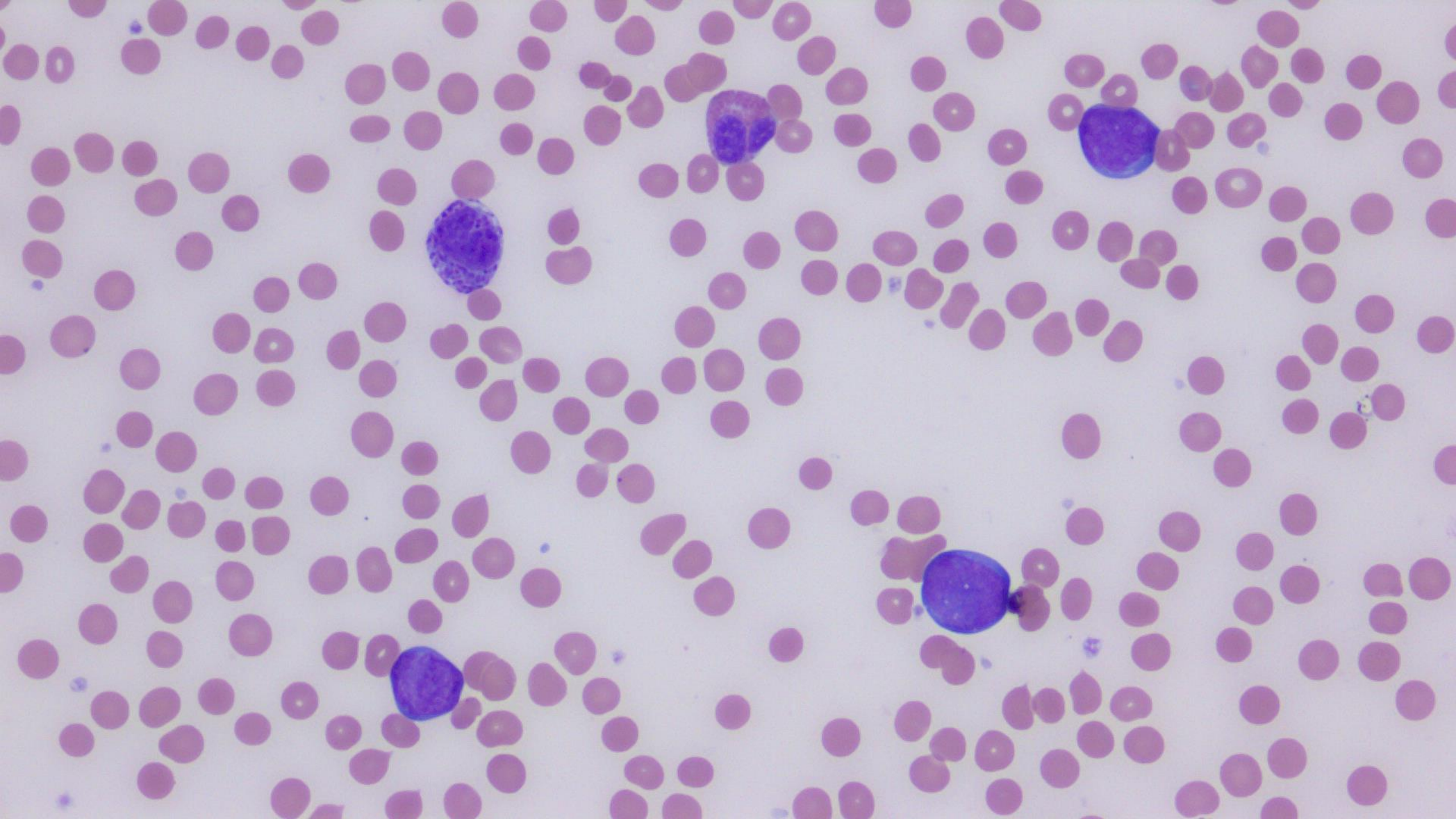
Case 1

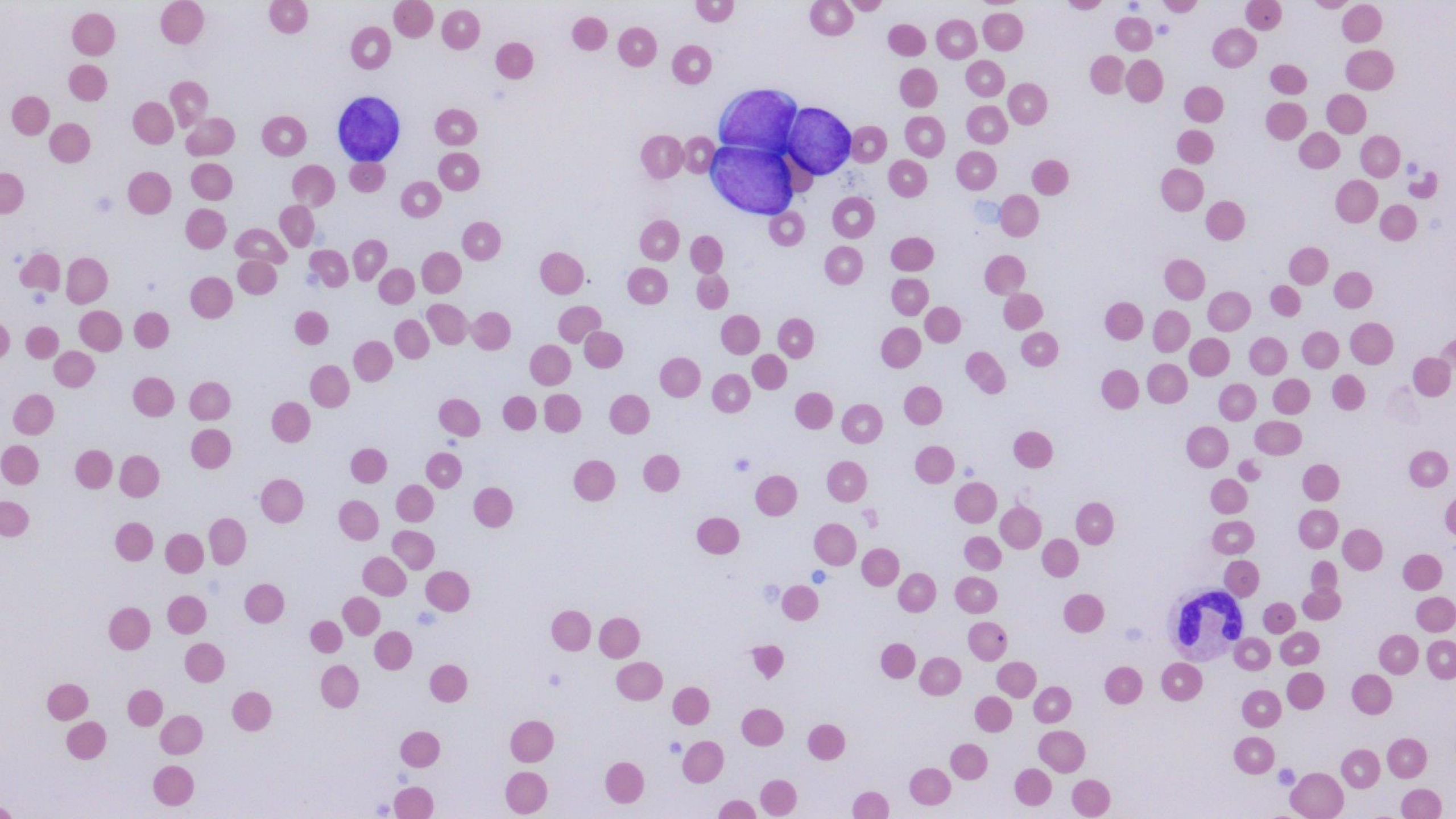
- 4 year-old with pancytopenia.

Lab View	07/18/18 09:03 MDT	07/17/18 19:15 MDT
<input type="checkbox"/> WBC		* C 77.80
<input type="checkbox"/> RBC		L 2.74
<input type="checkbox"/> HGB		L 8.1
<input type="checkbox"/> HCT		L 25.0
<input type="checkbox"/> MCV		91.5
<input type="checkbox"/> MCH		29.5
<input type="checkbox"/> MCHC		32.2
<input type="checkbox"/> PLT		167
<input type="checkbox"/> MPV		L 6.6
<input type="checkbox"/> RDW-CV		13.8
<input type="checkbox"/> RDW-SD		44.2
DIFFERENTIAL		
<input type="checkbox"/> NEUT ABS #		3.11
<input type="checkbox"/> BANDS ABS #		H 4.67
<input type="checkbox"/> LYMPH ABS #		H 12.45
<input type="checkbox"/> MONO ABS #		H 3.11
<input type="checkbox"/> NRBC ABS #		H 0.27
<input type="checkbox"/> SEG %		* 4.0
<input type="checkbox"/> BAND %		6.0
<input type="checkbox"/> LYMPH %		16.0
<input type="checkbox"/> ATYP LYMPH		2.0
<input type="checkbox"/> MONO %		4.0
<input type="checkbox"/> PERCENT NRBC		0
<input type="checkbox"/> OTHER		* (c) 68
SMUDGE CELLS		Moderate









Precursor B-cell acute lymphoblastic leukemia

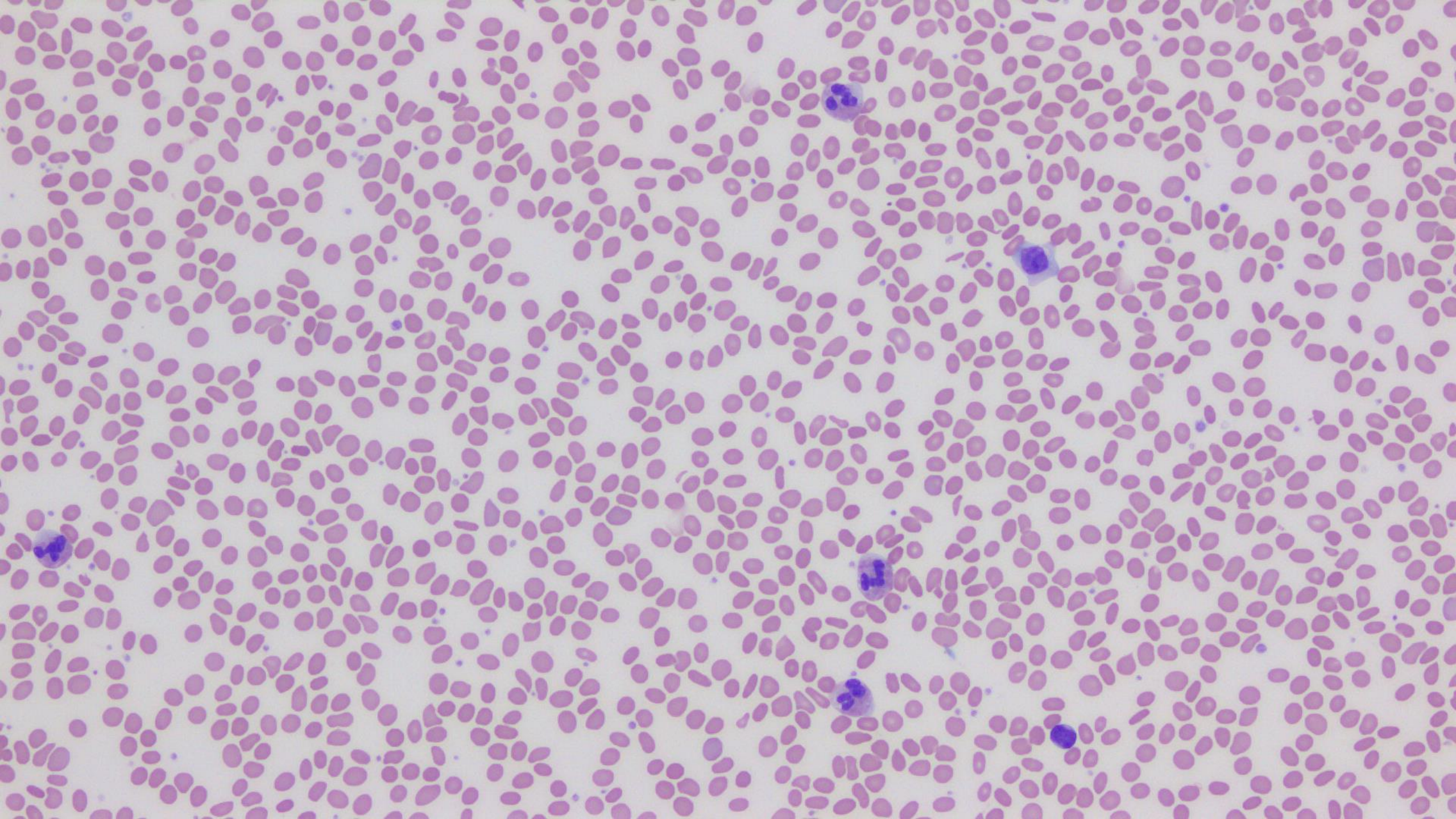
- Terminology
 - B-ALL is neoplasm of precursors (lymphoblasts) committed to B-cell lineage
 - When blood and bone marrow are extensively involved, acute lymphoblastic leukemia (B-ALL) is appropriate term
 - When disease is confined to tissue mass with absent or minimal blood and marrow involvement, term lymphoblastic lymphoma (B-LBL) is used
 - If patient presents with tissue mass and blood and bone marrow involvement, 25% blasts in marrow defines leukemia (B-ALL)
 - Blasts express immature markers [CD34 and TdT (terminal deoxynucleotidyl transferase)] and B-cell markers (CD19, CD10, CD79a, subset CD20)
- Etiology/Pathogenesis
 - Causes of ALL remain largely unknown
 - Many ALLs are thought to be congenital
 - Genetic abnormalities may result in constitutively activated oncogenes, activated kinase activity, or altered transcriptional regulation
 - Certain syndromes have increased incidence of B-ALL
- Clinical Issues
 - B-ALL is most common childhood neoplasm
 - Complex prognostic systems including clinical, biologic, cytogenetic findings, and response to therapy
 - Overall excellent prognosis
 - Intensive multiagent chemotherapy is mainstay treatment
 - Patients at very high risk may benefit from allogeneic SCT
 - Intrathecal prophylactic therapy routinely done to prevent CNS relapse
- Ancillary Tests
 - Routine karyotype is required on all new B-ALL cases
 - Specific FISH panel is required by Children's Oncology Group (COG) protocol
 - Molecular testings increasingly performed

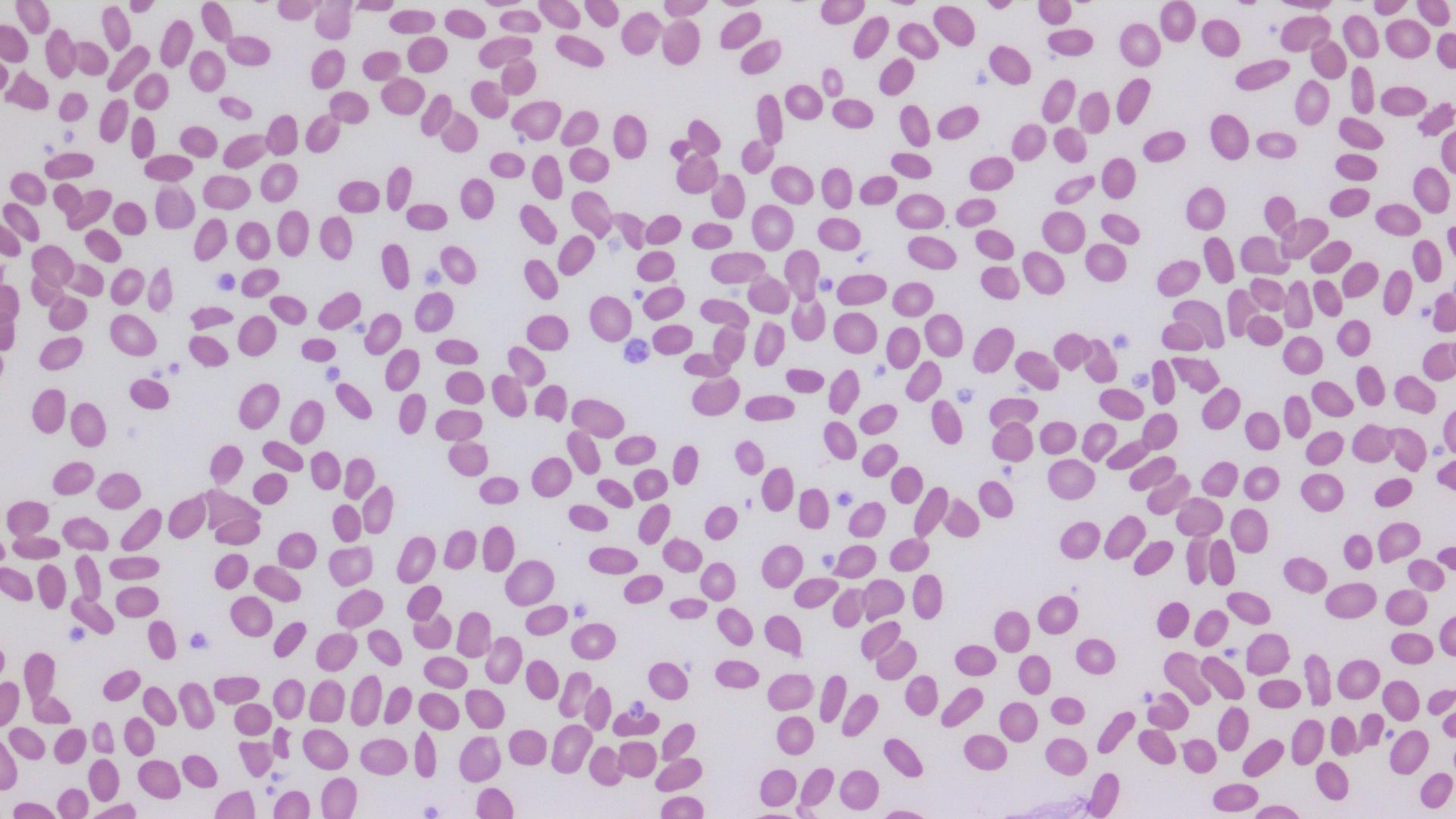
Case 2

- 2 year-old asymptomatic. Dad from Senegal has “blood disease.”

PERIPHERAL BLOOD:

WBC:	16.30 x10 E3/mm3	Neut:	46%	Meta:	0%
RBC:	4.88 x10E6/mm3	Lymph:	41%	Myelo:	0%
Hgb:	12.4 gm/dL	Var lymph:	0%	Promy:	0%
Hct:	35.5 %	Mono:	10%	Blast:	0%
MCV:	72.7 fL	Eos:	2%	nRBC:	0/100WBI
MCHC:	35.0 Gm/dL	Baso:	1%	Other:	0%
RDW:	18.1 %				
Plt:	401 x10E3/mm3				






Hereditary Elliptocytosis

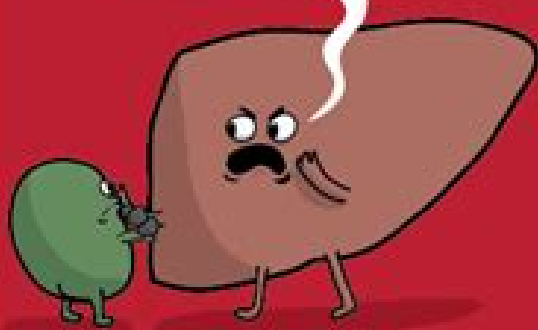
- Intrinsic membrane protein abnormalities → alterations in RBC membrane function, RBC shape, and hemolysis (in some cases)
- Point mutations, gene deletions or insertions, and mRNA processing defects in α spectrin, β spectrin, band 4.1, and glycophorin C genes
- Clinical Issues
 - Familial anemia
 - > 85% of HE asymptomatic
 - Gene mutation testing generally not warranted
 - Red cell transfusion for symptomatic anemia
 - May confirm disorder with presence of elliptocytes in maternal or paternal blood smear
- Microscopic Features
 - Elliptocytes on blood smear
 - Increased polychromasia secondary to bone marrow response to anemia
 - Bone marrow shows erythroid hyperplasia

what is it, gall bladder?
can't you see I have a
lot to do?

I made
these

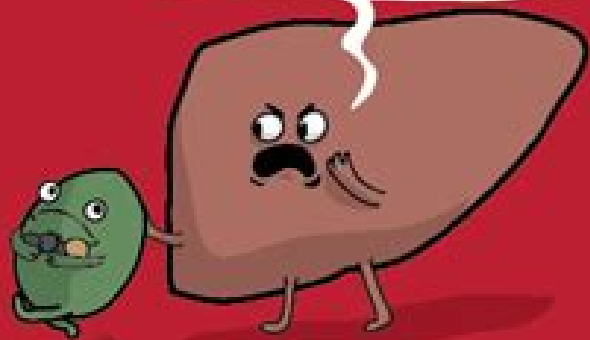


you made STONES?



YOU'RE JUST SUPPOSED
TO HOLD WHAT I GIVE YOU!

GET OUT! GO ON!



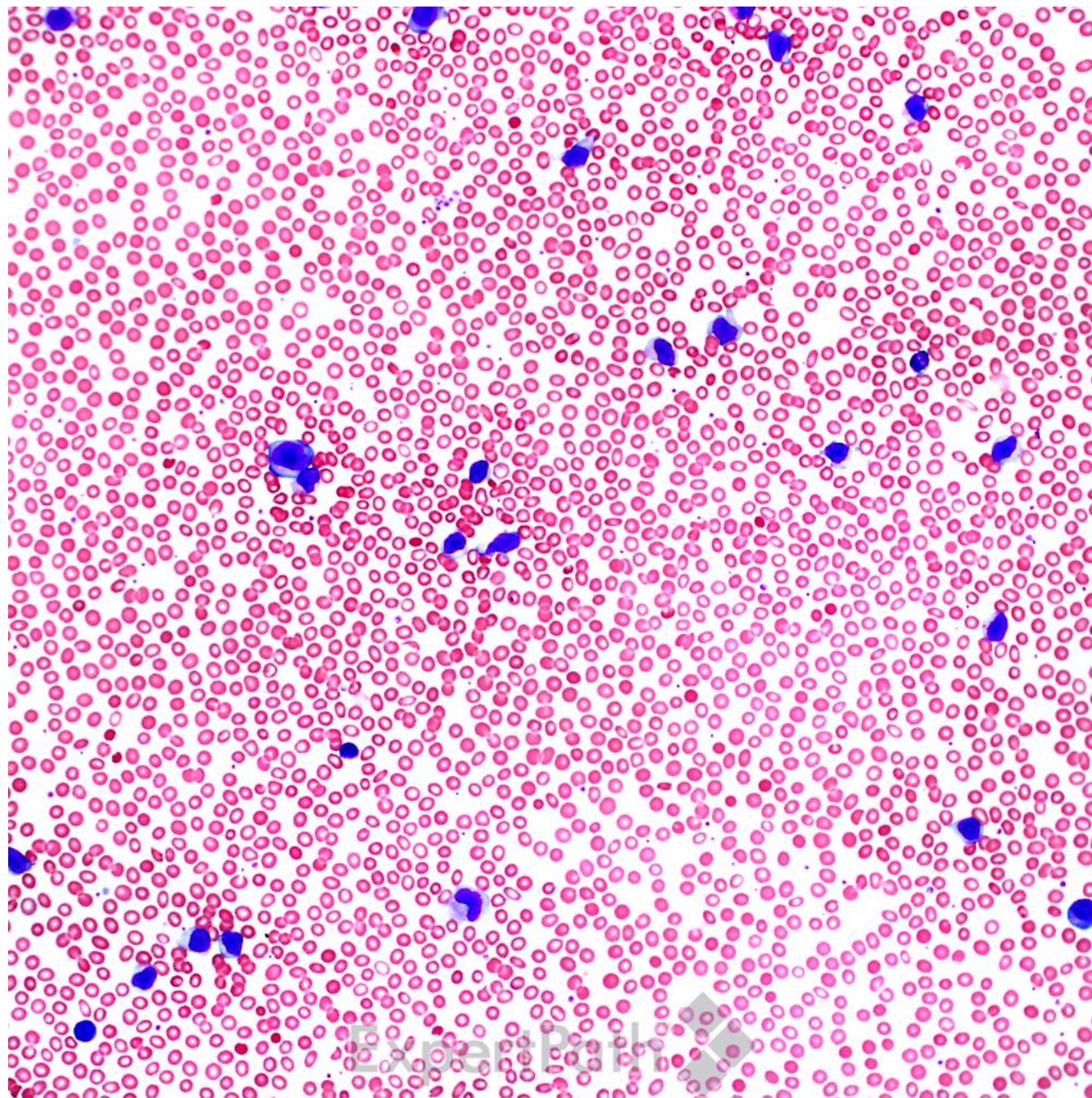
I made
these



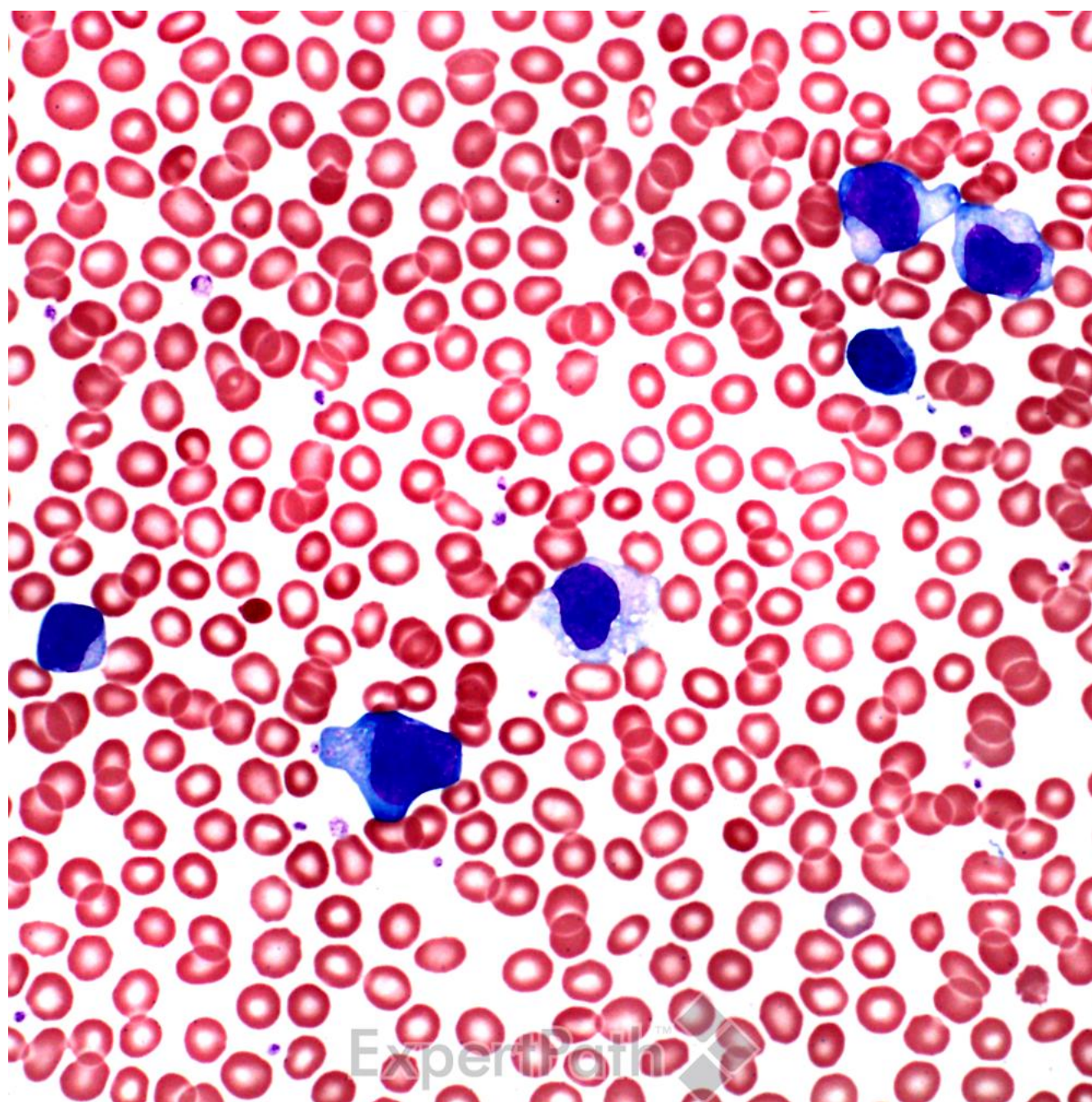
Case 3

- 16 year-old female presents with fever after kissing a boy (ew!)





A prominent lymphocytic reaction is present in this peripheral blood smear from a 16-year-old female with infectious mononucleosis and EBV-positive serology.



Downey type II lymphocytes are abundant in this smear. They are intermediate in size and have mature smudged chromatin, inconspicuous nucleoli, and moderately abundant pale blue cytoplasm with peripheral basophilia.

Infectious mononucleosis

- CBC and peripheral blood smear
 - Peripheral blood smear findings often precede heterophile antibody positivity in EBV infection
 - Morphologic findings help in making diagnosis
 - Confirmation of EBV infection is required in heterophile negative cases
 - Diagnosis of CMV infection requires laboratory confirmation
- Heterophile antibody (monospot) test
 - Positive
 - Majority of EBV-associated IM
 - 90% of adolescents, 80% of children > 4 years of age
 - EBV-specific serology unnecessary to make diagnosis
 - Occasional patients with lymphoma or hepatitis are positive
 - Negative
 - 50% of young children with symptomatic EBV infection

Case 4

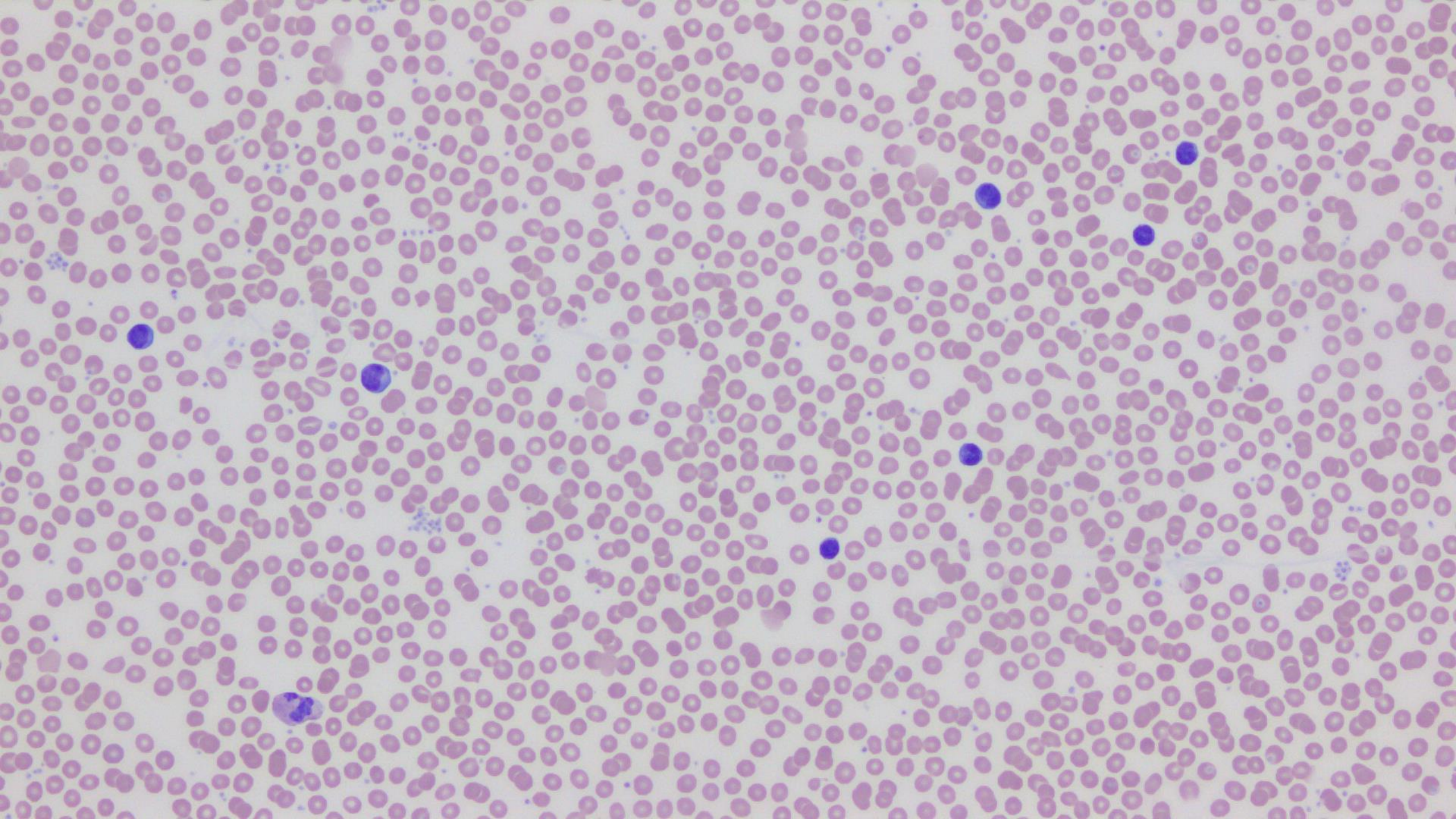
- 5 month-old male with coughing fits.

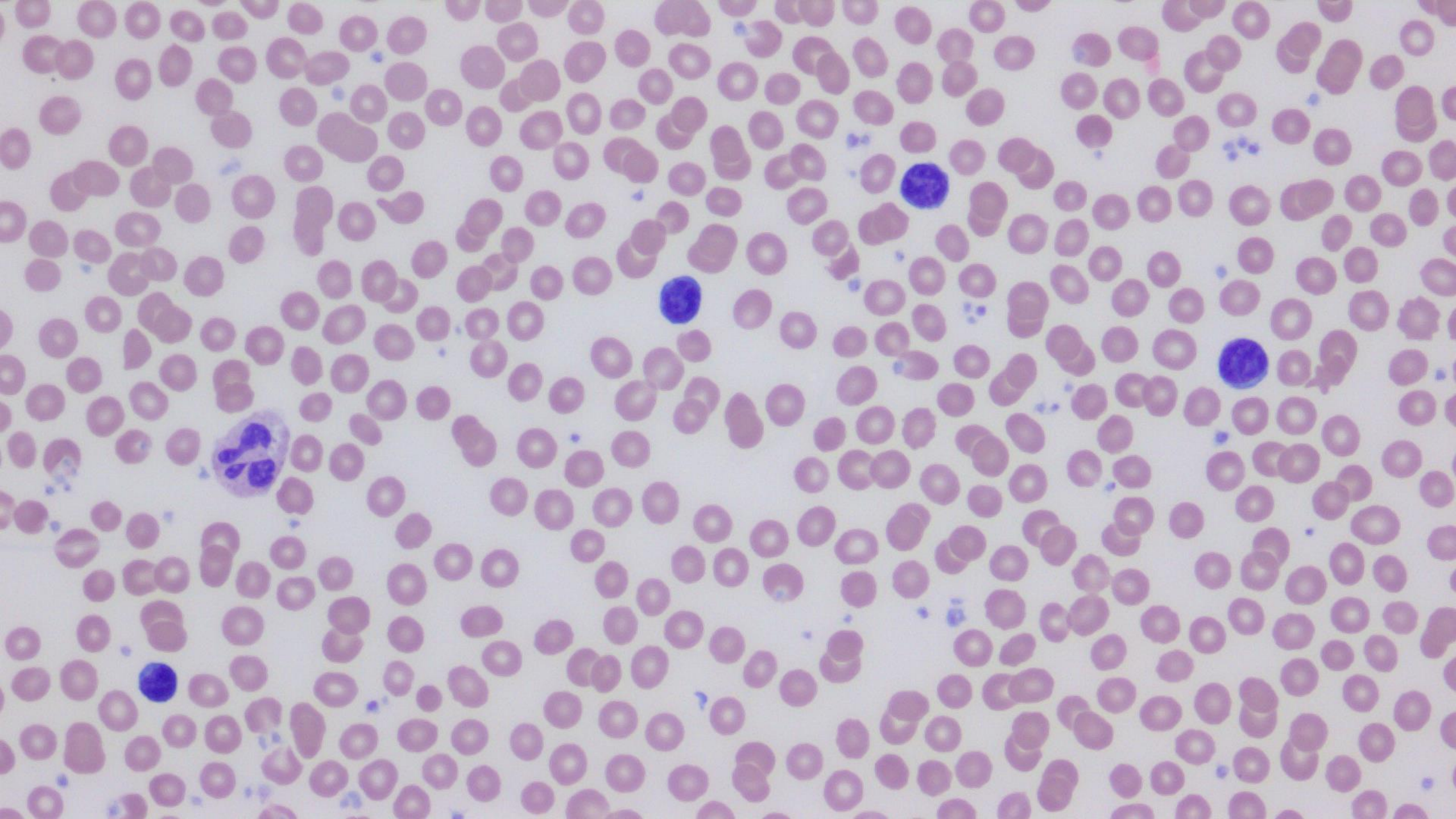
PERIPHERAL BLOOD:

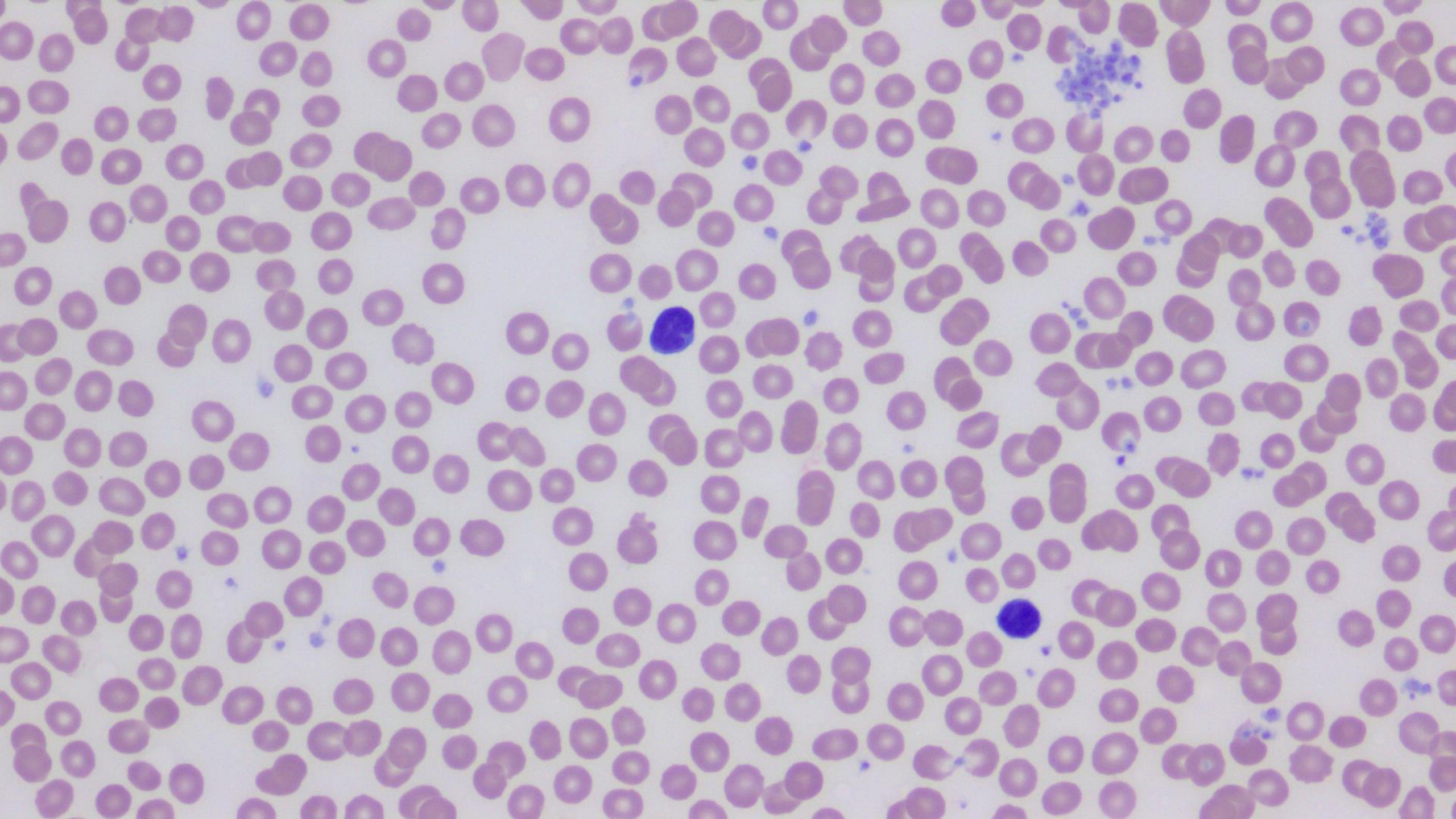
WBC: 14.60 x10 E3/mm3
RBC: 4.44 x10E6/mm3
Hgb: 12.1 gm/dL
Hct: 36.9 %
MCV: 83.1 fL
MCHC: 32.7 Gm/dL
RDW: 14.1 %
Plt: 410 x10E3/mm3

Neut: 30%
Lymph: 65%
Var lymph: 0%
Mono: 1%
Eos: 3%
Baso: 1%

Meta: 0%
Myelo: 0%
Promy: 0%
Blast: 0%
nRBC: 0/100WBC
Other: 0%

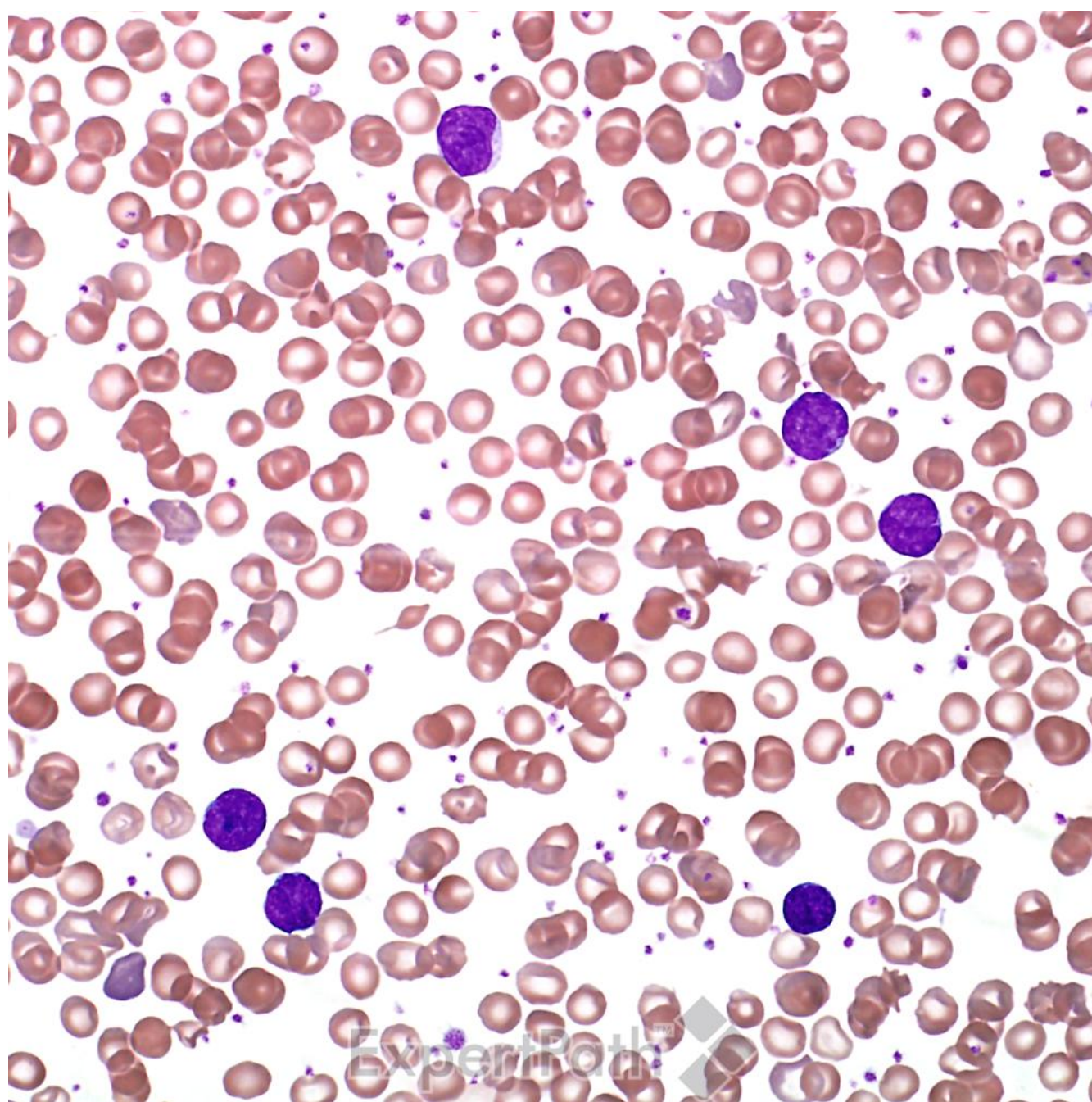






Pertussis

- Microscopic
 - **Pertussis**
 - Mature-appearing lymphocytes (primarily helper T cells)
 - Many cleaved or convoluted nuclei
- Pertussis
 - *B. pertussis* is exclusively human pathogen
 - Upper respiratory infection without dissemination
 - Pertussis toxin reduces L-selectin expression on lymphocytes, preventing their migration into tissue
 - T cells accumulate in blood

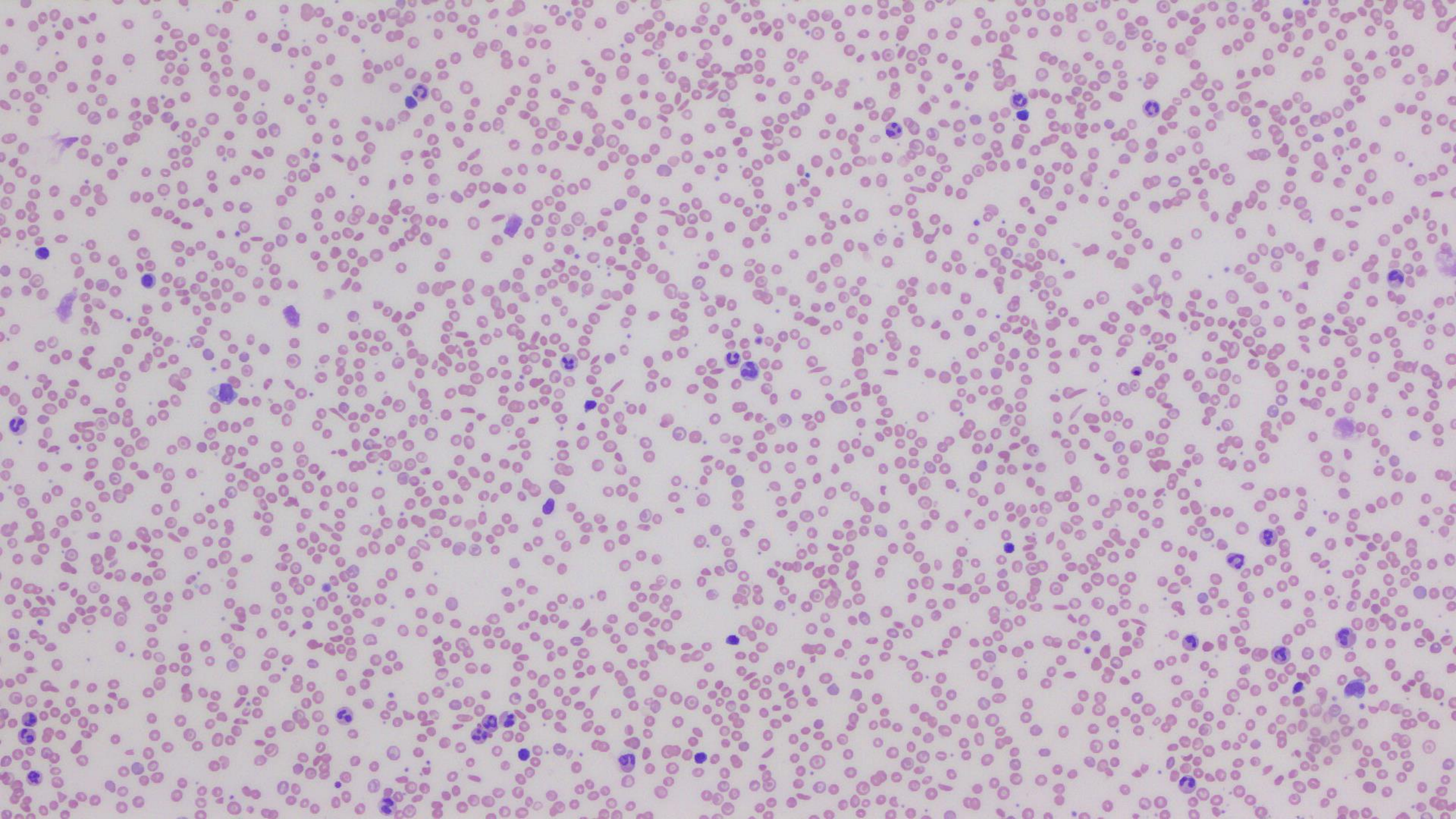


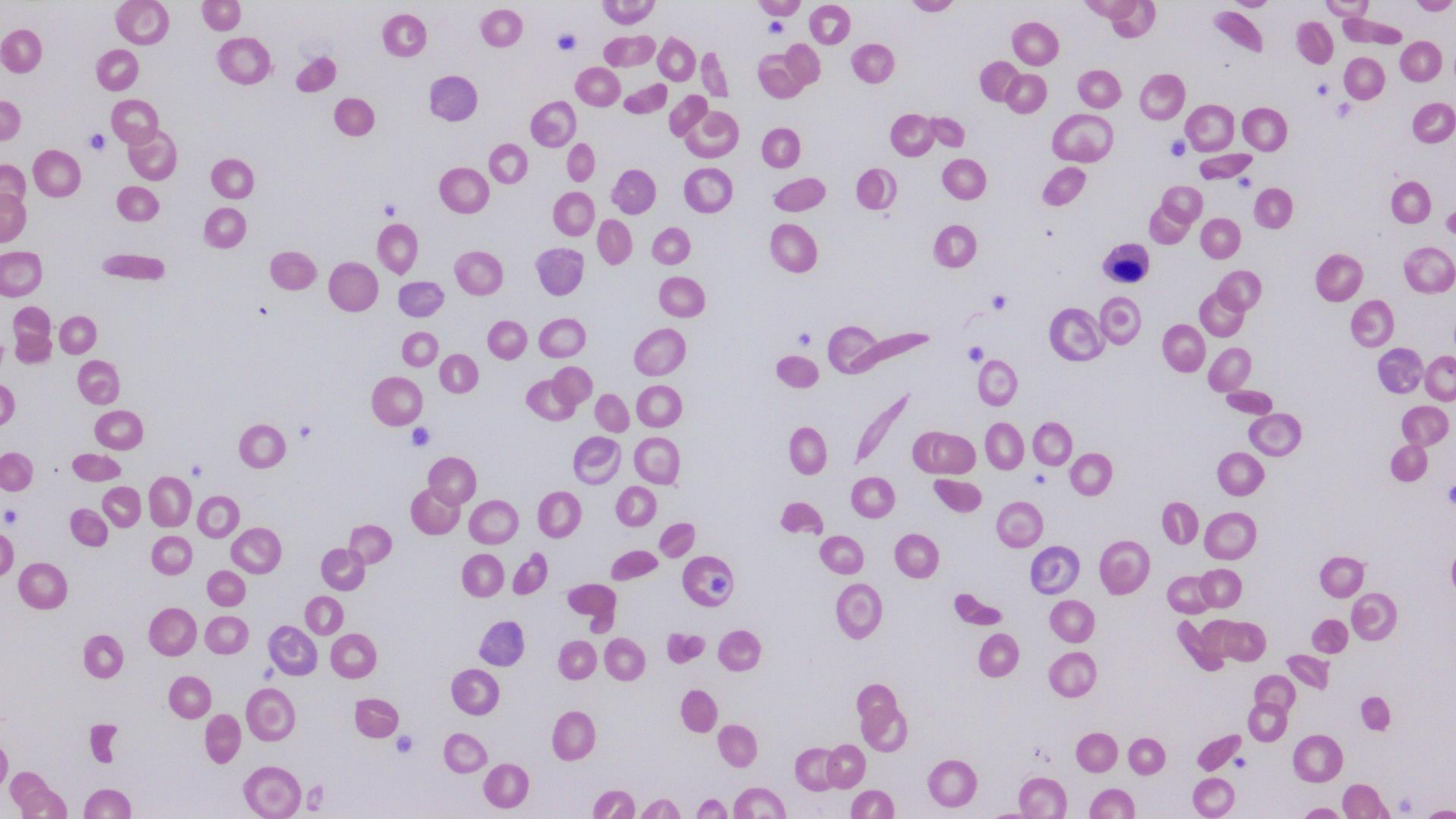
Peripheral blood smear from a child with pertussis shows a predominance of small lymphocytes with condensed chromatin and scant cytoplasm. Red blood cells and platelets are normal in number, although thrombocytosis is common.

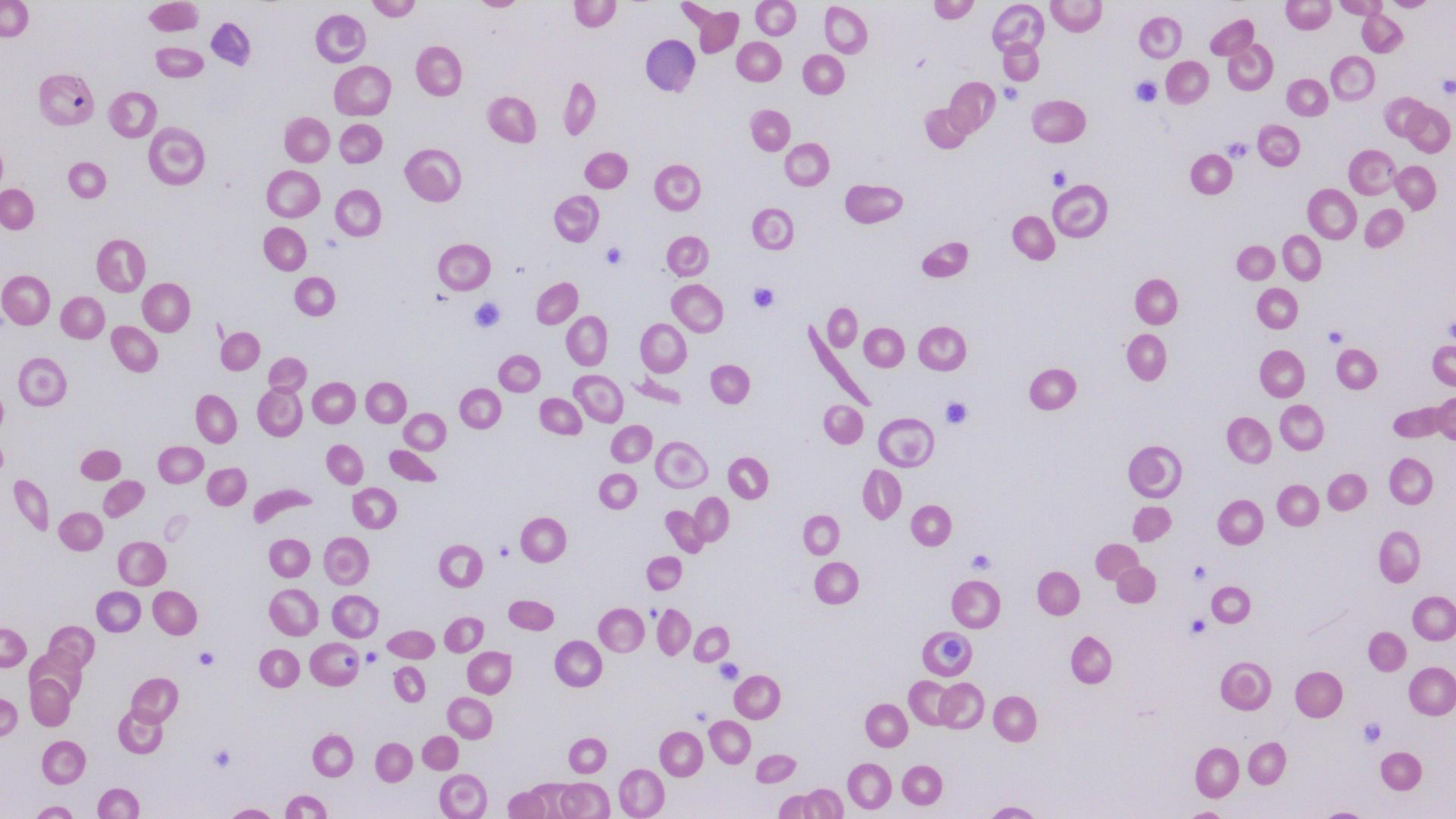
Case 5

- 3 year-old with chest pain.

CBC	
<input type="checkbox"/> WBC	H 17.10
<input type="checkbox"/> RBC	L 2.02
<input type="checkbox"/> HGB	* C 6.3
<input type="checkbox"/> HCT	L 19.1
<input type="checkbox"/> MCV	94.5
<input type="checkbox"/> MCH	H 31.1
<input type="checkbox"/> MCHC	32.9
<input type="checkbox"/> PLT	200
<input type="checkbox"/> MPV	10.3
<input type="checkbox"/> RDW-CV	H 23.1
<input type="checkbox"/> RDW-SD	H 76.1
DIFFERENTIAL	
<input type="checkbox"/> NEUT ABS #	H 10.09
<input type="checkbox"/> BANDS ABS #	0.34
<input type="checkbox"/> LYMPH ABS #	H 5.30
<input type="checkbox"/> MONO ABS #	0.86
<input type="checkbox"/> EOS ABS #	0.51
<input type="checkbox"/> NRBC ABS #	H 0.62
<input type="checkbox"/> SEG %	* 59.0
<input type="checkbox"/> BAND %	2.0
<input type="checkbox"/> LYMPH %	31.0
<input type="checkbox"/> MONO %	5.0
<input type="checkbox"/> EOS %	3.0
<input type="checkbox"/> PERCENT NRBC	(c) 12







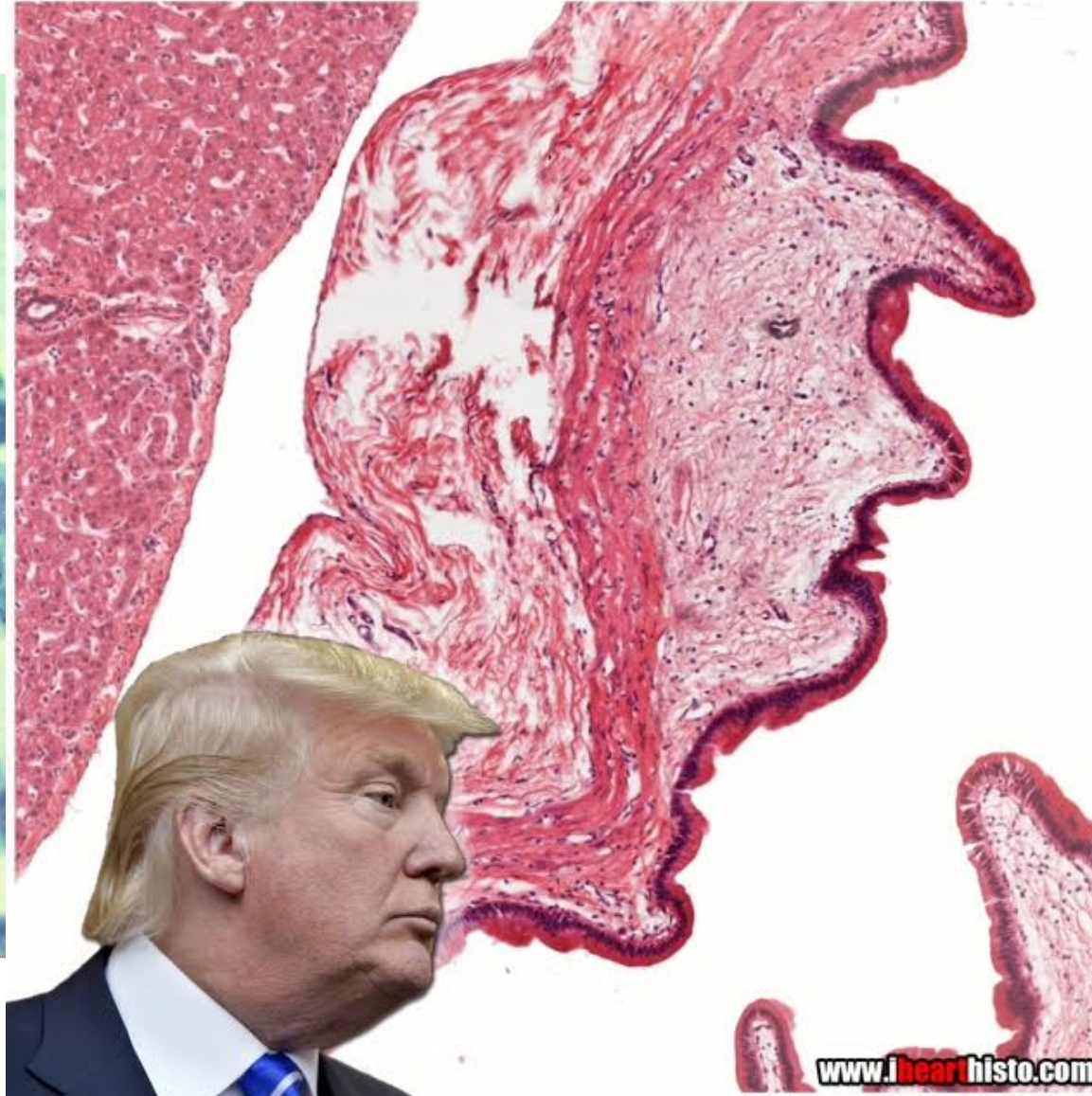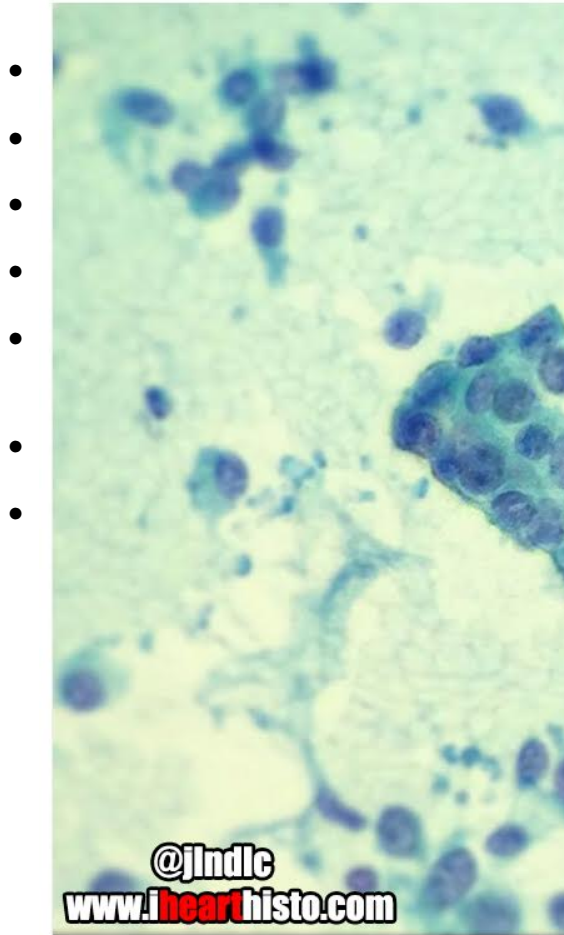
Sickle Cell Anemia

- Autosomal recessive inherited genetic disease resulting from homozygous point mutation (valine to glutamine at codon 6) of β globin gene
- **Etiology/Pathogenesis**
 - Abnormal hemoglobin (HbS) polymerizes under low oxygen tension, resulting in RBC sickling
 - RBC sickling and adhesion results in chronic anemia, microinfarcts, and painful vascular crisis
 - Heterozygous state provides protection against *Plasmodium falciparum* infection
- **Clinical Issues**
 - Ethnicity
 - African ancestry most common
 - Signs, symptoms, and natural history
 - Chronic anemia
 - Acute pain crises most commonly precipitated by infection, dehydration, high altitude
 - Diagnostic laboratory testing
 - Hemoglobin electrophoresis shows single band of HbS
 - Treatment
 - Hydroxyurea is standard
 - Stem cell transplantation considered using criteria related to donor availability and severity of disease
- **Microscopic**
 - Chronic normocytic normochromic anemia
 - Peripheral blood smear shows sickle cells during acute crisis
 - Howell-Jolly bodies indicate functional asplenism
- **Top Differential Diagnoses**
 - Hemoglobin S/ β -thalassemia
 - Hemoglobin SC disease
 - Microangiopathic hemolytic anemia

Take Home Points

- CBC and peripheral blood smear review are relatively inexpensive with a quick turnaround time
 - Can provide invaluable information
 - Can narrow differential diagnoses
 - Can identify subtle abnormalities that will reflex to additional diagnostic studies
- Can be reviewed with pathologist in real time
 - Slides are kept for 10 years

Good luck!



[s.ppt](#)