



TEXAS TECH UNIVERSITY  
HEALTH SCIENCES CENTER™  
EL PASO

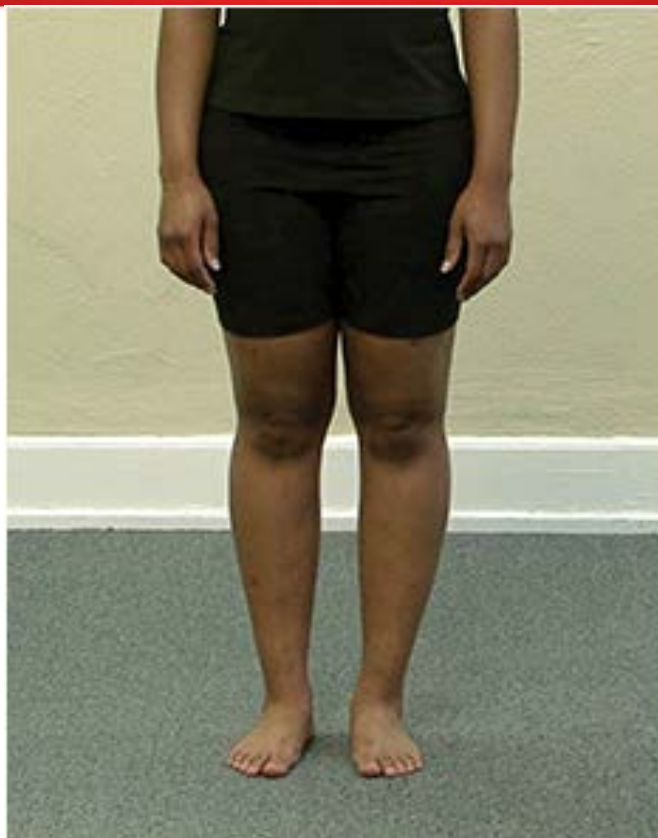

TEXAS TECH UNIVERSITY  
HEALTH SCIENCES CENTER™  
EL PASO

**KNEE**



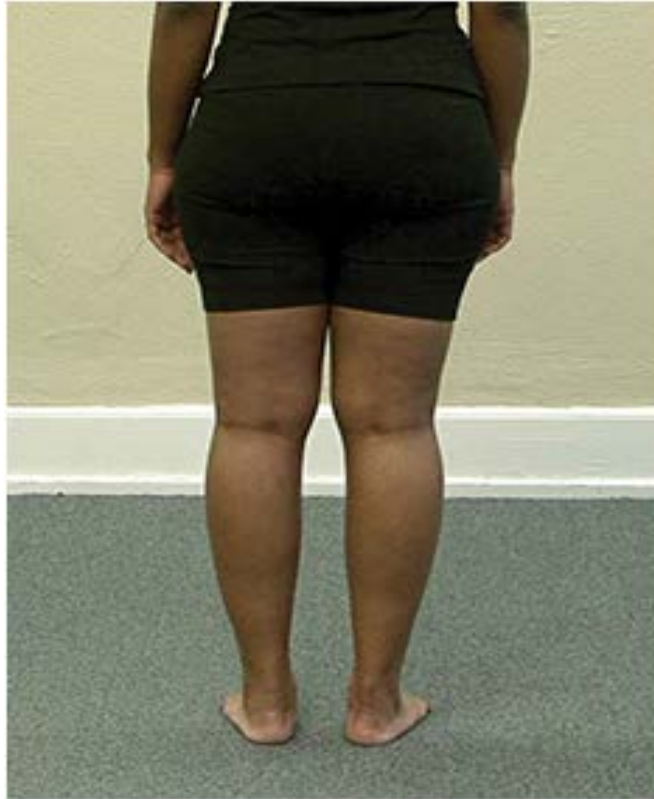## ANTERIOR VIEW



With the patient standing, inspect alignment and muscle symmetry, especially of the medial portion of the quadriceps muscles. Valgus malalignment is characterized by an ankle-to-ankle distance wider than the distance between the knees (knock knees). Conversely, varus malalignment is characterized by a knee-to-knee distance wider than the distance between the ankles. Persons with genu varum are referred to as being bowlegged. Internal femoral torsion, usually caused by the femoral neck leaning forward on the femoral shaft (femoral anteversion), aligns the knees with the patellae pointed inward when the feet are pointing straight ahead.



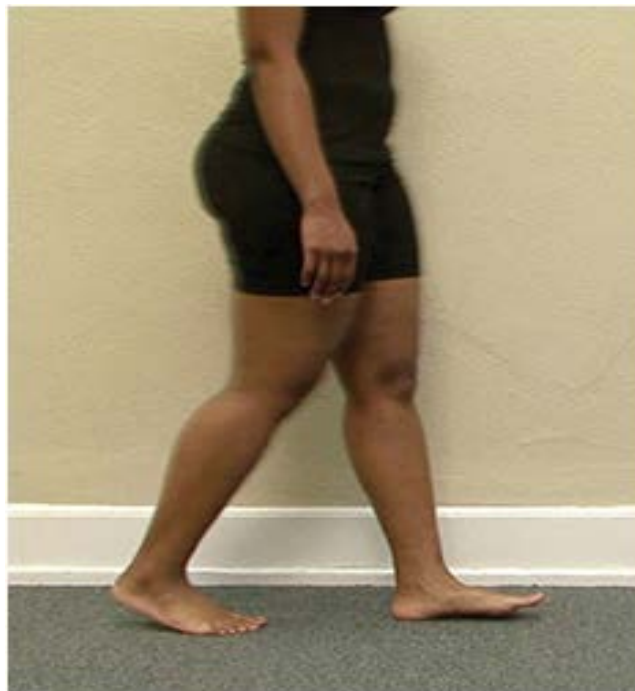**POSTERIOR VIEW**



With the patient standing, assess for asymmetry of the posterior thigh and calf musculature, including the hamstrings and calf muscles.



## GAIT

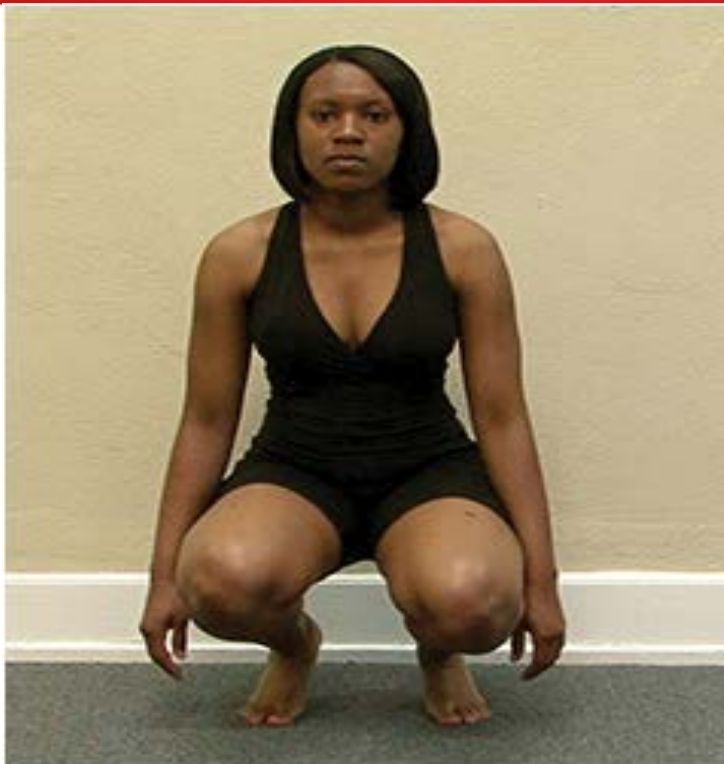

Watch the patient walk. Gait observation provides information on function and may be helpful in developing a differential diagnosis. With arthritic and other knee conditions that produce pain with weight bearing, the patient will limit motion and shorten the duration of weight bearing on the affected side (antalgic gait pattern).

Persons with primary hip pathology may demonstrate a Trendelenburg gait in which the patient leans over the affected leg to compensate for hip abductor weakness. Patients with insufficiency of the lateral knee ligamentous structures, either from trauma or severe medial compartment osteoarthritis, may walk with a varus thrust, which involves normal alignment when standing but in which the knee falls into varus malalignment when the foot strikes the ground during ambulation. Footdrop or inability to dorsiflex the ankle can indicate a peroneal nerve injury, which can be seen in association with an injury to the lateral collateral ligament.



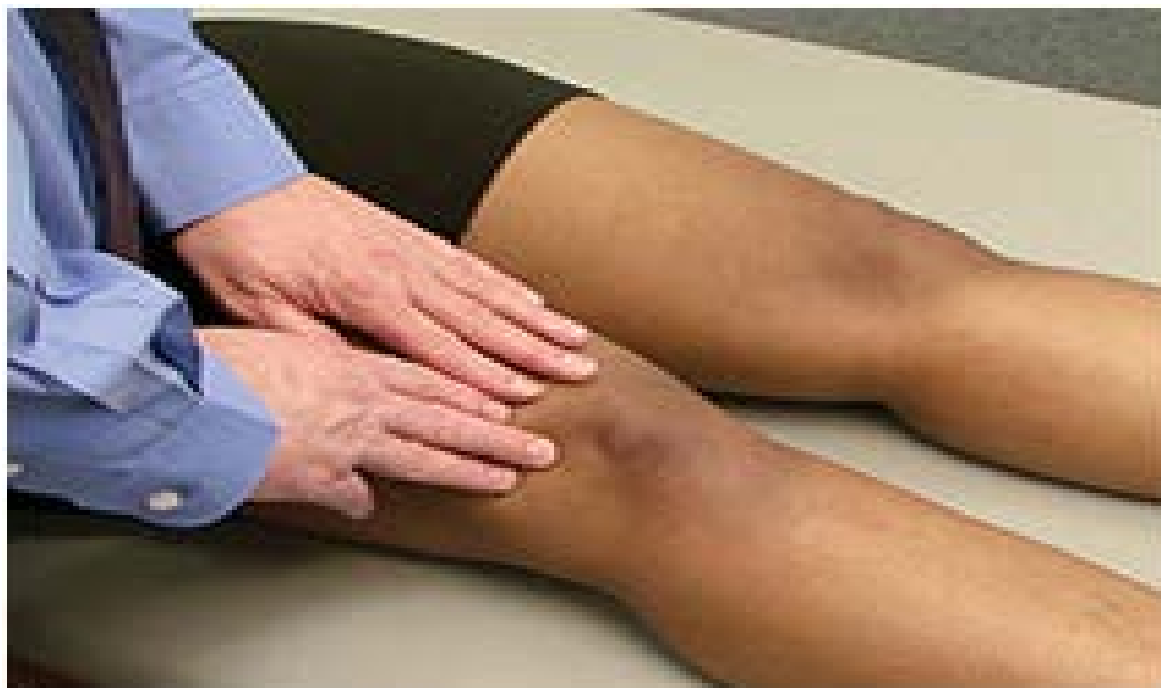## SQUAT



To assess knee flexion, ask the patient to squat. The patient should be able to flex both knees symmetrically. Pain with squatting may indicate meniscal injury or patellofemoral arthritis.



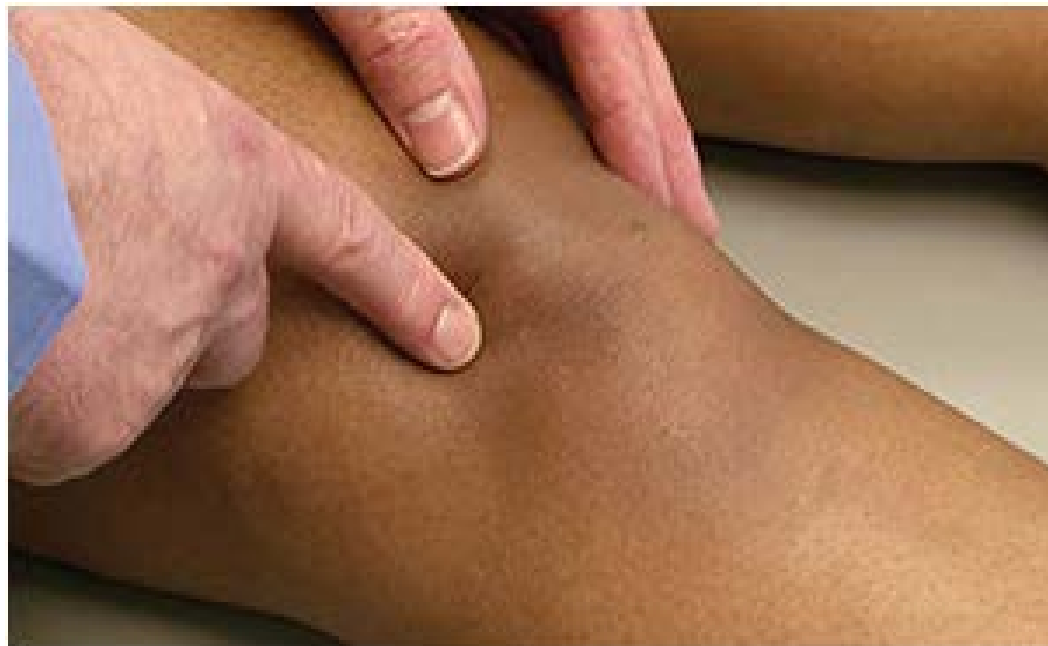## KNEE EFFUSION



To assess for the presence of an effusion, with the patient supine and the knee extended, inspect the suprapatellar region. If a large knee effusion is present, fullness of the suprapatellar region and loss of the normal dimpling on either side of the patella will be apparent. Subtle knee effusions can be demonstrated by “milking down” joint fluid from the suprapatellar pouch. To perform the milking maneuver, apply downward pressure to the patella with one hand while using the other hand to hold the fluid wave in place. Excess fluid will create a “spongy” feeling as the patella is pushed down.



## PATELLA



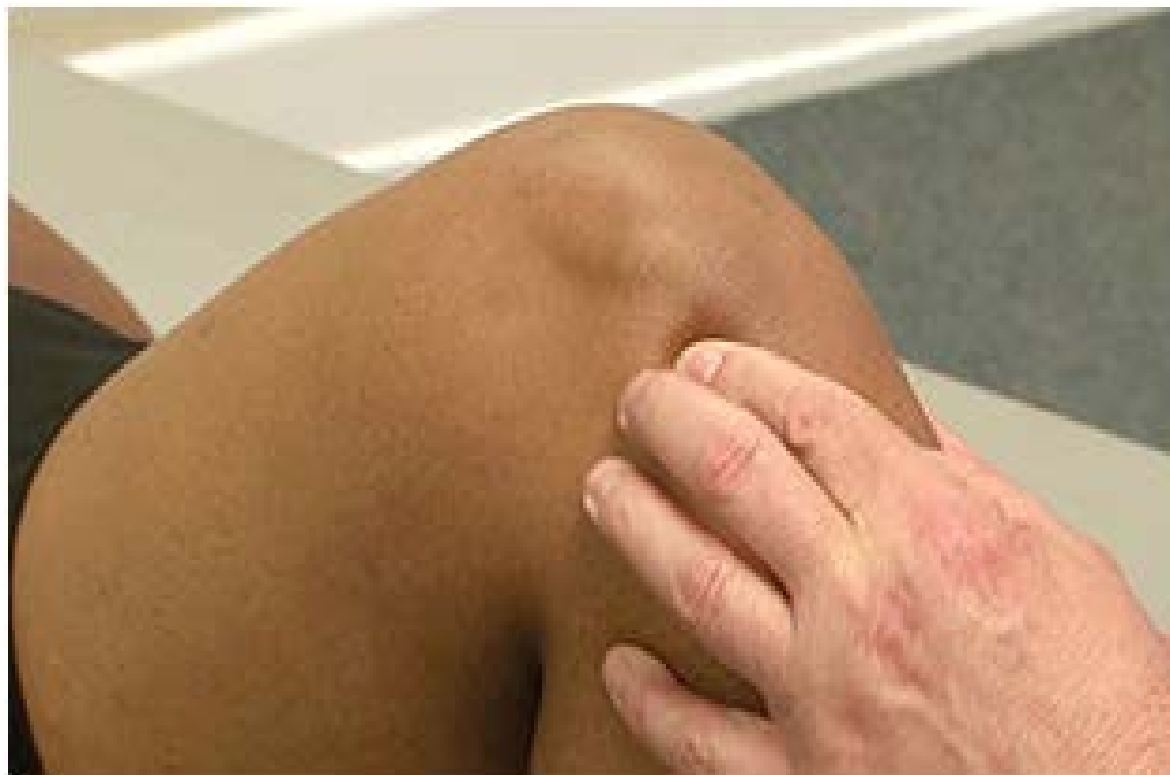To assess for pathology within the extensor mechanism, palpate the superior and inferior poles of the patella. Quadriceps and patellar tendinitis produce tenderness at the superior and inferior poles of the patella, respectively; complete rupture of these tendons creates a palpable defect at their respective locations. The defect becomes more prominent with increasing knee flexion and is associated with the patient's inability to actively straighten the knee.

Patellar tenderness can be elicited by placing the patient supine, ensuring relaxation of the extensor mechanism, and displacing the patella laterally and medially to allow palpation of the edges and undersurface of the patella. To perform a sensitive test for patellofemoral crepitus, place the patient supine with the hip flexed to 90°, and then place a hand on the patella as the knee is moved through a range of motion. A sensation of crepitus with this maneuver suggests articular cartilage damage within the patellofemoral joint.





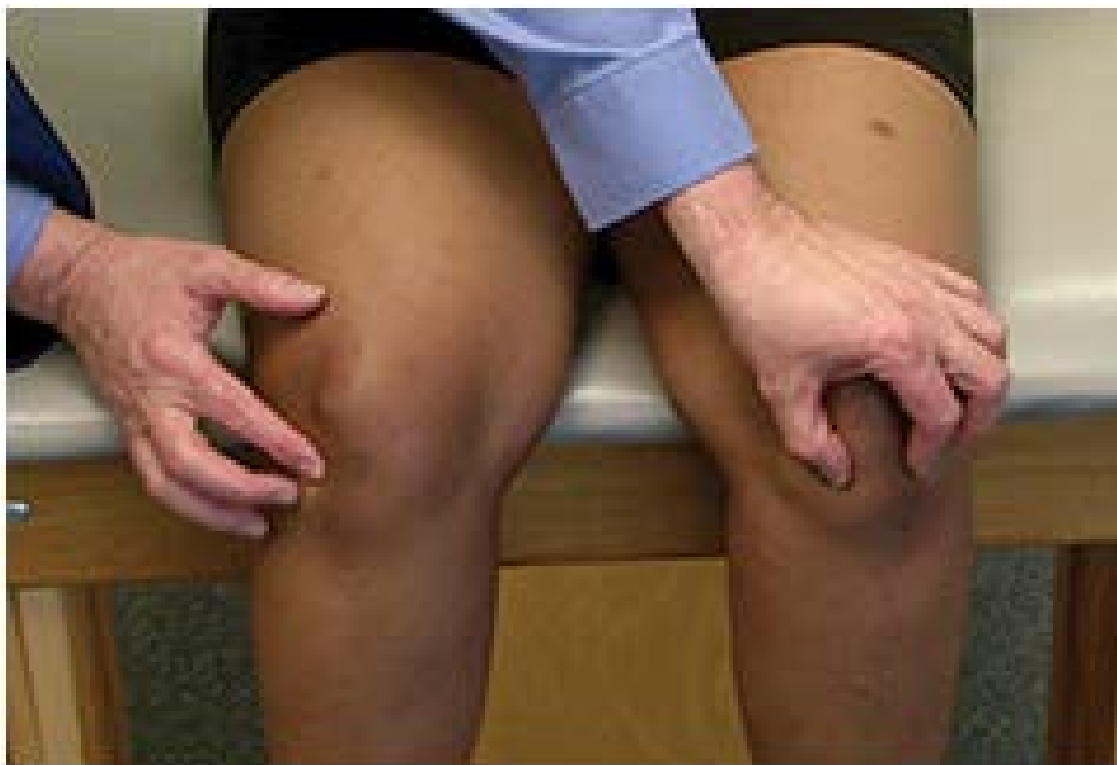## JOINT LINE TENDERNESS



Assess joint line tenderness with the patient supine and the knee flexed  $90^\circ$ . Identify the joint line within the soft spot between the femur and the tibia, then palpate the joint line along the entire joint margin on both the medial and lateral sides of the knee. An area of focal tenderness directly at the joint line supports the diagnosis of a torn meniscus. Joint line tenderness remains the most sensitive and specific physical examination test for the diagnosis of a meniscal tear.



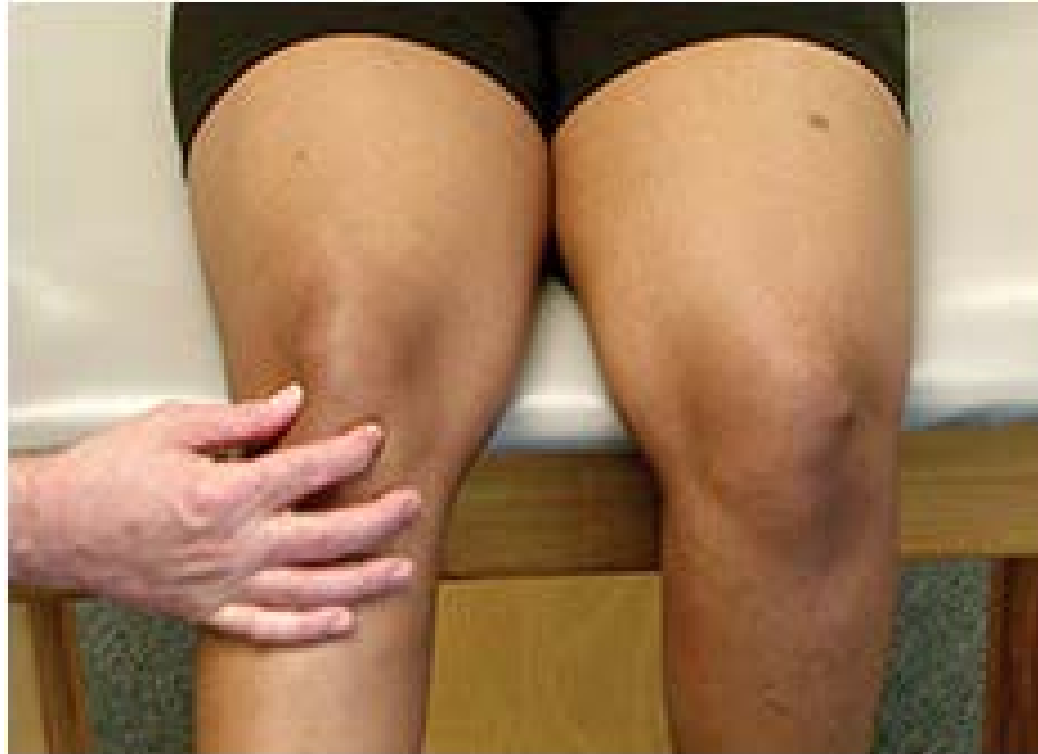## INFRAPATELLAR BURSA



The swollen infrapatellar bursa is usually visible as a dumbbell-shaped swelling on either side of the patellar tendon. In addition, the infrapatellar bursa can be palpated inferior to and on either side of the patella. Swelling of the infrapatellar bursa associated with erythema is concerning for a septic bursitis.



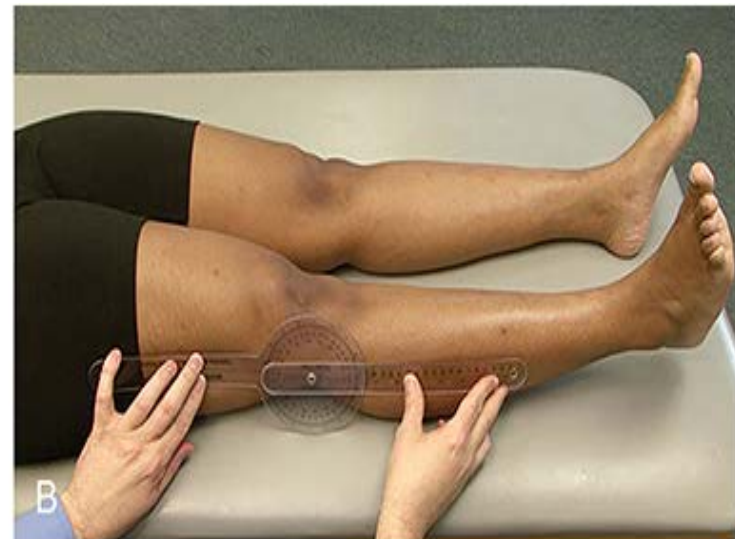
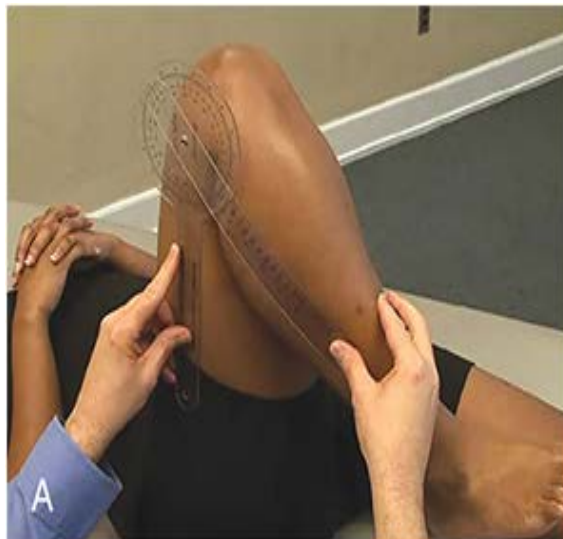## PATELLA TRACKING



To assess patellar tracking within the trochlea, place one hand on the patella and palpate the patella while the patient flexes and extends the knee. As the knee moves from extension to flexion, the patella normally moves in a gentle arc from a relatively lateral position when the knee is extended to a more central position during early flexion, and then back to a relatively lateral position as flexion continues. With patellar instability, this arc of movement is exaggerated and may make an inverted J-shaped motion (the “J sign”), a sudden lateral movement of the patella as the knee nears full extension.



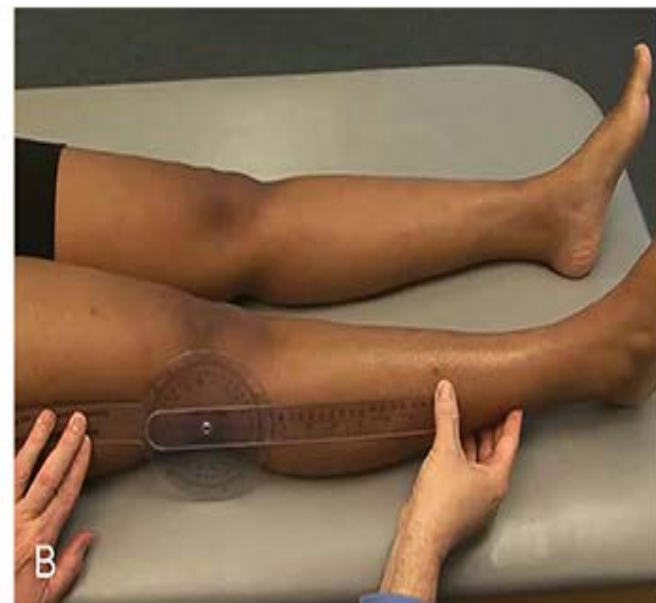
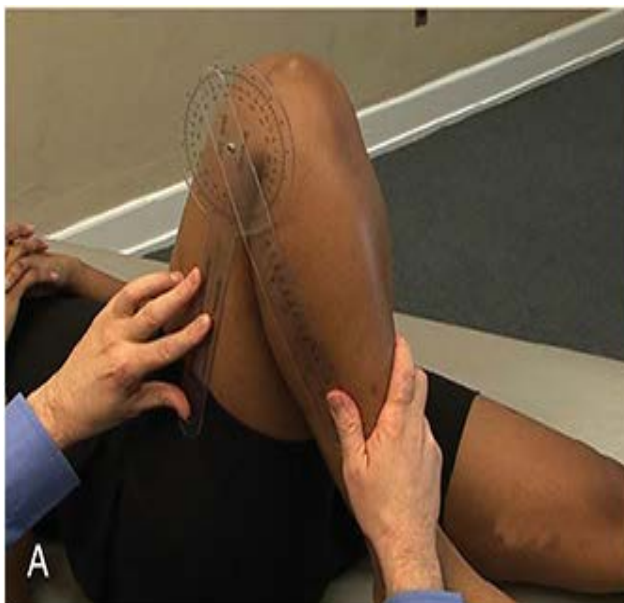## ACTIVE RANGE OF MOTION



Active flexion may be measured with a goniometer while the patient squats, using the straight knee as the starting position, or, more traditionally, with the patient supine (A). Extension (B) or hyperextension is motion opposite to flexion, which is measured relative to full extension and compared with the contralateral knee.



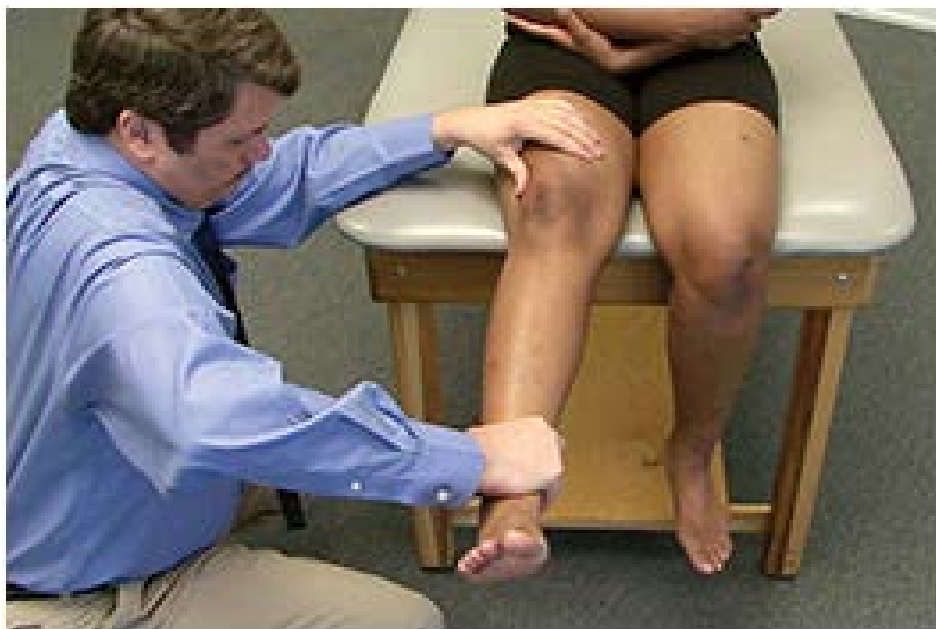## PASSIVE RANGE OF MOTION



Using a goniometer, obtain measurements of passive knee flexion (A) and extension (B) with the patient supine or prone and with the examiner's hands placed on the ankle and knee to flex and extend the patient's knee. Passive extension can also be measured with the patient supine and the heel resting on a support that elevates the leg 5 cm above the examination table.



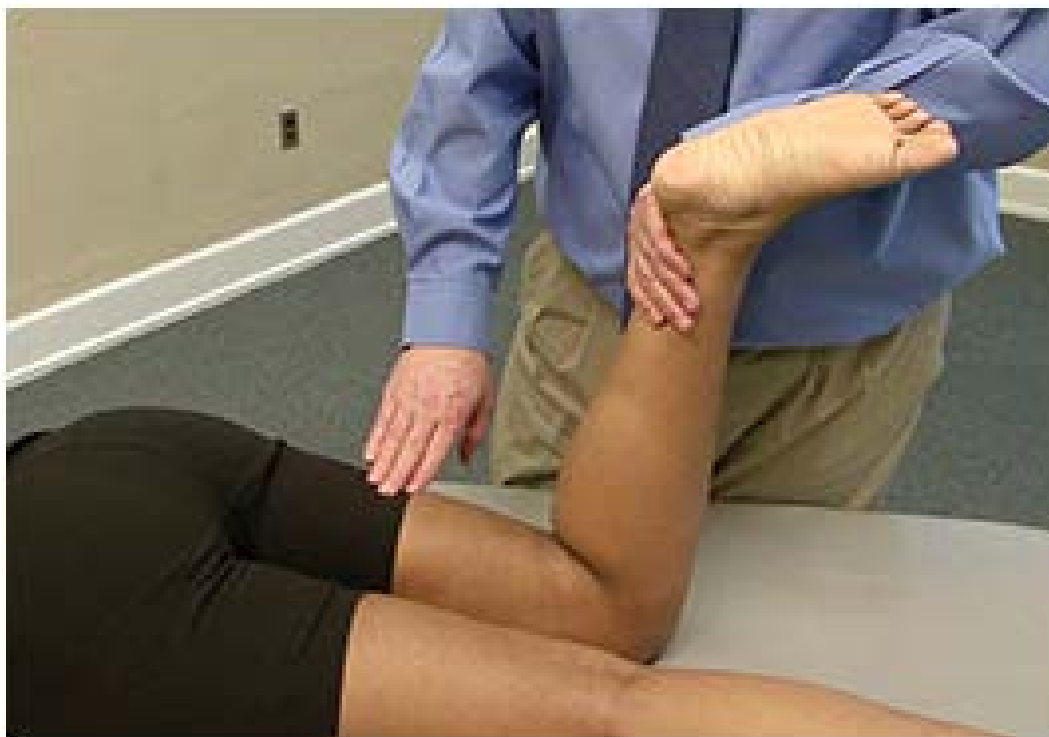## QUADRICEPS



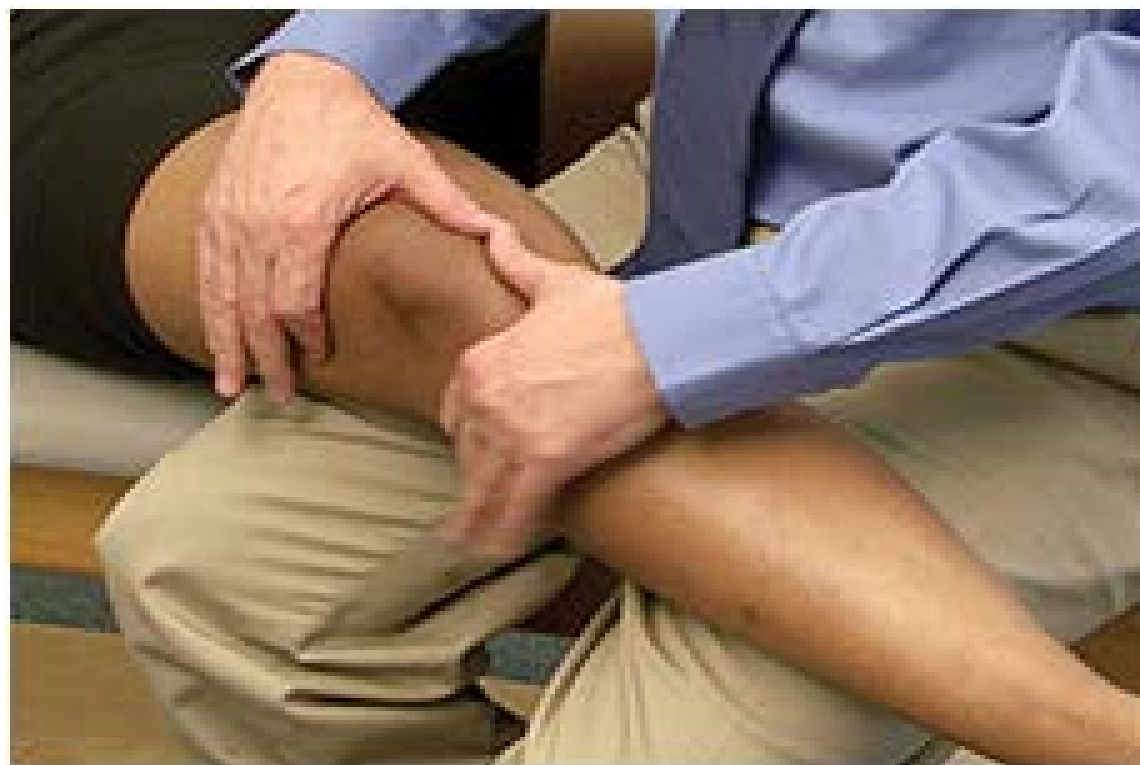Assess quadriceps muscle strength by asking the seated patient to extend the knee. Apply resistance by pushing down on the tibia after the knee is fully extended.



## HAMSTRING



Hamstring strength testing is best measured with the patient placed prone. Place the knee in approximately 90° of flexion, and then ask the patient to flex the knee against resistance applied to the distal tibia.



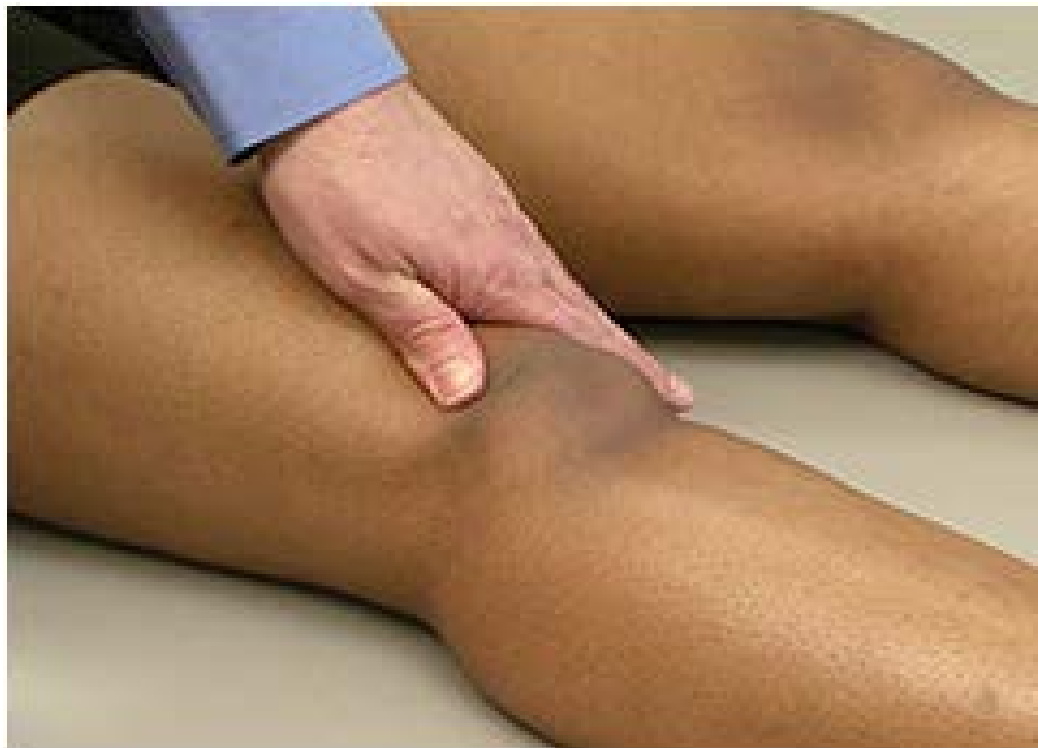## PATELLAR APPREHENSION TEST

Assess patellar instability with the patient supine and the knee relaxed in approximately 30° of flexion and draped across your thigh. Using your thumbs, apply gentle, laterally directed pressure to displace the patella laterally. Normally, the patella eventually reaches a firm end point laterally after being displaced. In cases of patellar instability, often you will appreciate the absence of a firm end point. Furthermore, the patient often anticipates or perceives pain associated with patellar subluxation over the lateral trochlear ridge, becomes apprehensive, and contracts the quadriceps muscle to avoid further lateral displacement of the patella (apprehension sign).





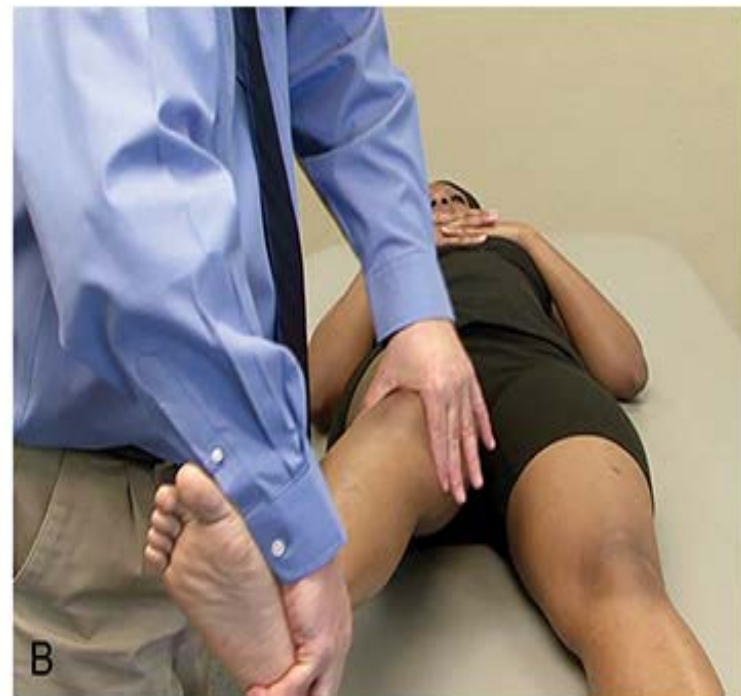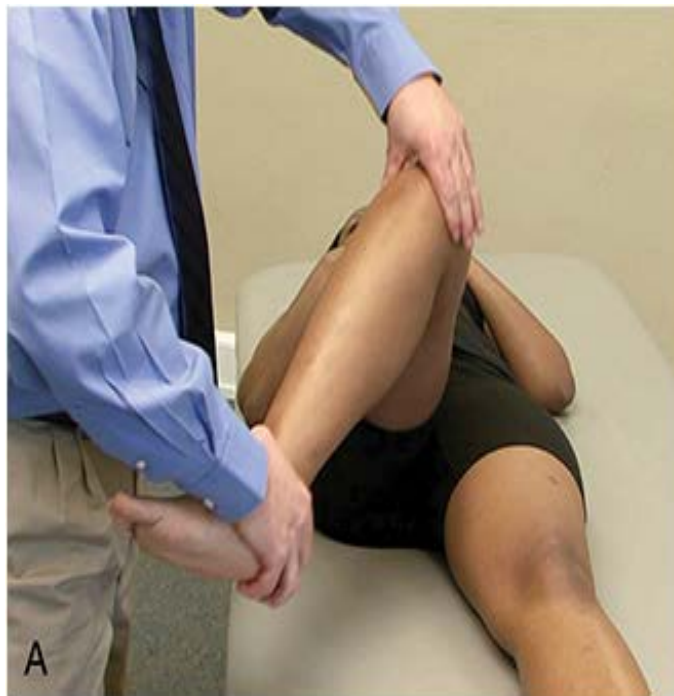## PATELLAR GRIND TEST (CLARKE SIGN)



Assess for cartilage degeneration on the undersurface of the patella with the patient supine, the knee extended, and the quadriceps muscle relaxed. Place one hand superior to the patella and push the patella inferiorly. Ask the patient to tighten the quadriceps muscle against this patellar resistance. A grinding sound and/or pain may indicate patellofemoral chondromalacia. However, this test is often positive for grinding and/or pain in patients with normal knees.



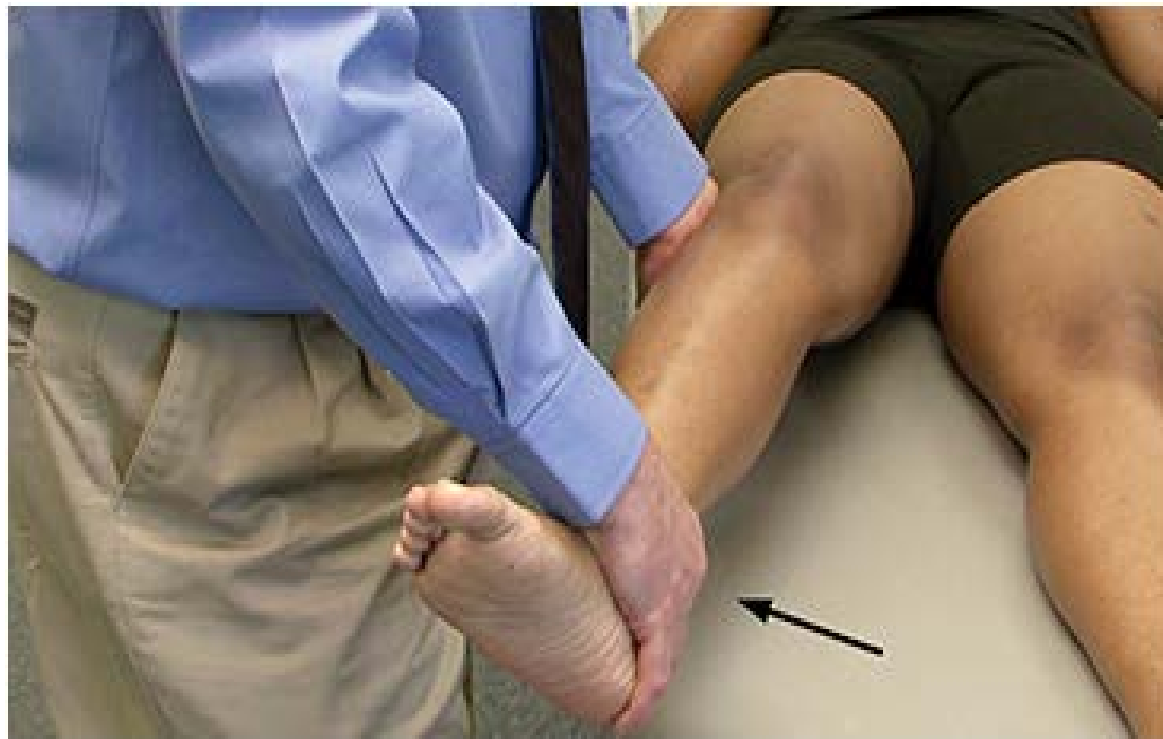## McMURRAY TEST



The McMurray test is used to evaluate the knee menisci. With the patient supine, flex the knee to the maximum pain-free position (A). Hold the leg in that position while externally rotating the foot and then gradually extend the knee while maintaining the tibia in external rotation (B). This maneuver stresses the medial meniscus and often elicits a localized medial compartment click and/or pain in patients with a tear of the posterior horn of the medial meniscus. The same maneuver performed while rotating the foot internally stresses the lateral meniscus. To be useful, this test requires pain-free flexion beyond 90°.



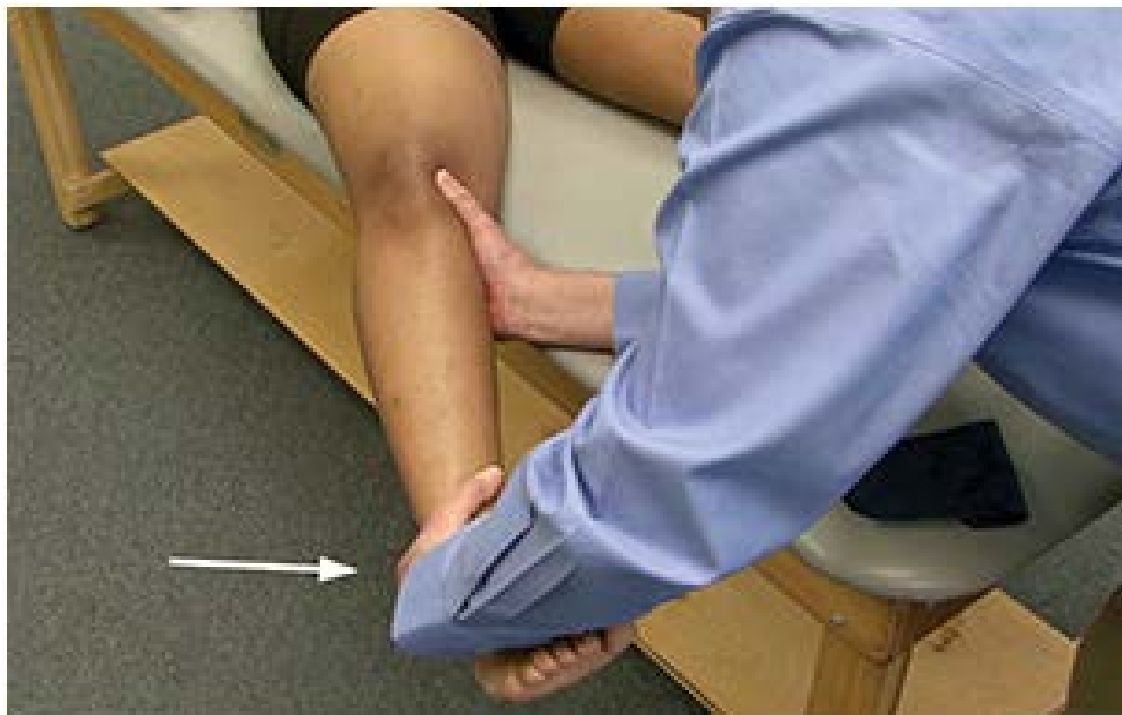## VALGUS STRESS TEST



Assess medial collateral ligament stability by applying valgus stress to both knees, once with the knee extended and once with the knee in  $30^\circ$  of flexion. With the patient supine and the thigh supported to relax the quadriceps, place one hand on the lateral side of the knee, grasp the medial distal tibia with the other hand, and abduct the knee (arrow). If the affected knee exhibits increased medial joint space opening under a valgus stress and with the knee flexed to  $30^\circ$ , an isolated injury of the medial collateral ligament likely exists. The additional finding of medial laxity with valgus stress in full extension indicates a more severe injury that involves not only the medial collateral ligament, but also likely the posterior cruciate ligament and/or other posteromedial structures of the knee.



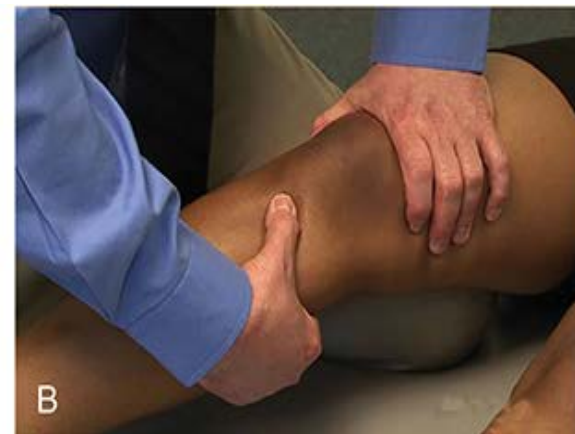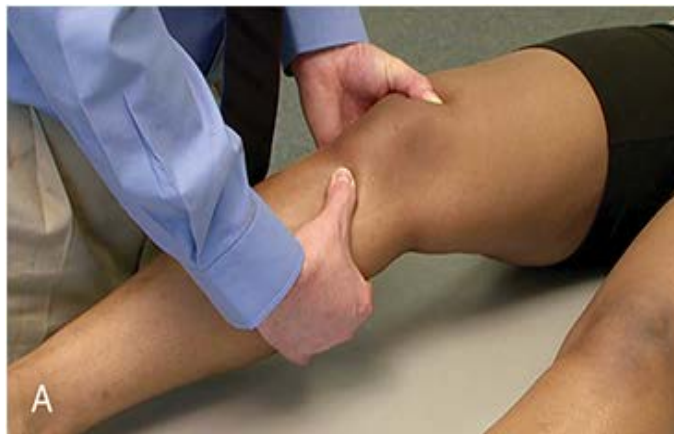## VARUS STRESS TEST



Assess the integrity of the lateral collateral ligament by applying varus stress with the knee in extension and in 30° of flexion and comparing the degree of lateral opening with that of the opposite knee. Many patients, especially those with global hyperlaxity, have physiologic varus laxity. With the patient supine, place one hand on the medial side of the knee, grasp the lateral distal tibia with the other hand, and adduct the knee (arrow). At 30° of knee flexion, if the affected knee has increased excursion compared with the opposite knee in a varus direction, the patient likely has an injury involving only the lateral collateral ligament. If the knee also exhibits asymmetric varus laxity in full extension, the patient has an injury involving the entire posterolateral corner, including but not limited to the lateral collateral ligament, popliteus tendon, and popliteofibular ligament.



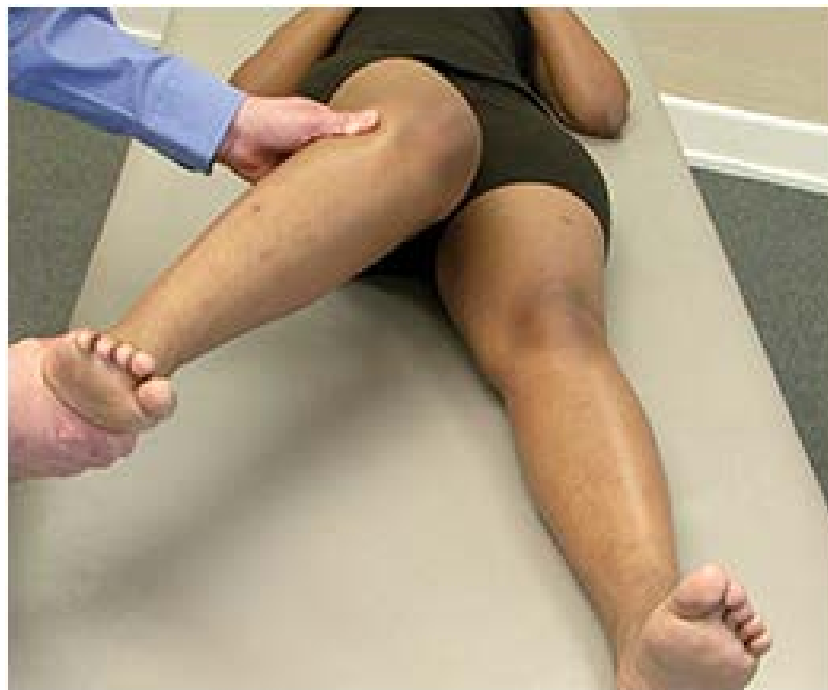## LACHMAN TEST



The Lachman test is used to assess the ability of the anterior cruciate ligament to resist anterior translation of the tibia relative to the femur. With the patient supine, the thigh supported, and the thigh muscles relaxed, flex the patient's knee to 30° and then, after you stabilize the distal femur from the lateral side of the knee with one hand, with your other hand grasp the proximal tibia from the medial side and translate it directly anteriorly (A). Alternatively, in the cases of larger patients, you may rest the patient's thigh on your flexed knee on the examination table (B). Keep the knee in neutral rotation, then lift the proximal tibia anteriorly while stabilizing the femur. Focus on the amount of bony translation of the tibia relative to the femur and on the presence or absence of a firm end point on reaching full anterior translation. Increased anterior tibial translation and/or the absence of a firm end point suggests a tear of the anterior cruciate ligament. The Lachman test is the best maneuver for assessing the integrity of the anterior cruciate ligament.



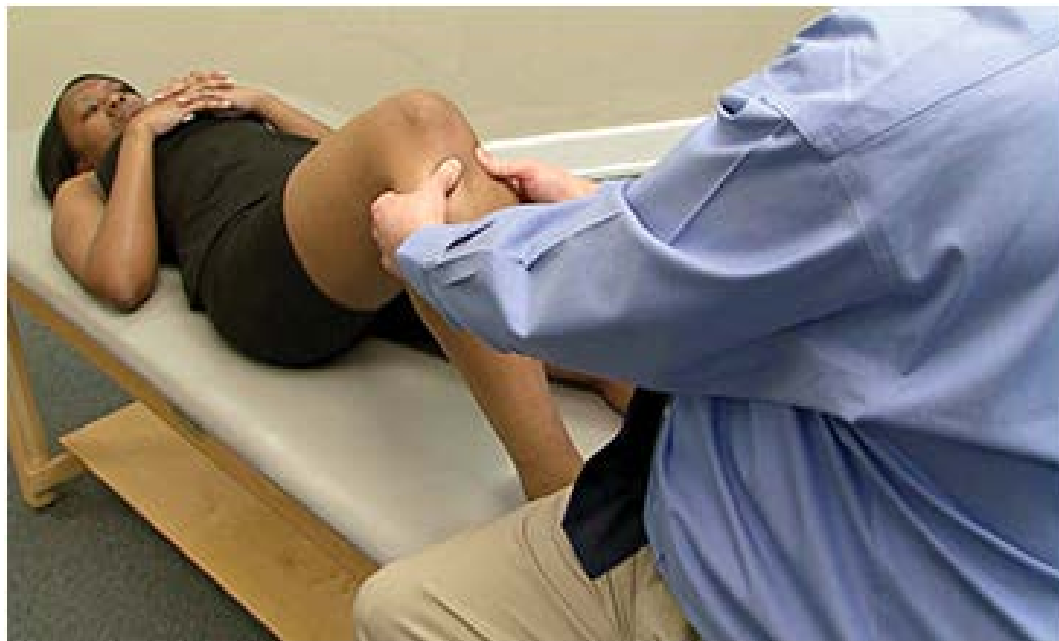## PIVOT SHIFT TEST



The pivot shift test is used to assess the integrity of the rotatory function of the anterior cruciate ligament. With the patient supine, place the knee in full extension and then slowly flex the knee while applying a simultaneous valgus stress and internal rotation stress. Conversely, the pivot shift can also be elicited by holding the leg in external rotation and flexion, applying a valgus force throughout the range of motion, and slowly extending the knee. In both cases, anterior subluxation of the lateral femoral condyle greater than that of the medial femoral condyle occurs between 20° and 40° of knee flexion.



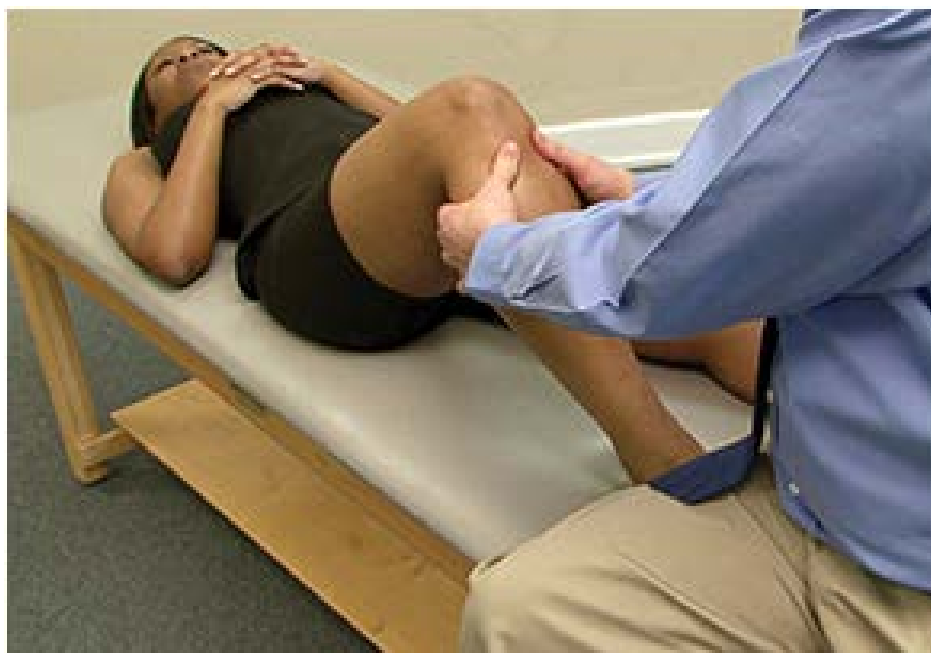## ANTERIOR DRAWER TEST



The anterior drawer test is done to determine the ability of the anterior cruciate ligament to provide sagittal stability when damage to secondary restraints exists. The anterior drawer test differs from the Lachman test only in the degree of knee flexion in which the test is performed. Although the anterior drawer test is easier to perform than the Lachman test, it lacks the sensitivity of the Lachman test. The anterior drawer test is performed with the patient supine and the knee flexed to 90° and in neutral rotation. Stabilize the leg by sitting on the patient's foot and palpating the hamstring tendons to ensure that the secondary restraints to anterior tibial translation are relaxed. Grasp the proximal tibia with both hands and thrust the tibia anteriorly. Compare the results with the unaffected knee, which should always be examined first.



## POSTERIOR DRAWER TEST

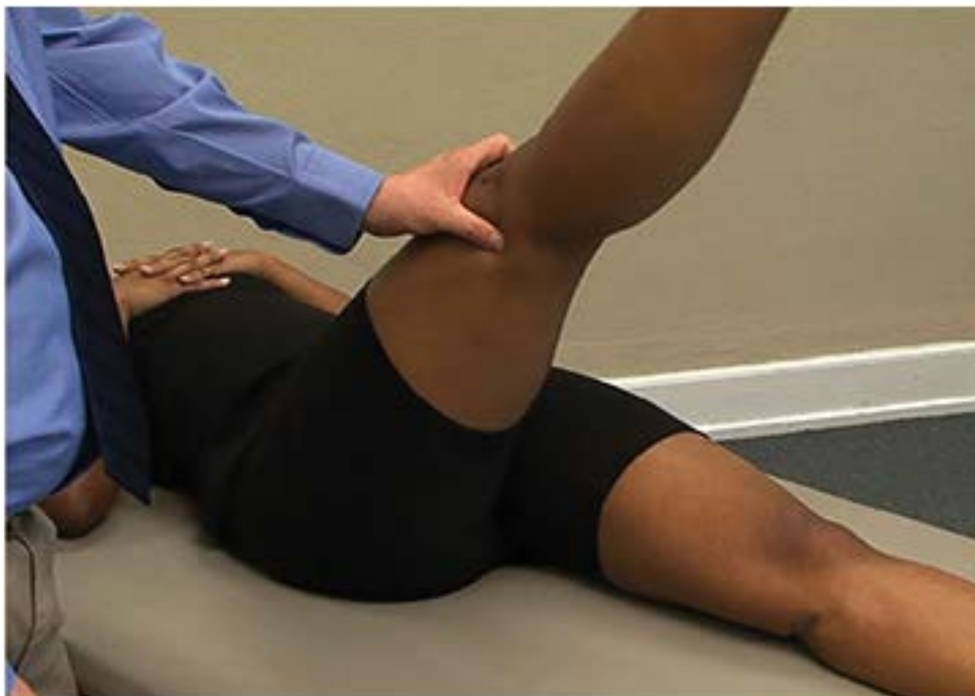


The posterior drawer test assesses the function of the posterior cruciate ligament as a restraint to posterior tibial translation. With the patient supine and the foot supported on the table, flex the knee to 90°. Grasp the proximal tibia with both hands and place your thumbs on the top of the medial and lateral tibial plateaus. In the normal knee, the anterior tibial plateaus are located 10 mm anterior to the femoral condyles at rest. Push the tibia posteriorly; translation of the tibial plateaus to be flush with the femoral condyles indicates at least 10 mm of posterior laxity. This amount of posterior tibial translation is consistent with a complete tear of the posterior cruciate ligament. In many cases of posterior cruciate ligament injury, a positive posterior drawer test may not be apparent because the tibia rests at a level equal to or posterior to that of the femoral condyles (the gravity sag sign). In this instance, no further posterior displacement may be noted when pushing the tibia posteriorly, but the anterior drawer test may exhibit a false-positive response because of the anterior force used to reduce the knee to a normal position.





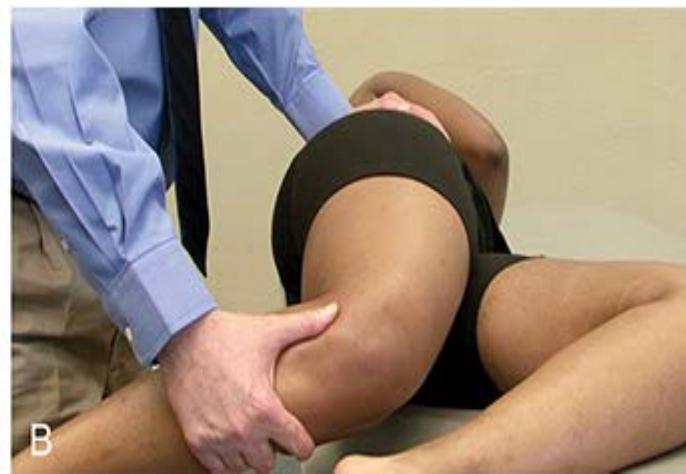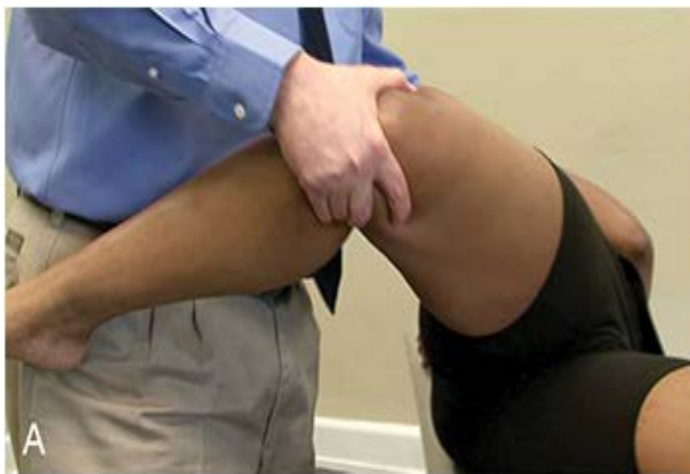## NOBLE TEST



The Noble test assesses for the presence of iliotibial band friction syndrome. With the patient supine and the knee flexed to 90°, apply pressure with your thumb to the iliotibial band over the lateral femoral condyle and then extend the knee. Tenderness elicited between 30° and 40° of knee flexion is a positive sign.



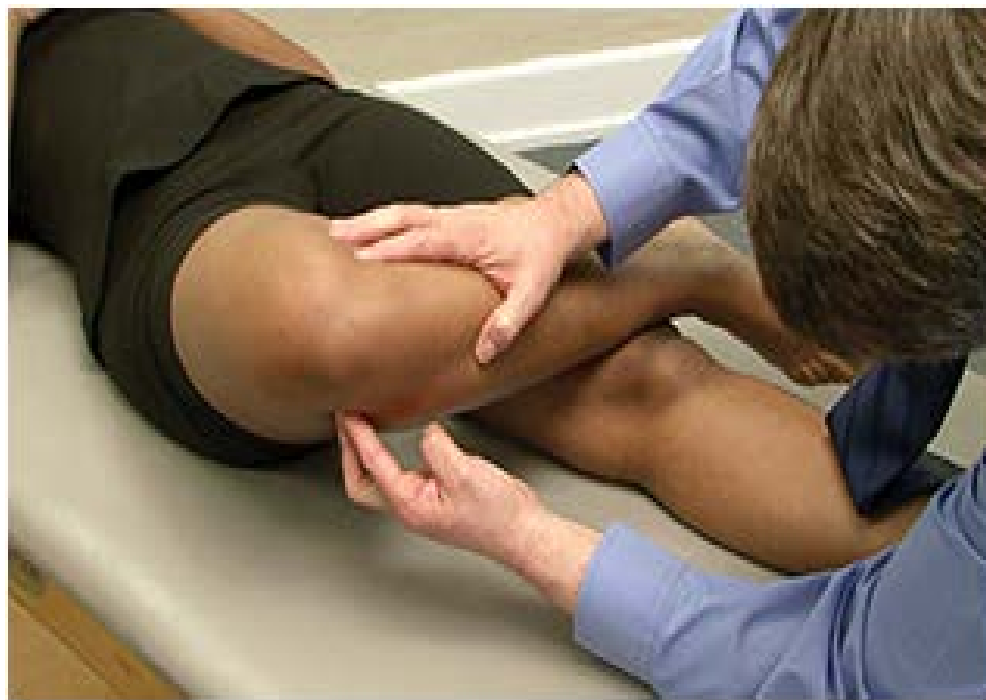## OBER TEST



The Ober test can be used to determine the degree of tightness in the tensor fascia lata and iliotibial band. Position the patient lying on the unaffected side with the unaffected knee and hip flexed. Flex the affected knee to 90° and abduct and extend the ipsilateral hip while stabilizing the pelvis (A). Then slowly lower the affected thigh as far as possible (B). Inability of the extremity to drop below horizontal to the level of the table indicates tightness in the tensor fascia lata and iliotibial band. This tightness may contribute to patellofemoral pain or iliotibial band syndrome.



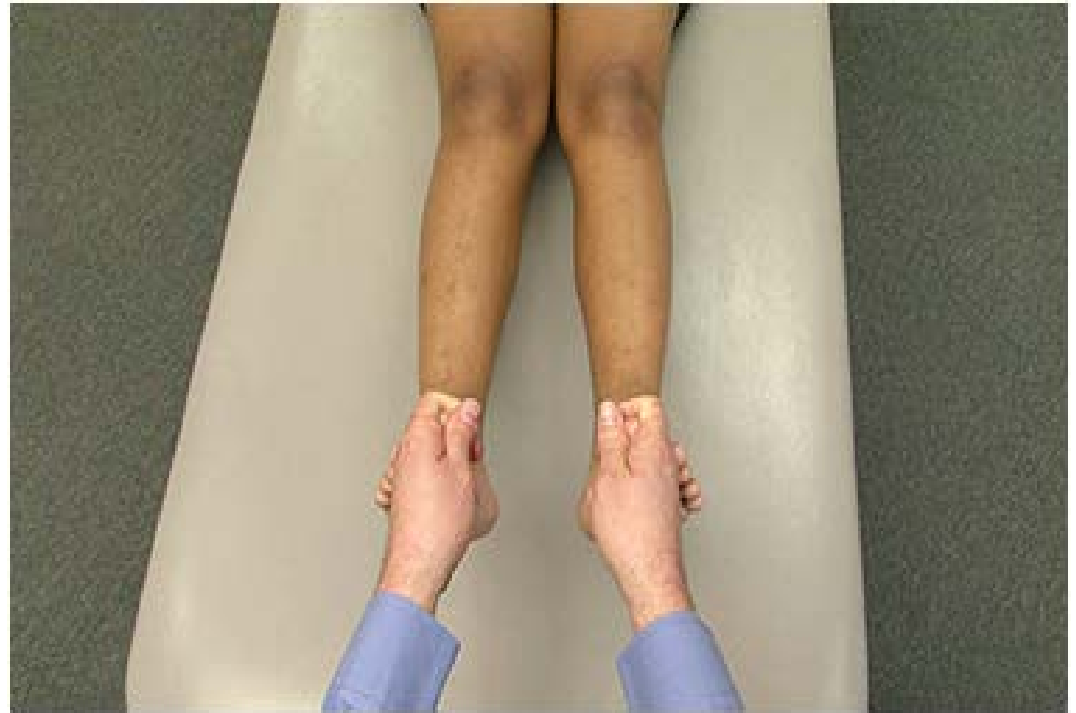## FIBULAR COLLATERAL LIGAMENT PALPATION



With the knee in the figure-of-4 position, the fibular collateral ligament can be palpated to evaluate its integrity. With the patient supine, flex the affected knee and place the ipsilateral hip in flexion, abduction, and external rotation with the patient's foot placed on the opposite knee (the figure-of-4 position). Palpate the fibular collateral ligament directly in line with the fibula and lateral epicondyle. An intact fibular collateral ligament should be readily palpable in this position; the absence of a cordlike structure may indicate a loss of integrity of the ligament.



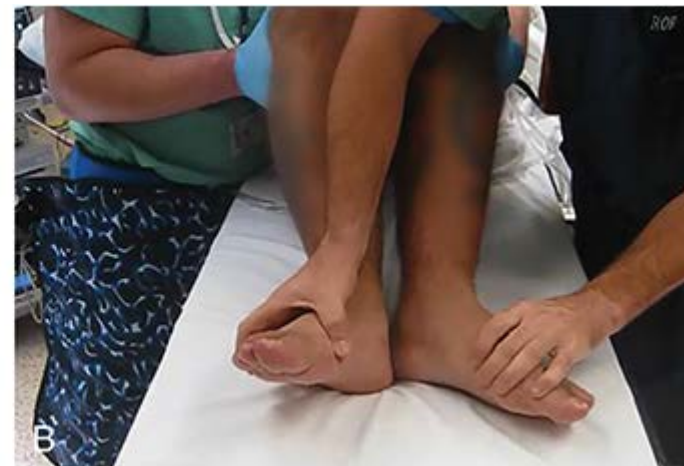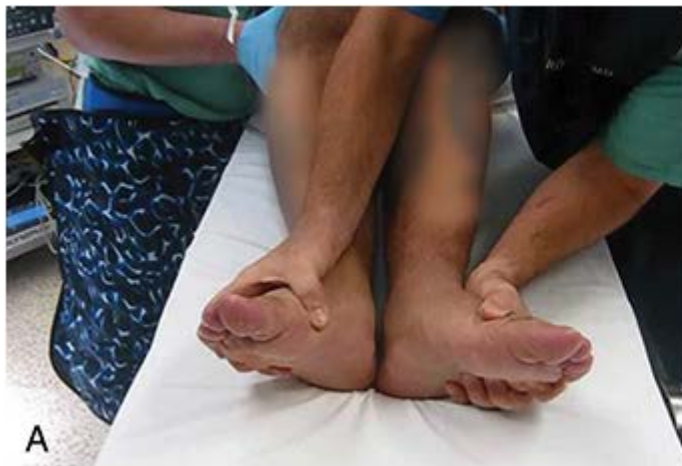## EXTERNAL ROTATION RECURVATUM TEST



Injuries to the posterolateral corner of the knee can be demonstrated by performing the external rotation recurvatum test. With the patient supine, grasp the great toe of both feet and lift up slightly so that the knees elevate off the table. Asymmetric recurvatum (hyperextension), varus, and knee external rotation greater than  $10^{\circ}$  compared with that of the opposite limb suggests substantial injury to the posterolateral structures of the knee.



## DIAL TEST



The Dial test is another test used to determine injury to the posterolateral structures of the knee. The test can be performed with the patient supine or prone. With the patient's hips and thighs in neutral rotation, grasp the heels and flex the knees to 30° (the thighs should remain on the table) (A). Apply an external rotation force to each leg. A difference in external rotation between legs of greater than 10° indicates an injury to the posterolateral structures of the knee. Repeat the test with the knees flexed to 90° (B). Increased external rotation at 90° suggests a combined posterolateral corner and posterior cruciate ligament injury. If the Dial test is positive only at 30°, an isolated injury to the posterolateral corner structures is likely.