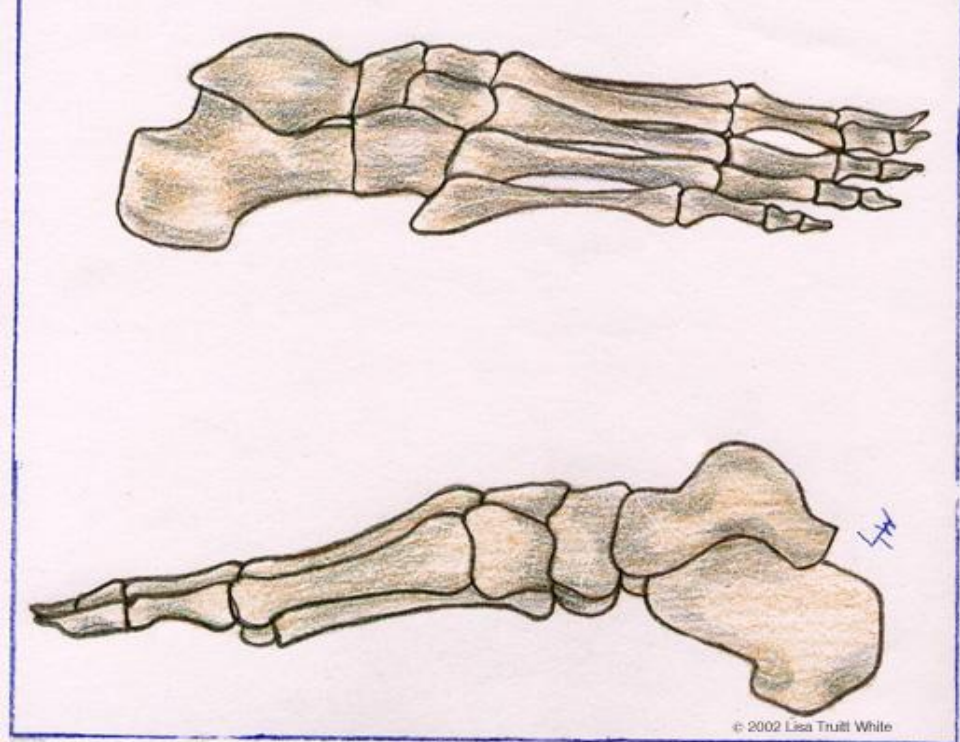
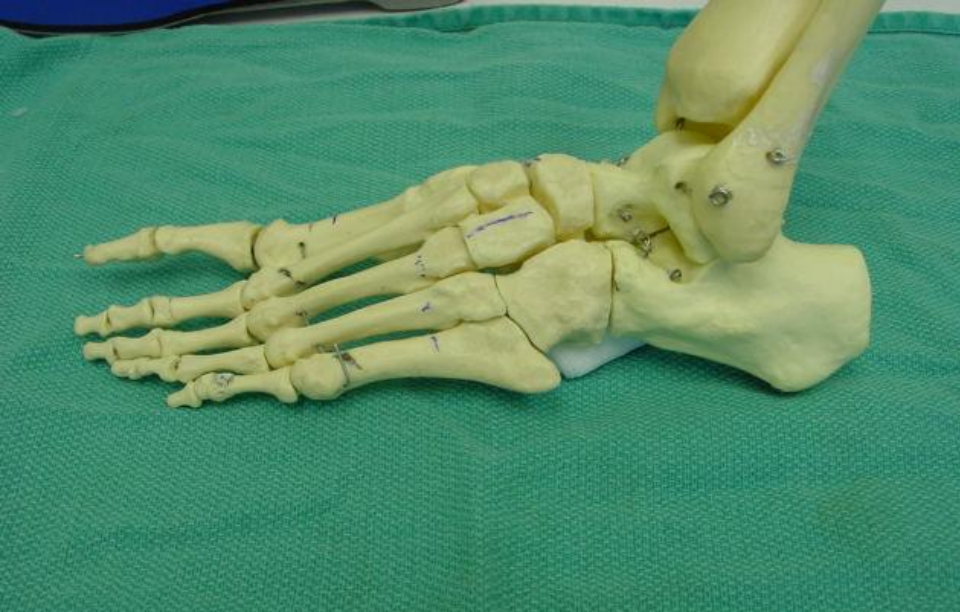

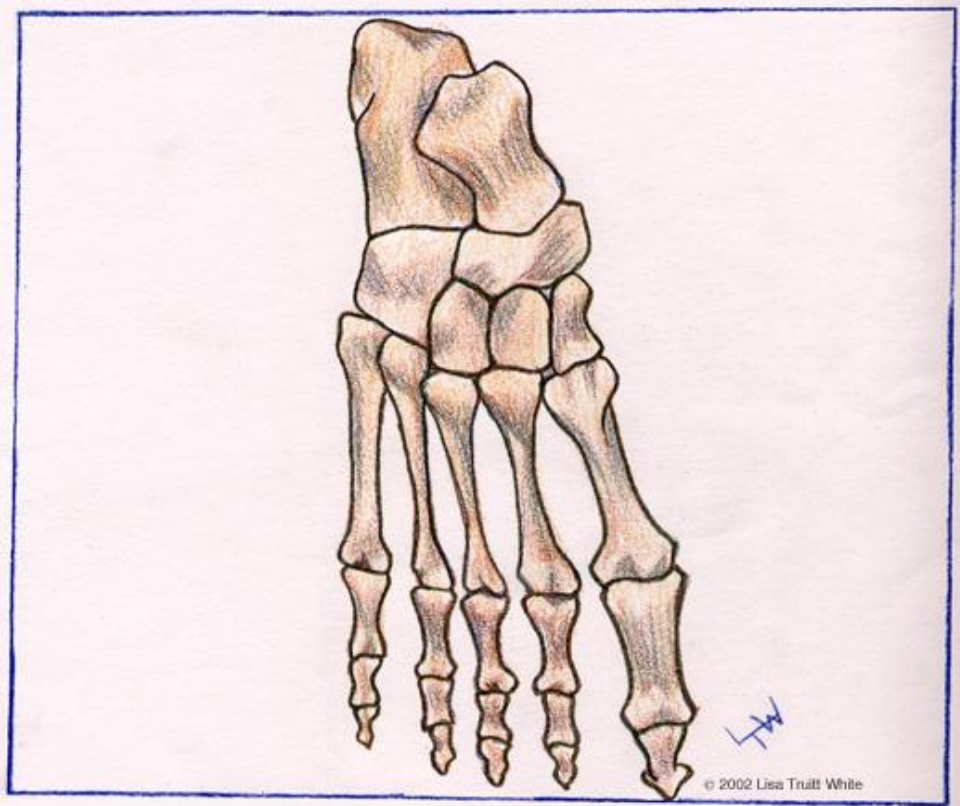
Common Foot & Ankle Problems

Created by Dr. Willard J. Niemi, FACFAS

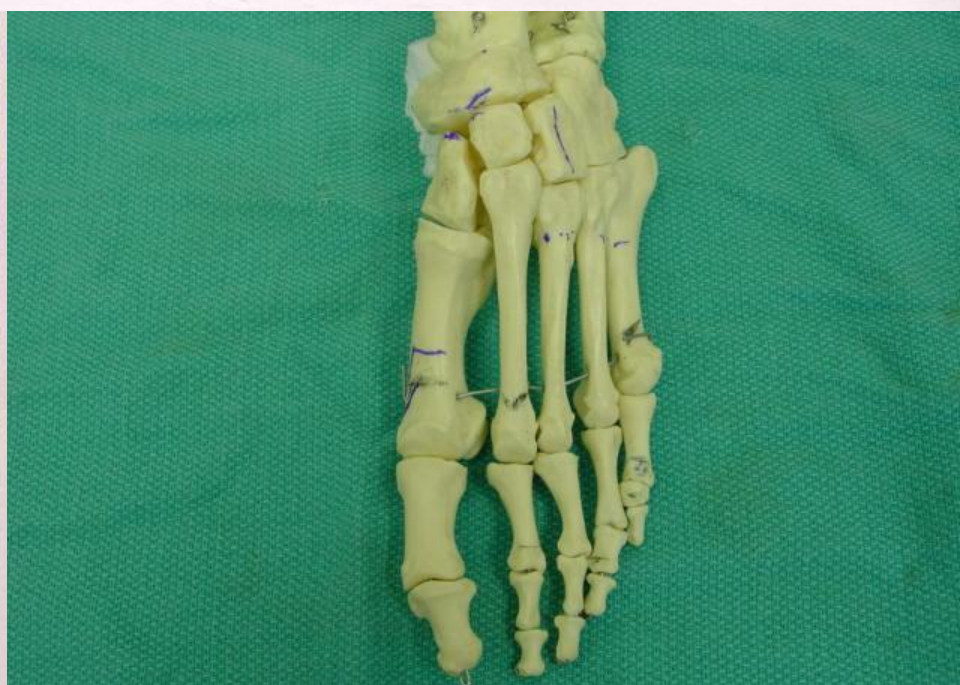Dr. John LoPiccolo, AACFAS



© 2002 Lisa Trull White



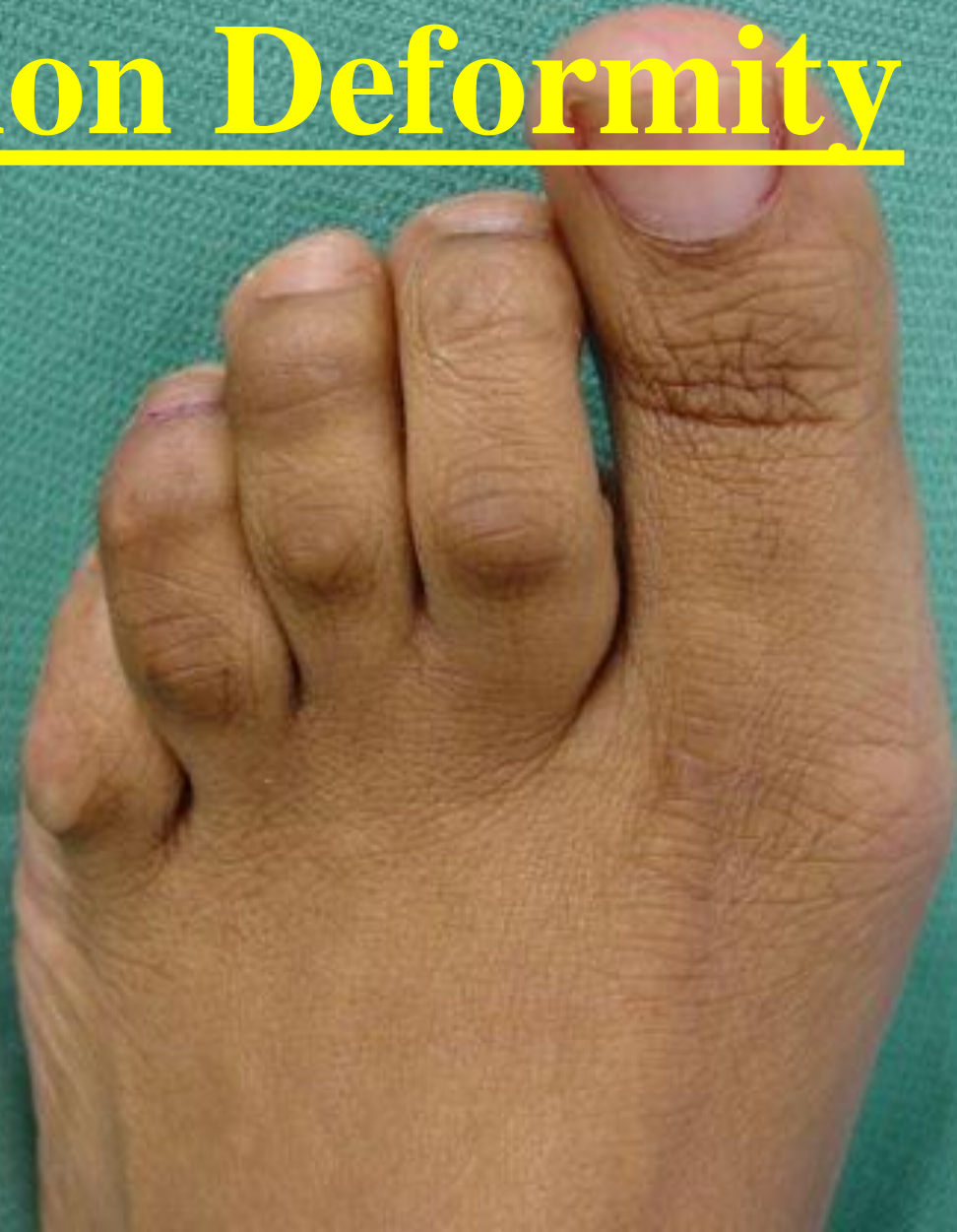
© 2002 Lisa Trull White



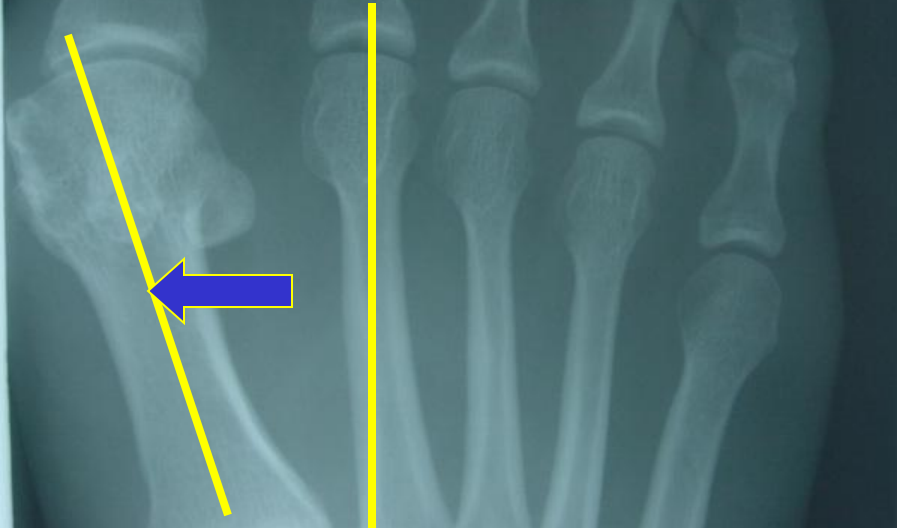
Hallux Valgus / Bunion Deformity

- A structural (bony) deformity where the metatarsal bones spread apart causing a prominent bone to protrude on the inside of the foot.
- A progressive deformity.
- May be treated conservatively, but usually requires surgical correction if pain persists.

Hallux Valgus / Bunion Deformity

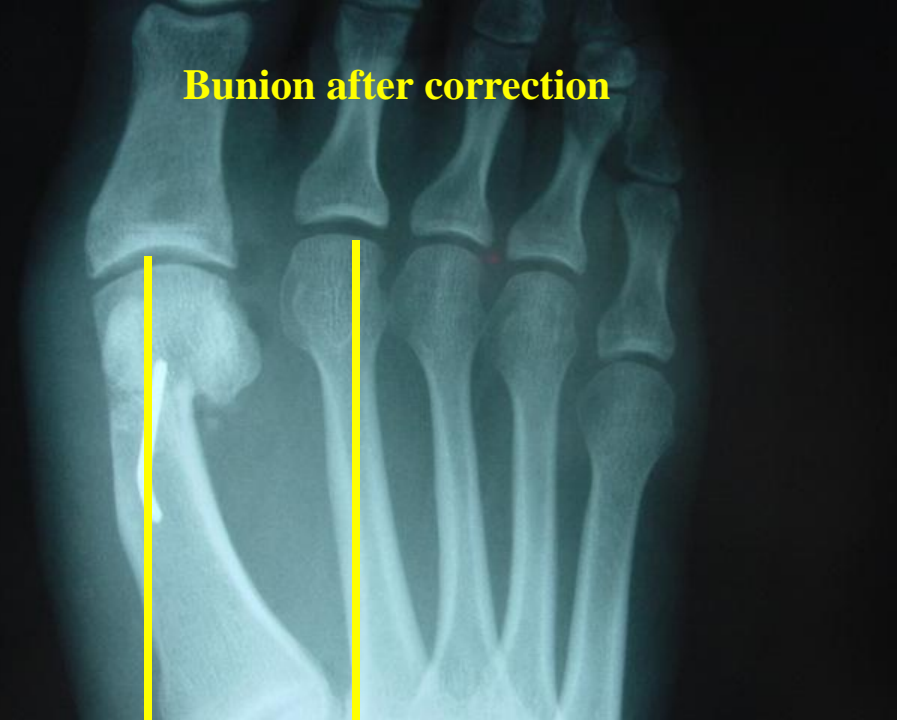


Bunion prior to correction

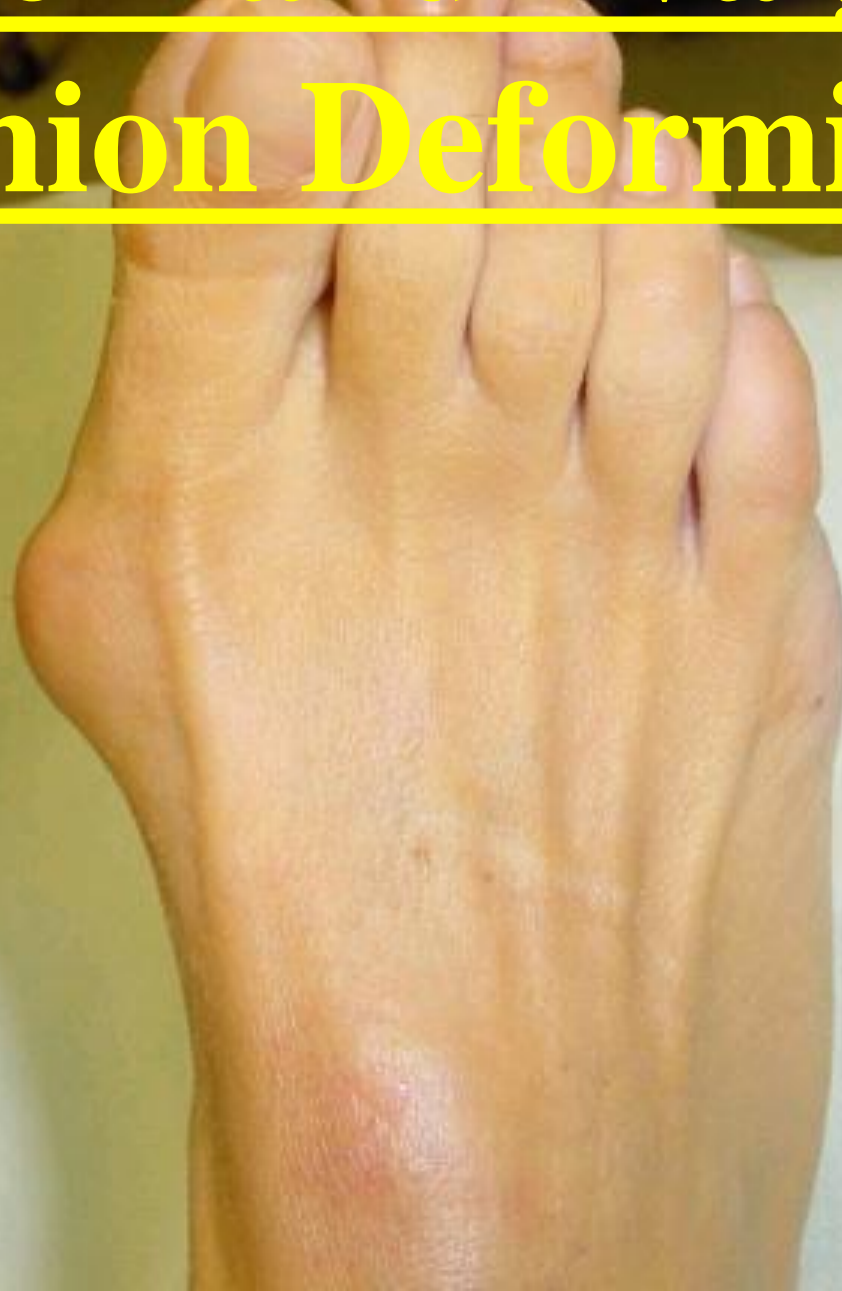

Hallux Valgus /
Bunion Deformity

Bunion after correction



Severe Hallux Valgus / Bunion Deformity

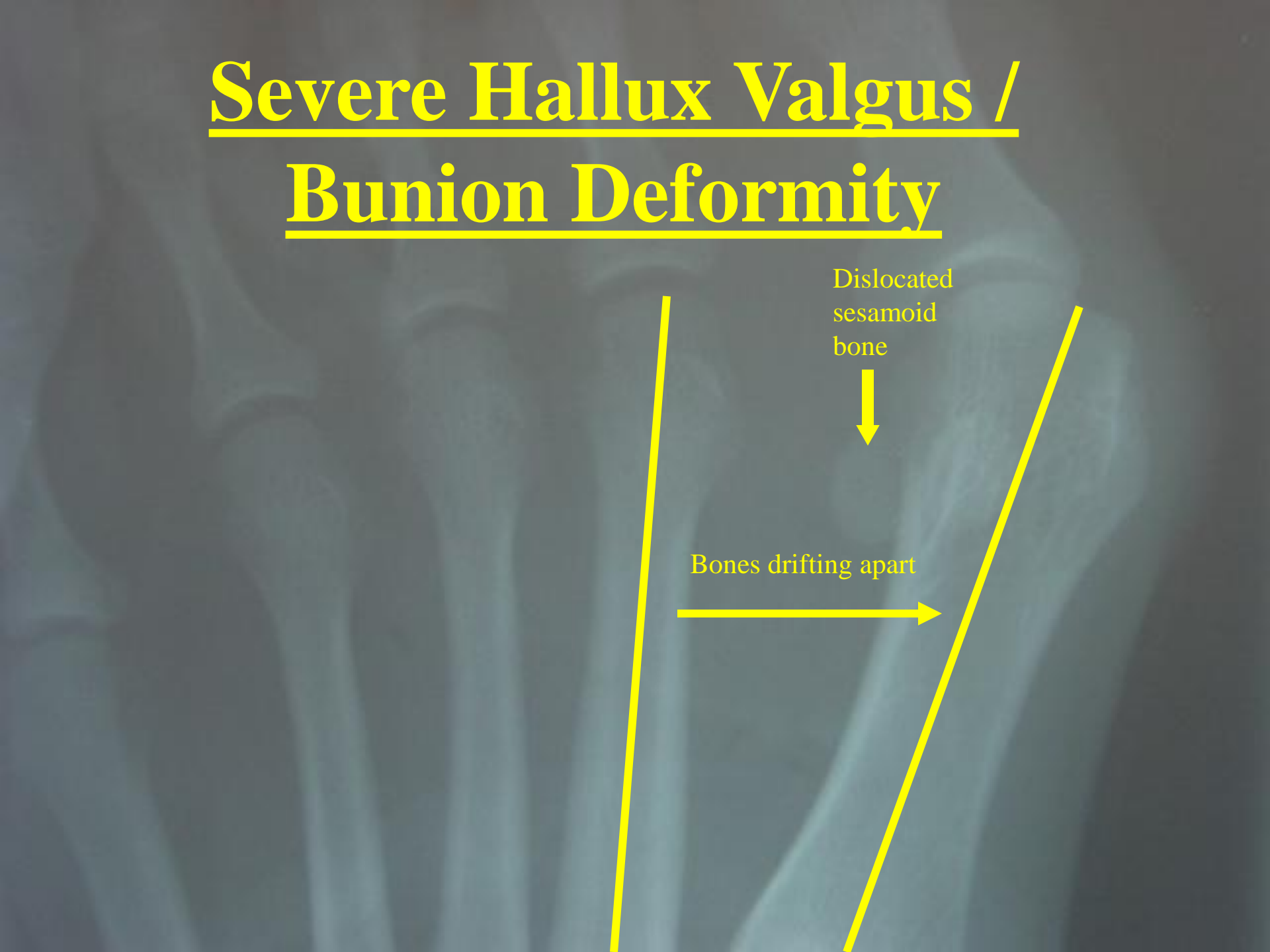


Severe Hallux Valgus / Bunion Deformity

Dislocated
sesamoid
bone



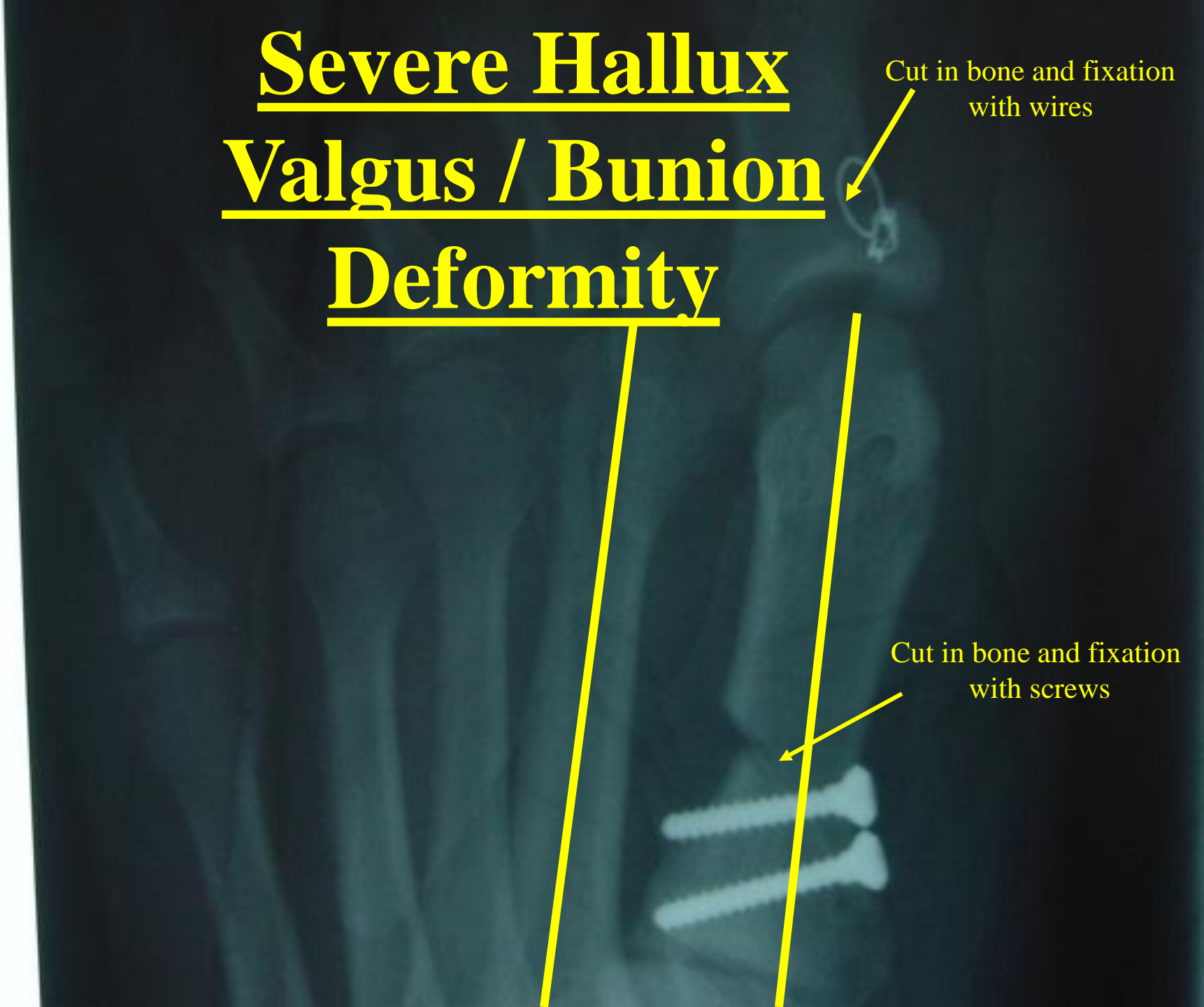Bones drifting apart



**Severe Hallux
Valgus / Bunion
Deformity**

Cut in bone and fixation
with wires

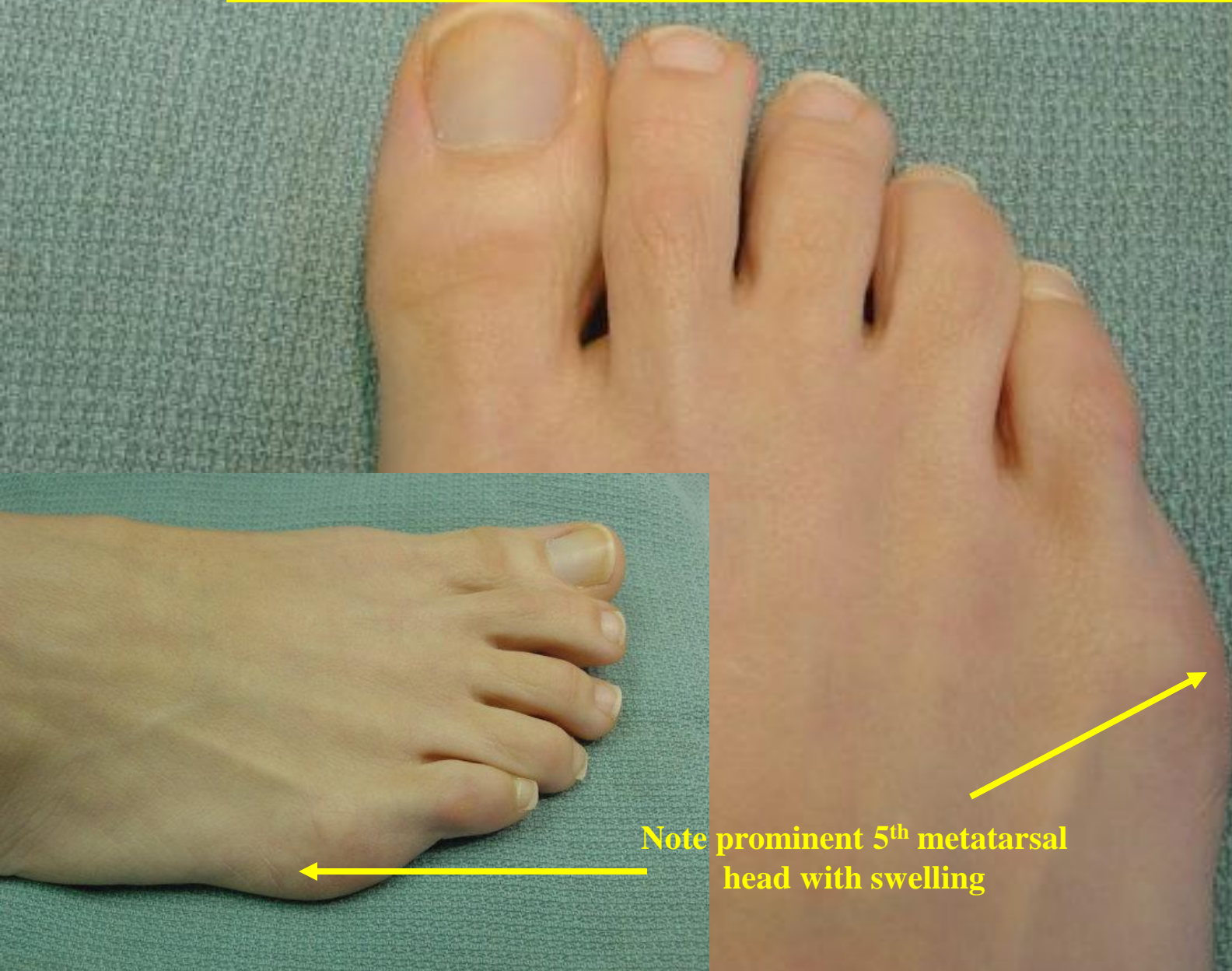
Cut in bone and fixation
with screws



Tailor's Bunion / Bunionette

- Bony deformity which is located on the outside part of the foot.
- The bump, bunionette or Tailor's Bunion, can become very painful due to shoe irritation.
- Tailor's bunions may be treated conservatively. Surgical correction may be necessary.

Tailor's Bunion / Bunionette



Note prominent 5th metatarsal head with swelling

Tailor's Bunion / Bunionette

Prior to Correction



Note Bowing of the Metatarsal

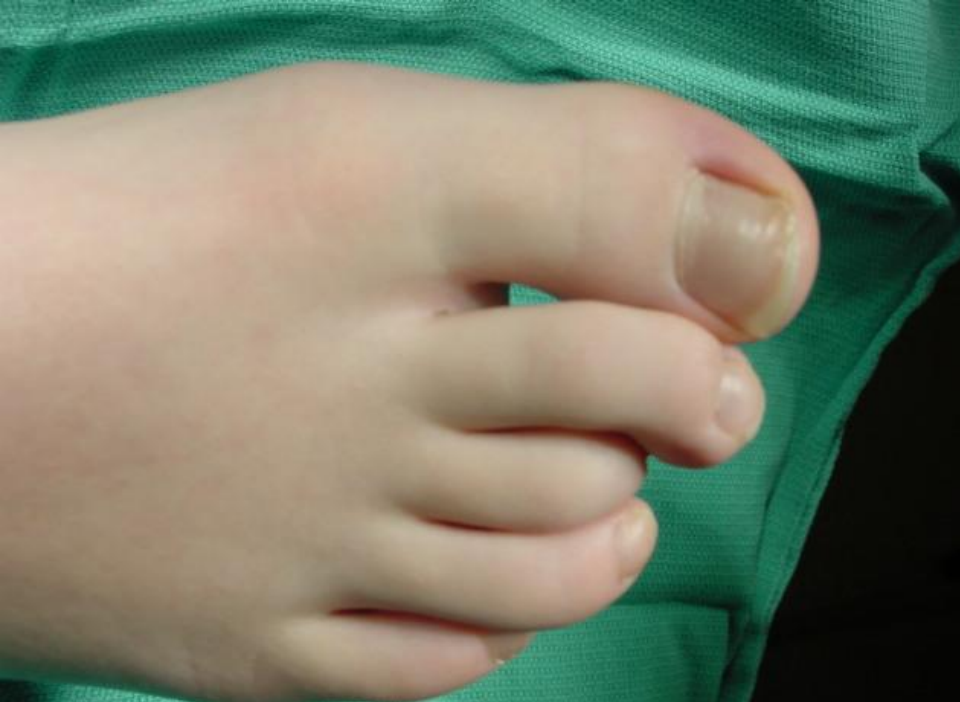After Correction



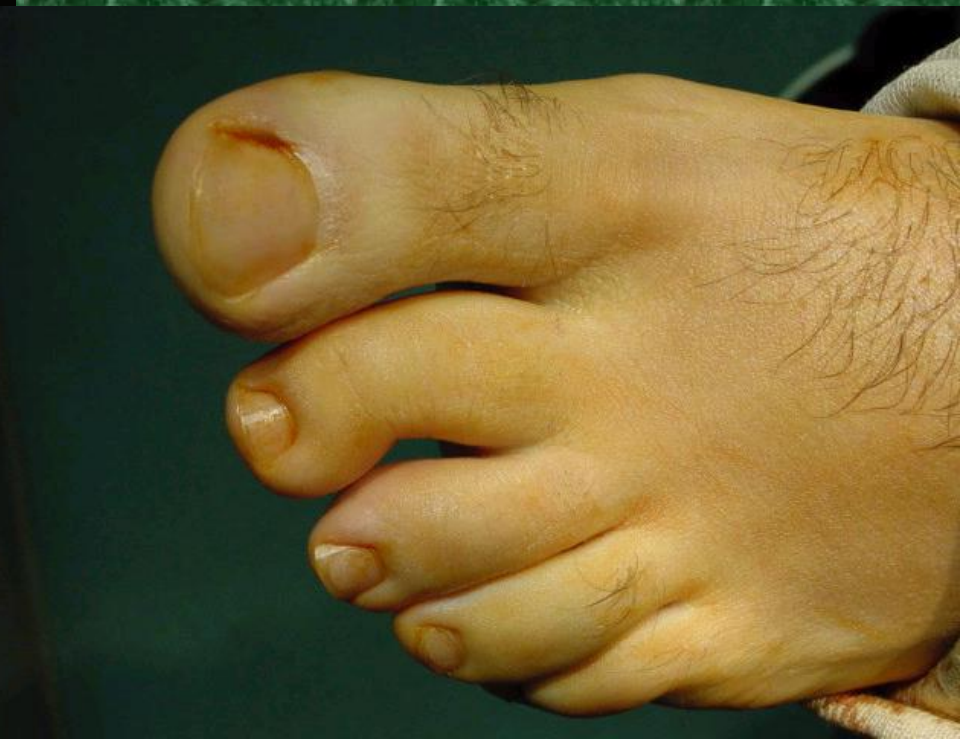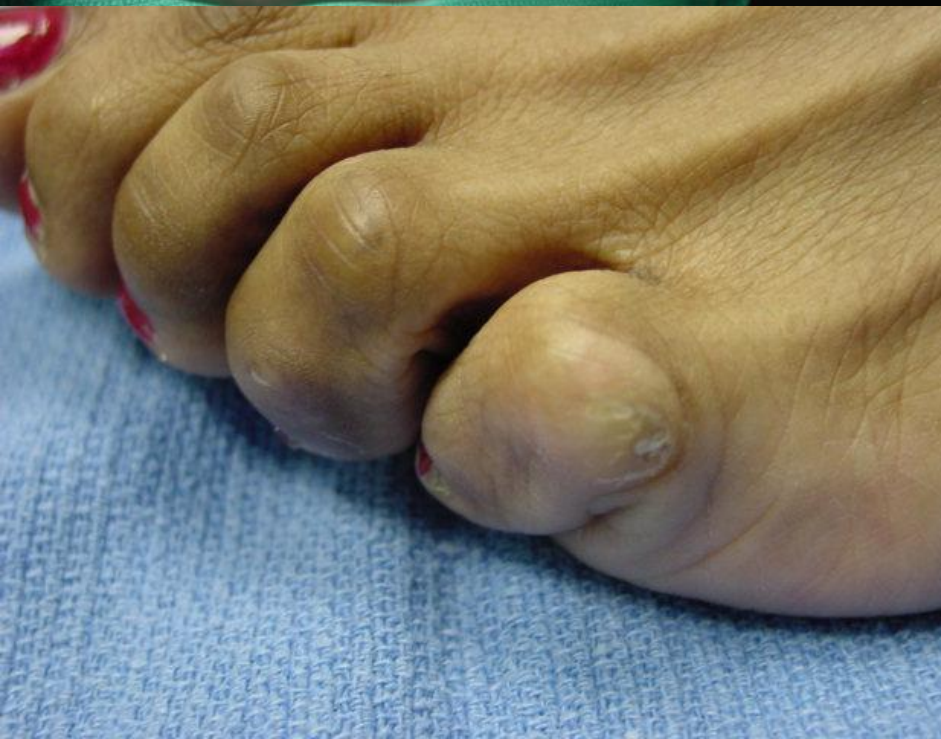Note Straight Metatarsal

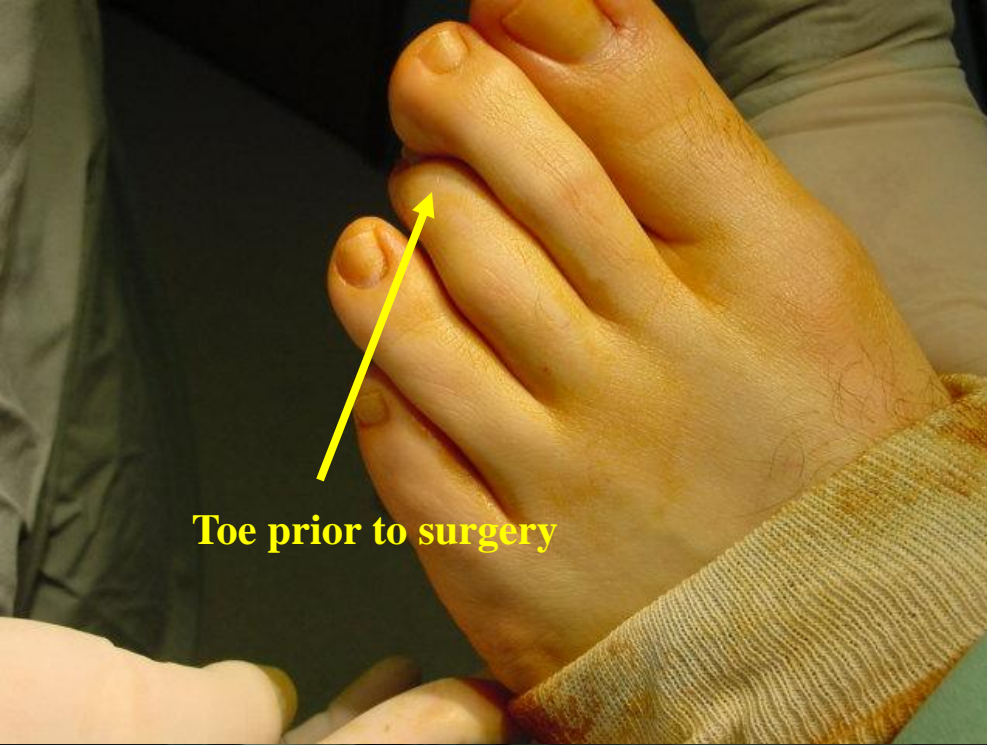
Hammertoe Deformity

- Contracted or abnormal position of the toes, which may be flexible or rigid in nature.
- Usually caused by weakened muscles of the foot.
- May cause pain due to irritation from other toes. The pain may be exasperated by tight fitting shoes.
- Hammertoes are often accompanied by a corn or callous.

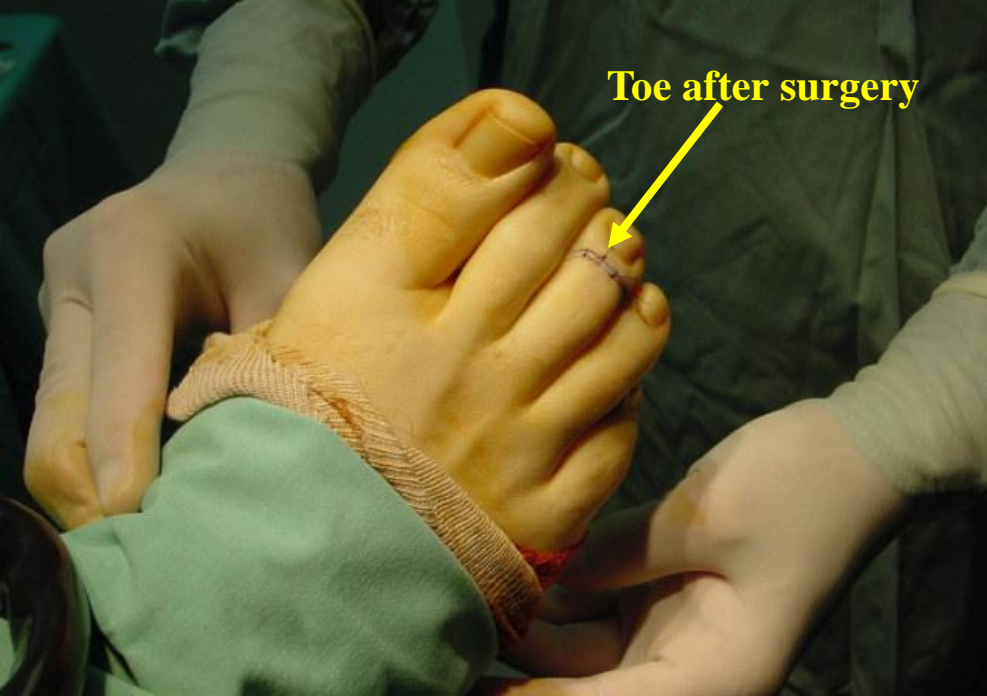

Hammer toe Deformity





Toe prior to surgery



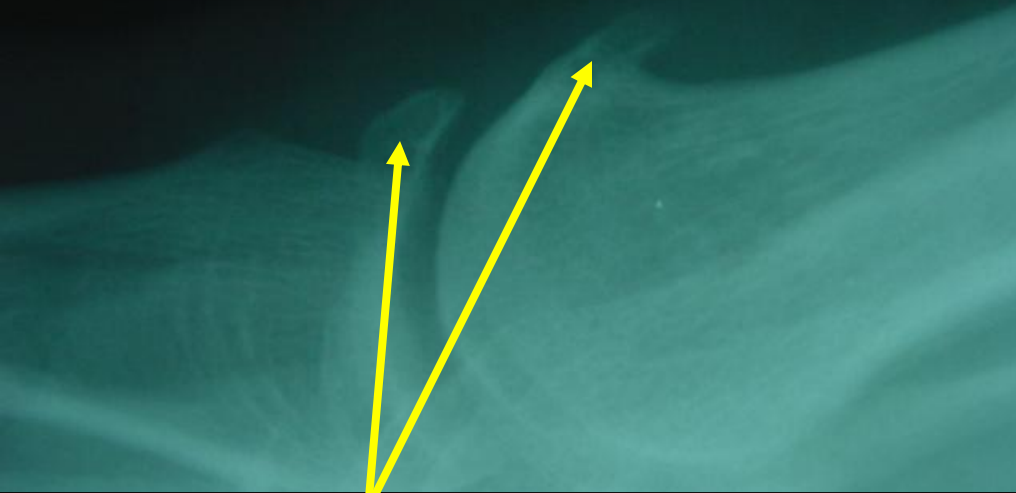
Toe after surgery

Hammer toe Deformity

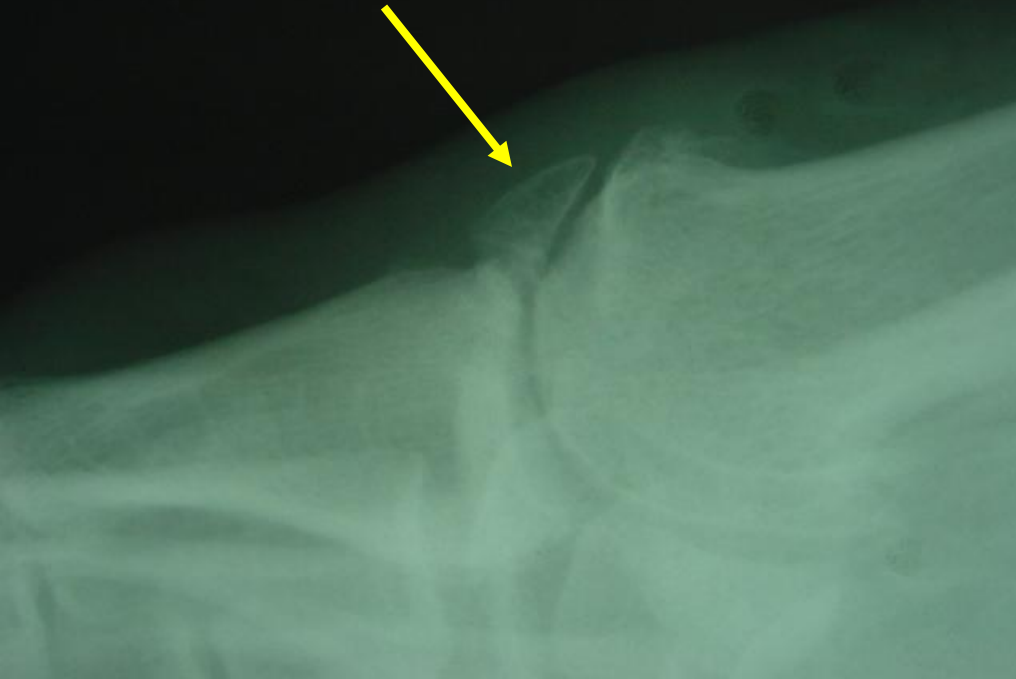Hallux Rigidus

- Osteoarthritis of the big toe joint usually associated with pain and restricted motion.
- May be caused by injury or repetitive joint damage due to a biomechanical / structural problem of the foot.
- Chronic wear and tear causes a wearing out of the cartilage at the joint and bone spurs to form.

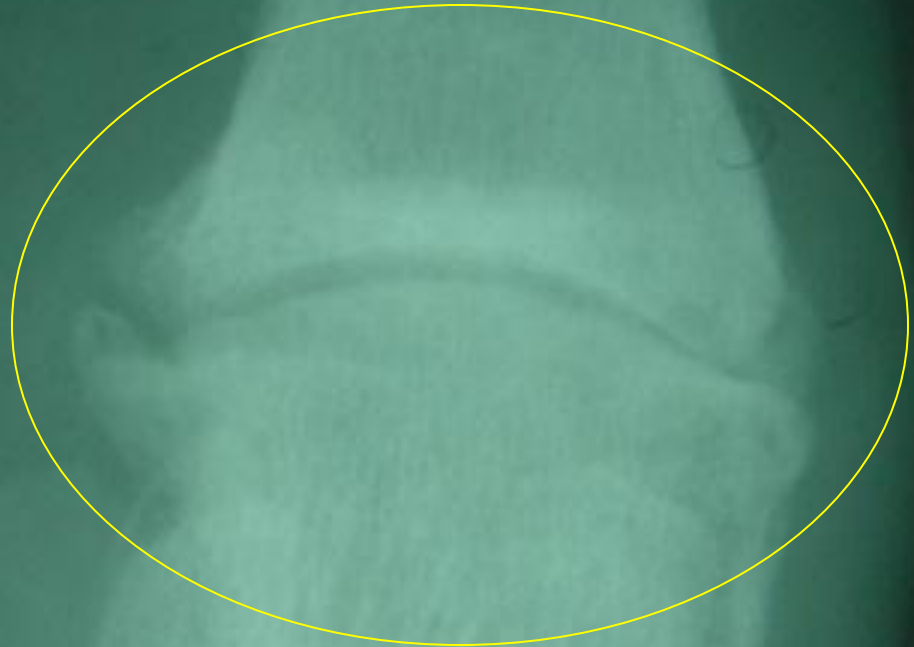
Hallux Rigidus of the Big Toe Joint



Note bone spur formation



Hallux Rigidus of the Big Toe Joint



Note joint space narrowing and bone spur formation at the joint margins

Rheumatoid Arthritis


- An inherited arthritis which affects joints in the feet and hands.
- The joint destruction and deformities are progressive in nature.
- May predispose patients to bunion and hammertoe formation.

Rheumatoid Arthritis

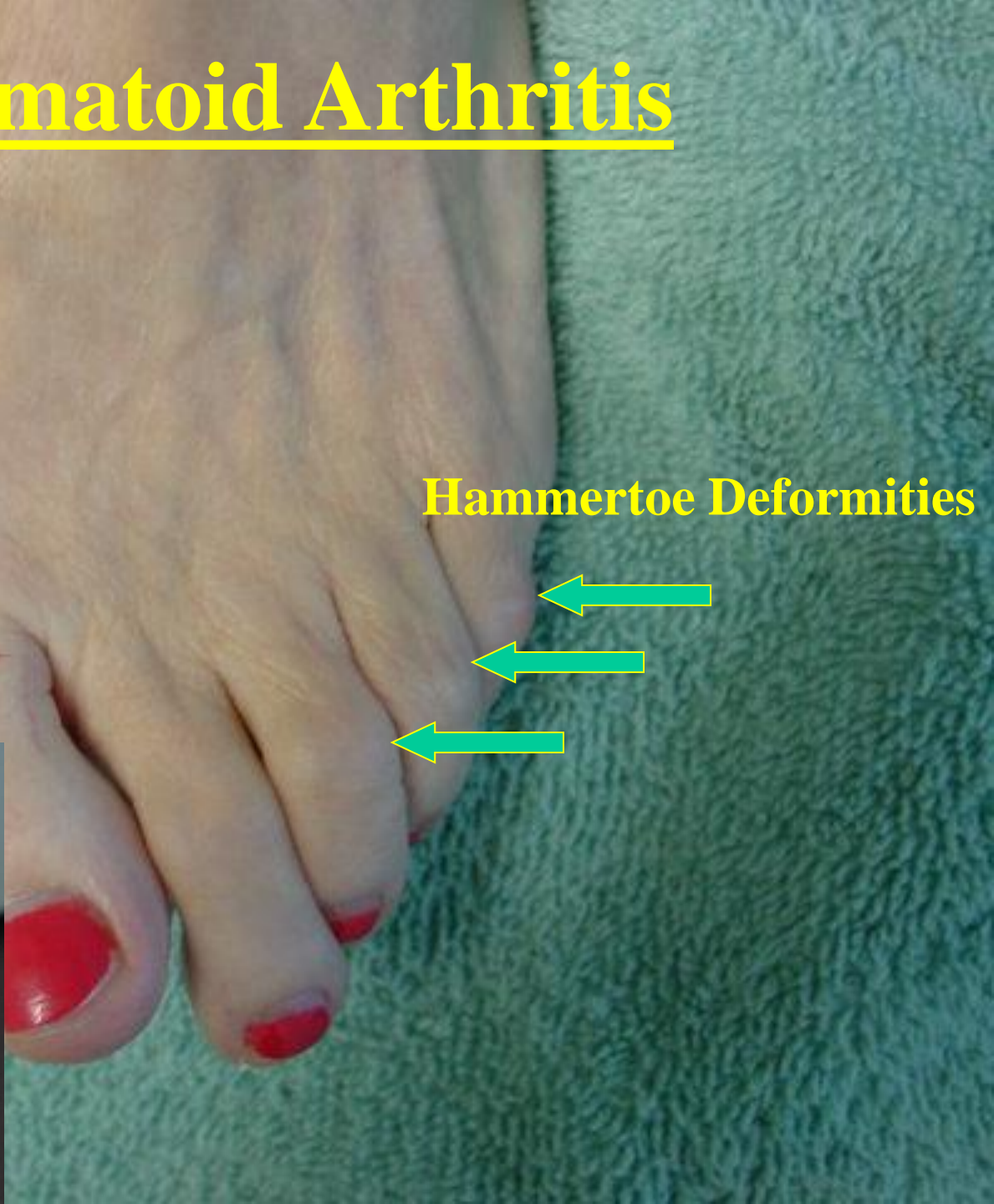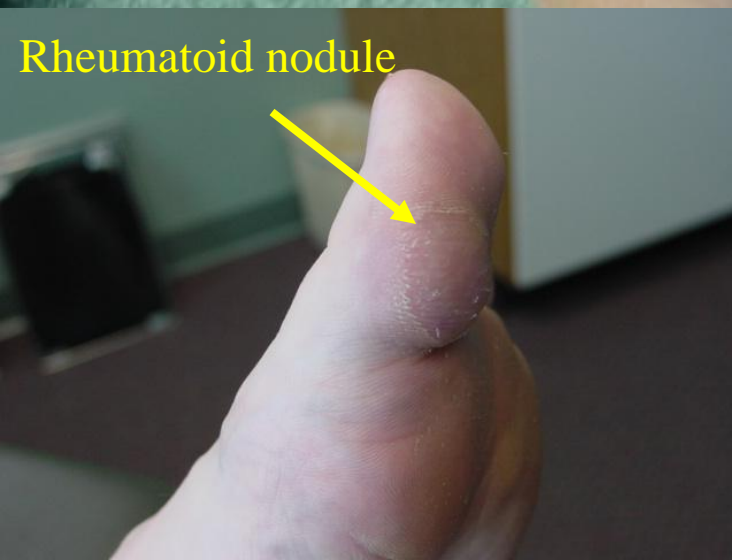Bunion Deformity



Hammertoe Deformities

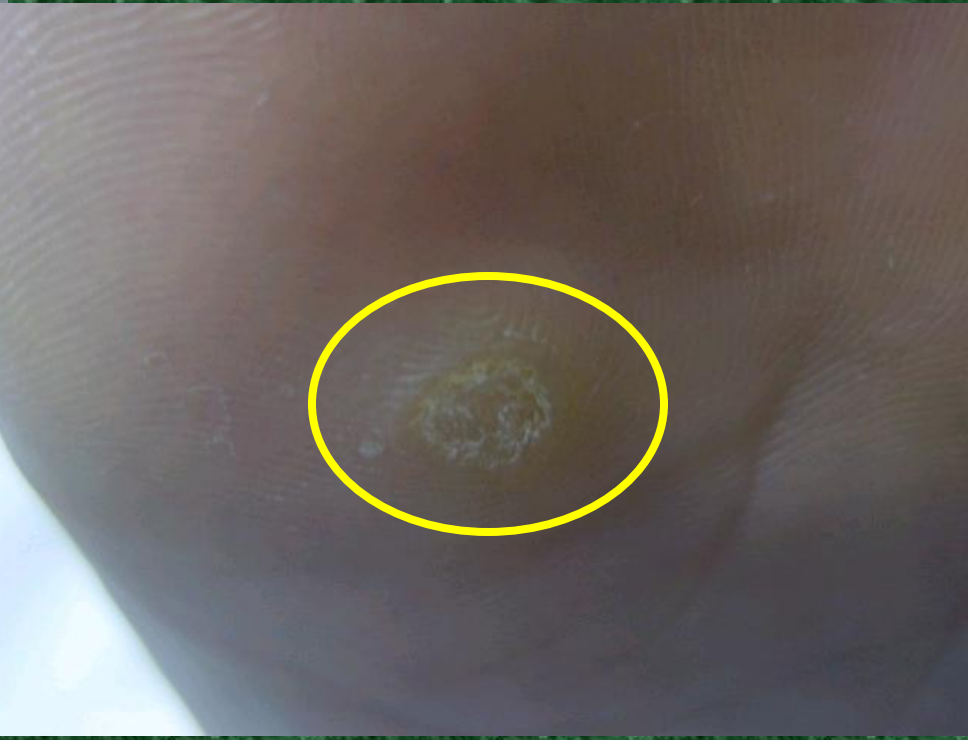
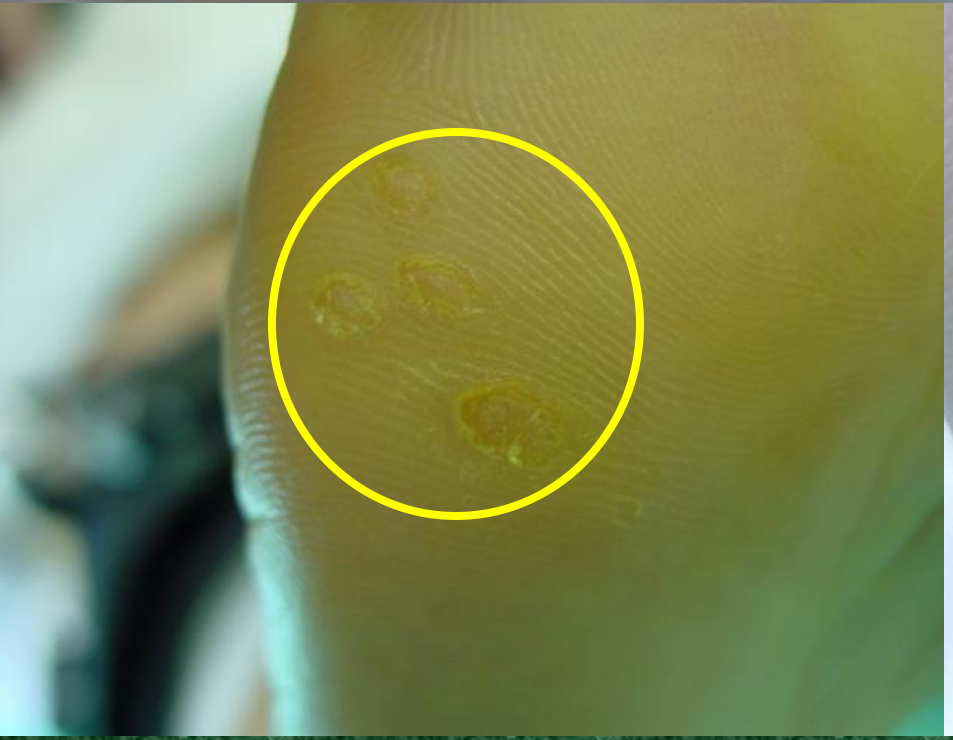
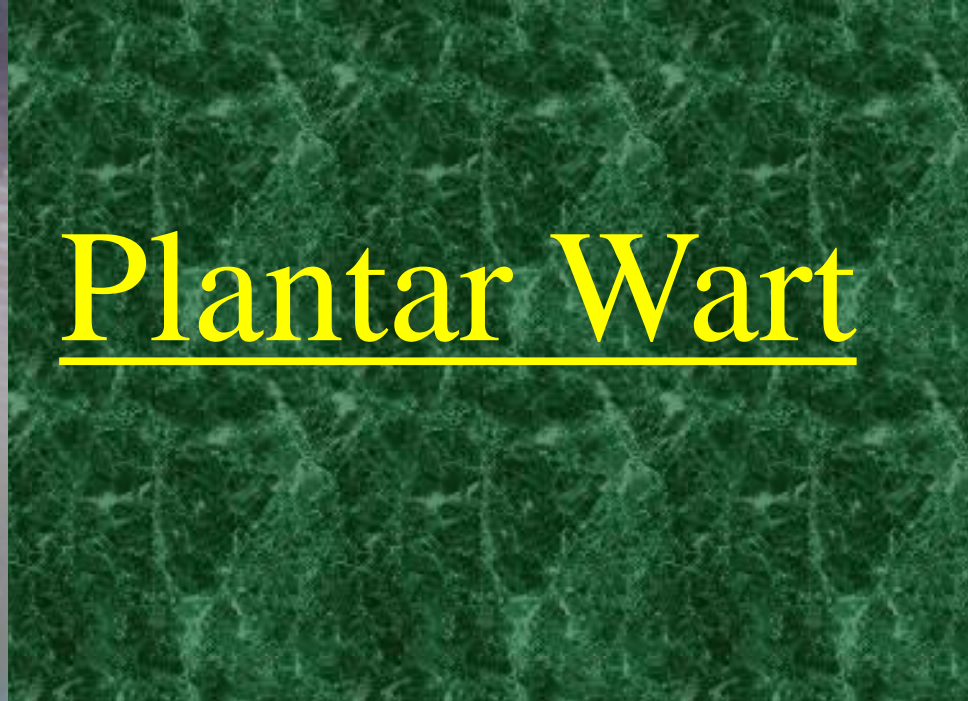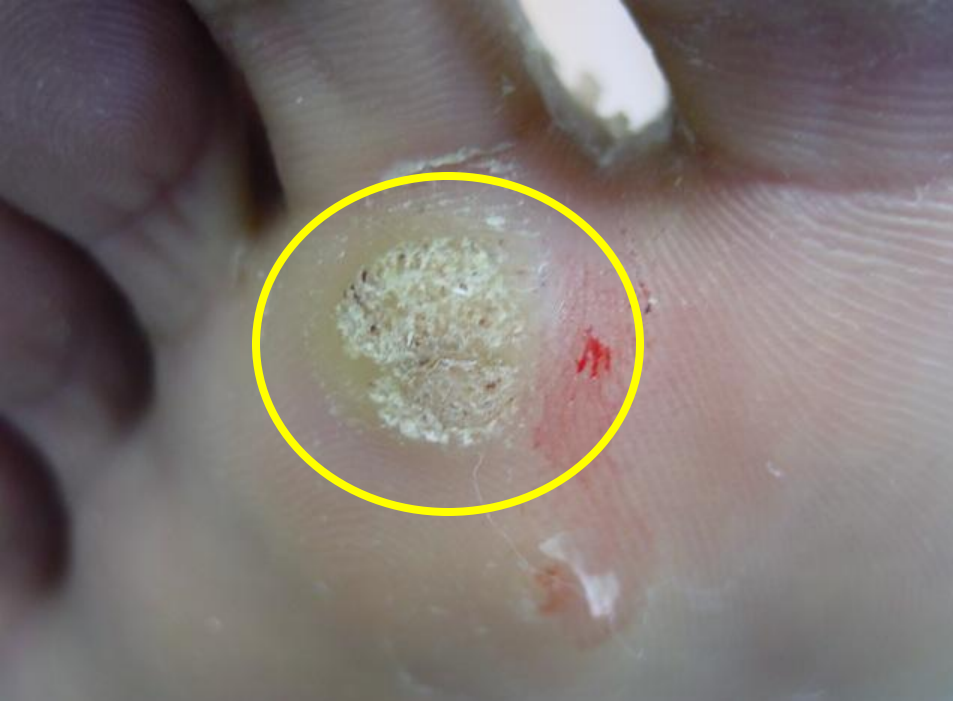Rheumatoid nodule



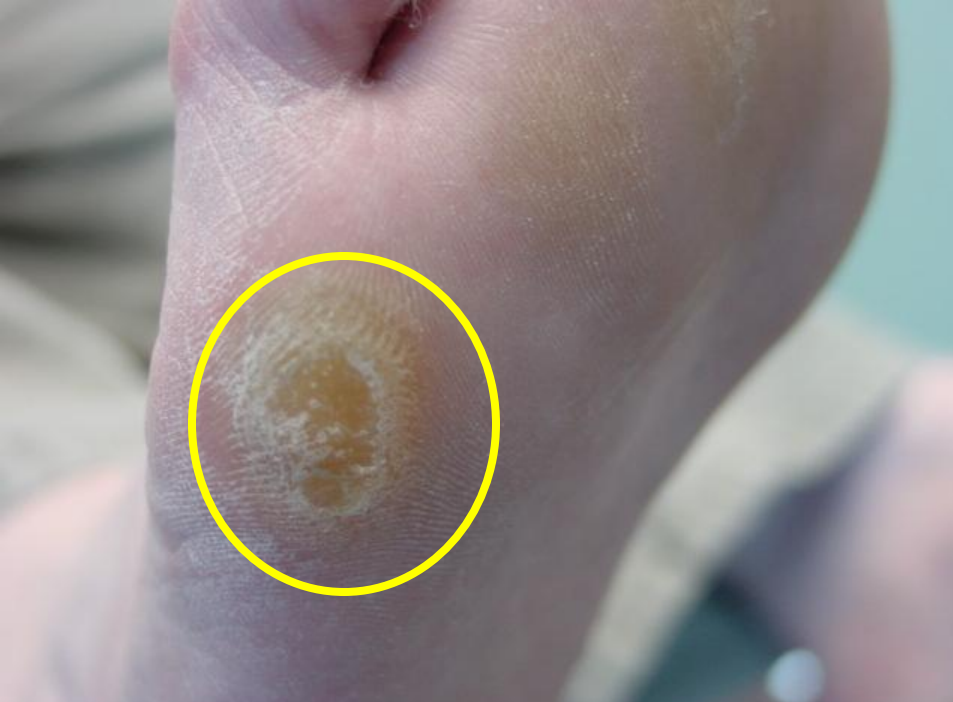Plantar Wart

- Human papilloma virus infection in the feet.
- Warts are obtained by barefoot exposure to the virus.
- Warts are often spread in showers, gyms, or other areas where barefoot walking is common.
- May be treated with any number of methods but recurrence ranges between 18-22%.

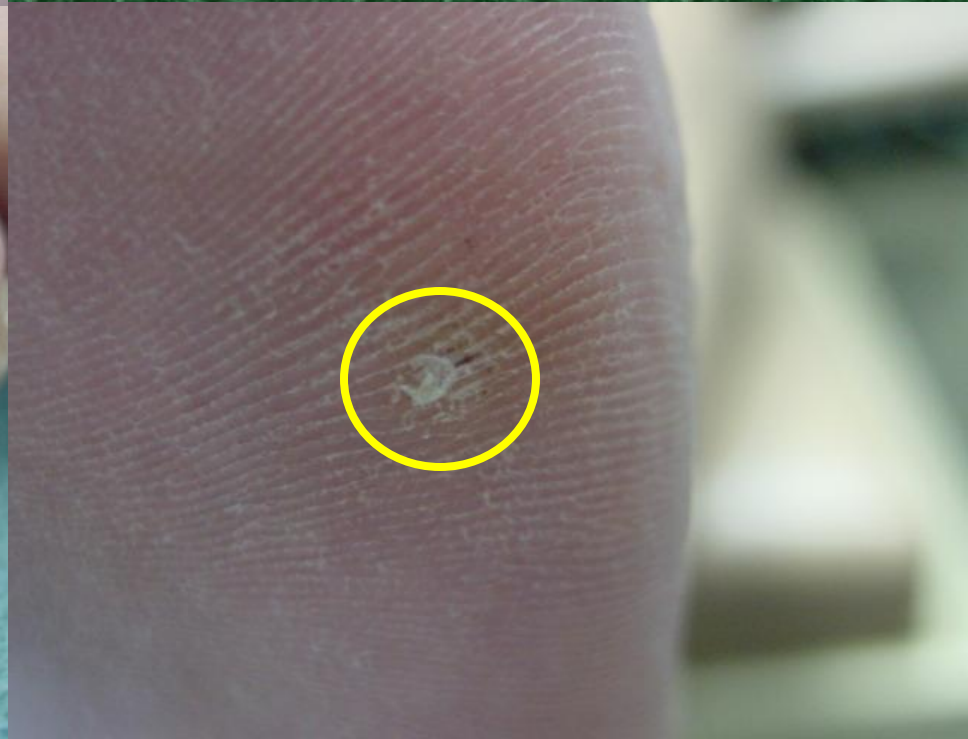
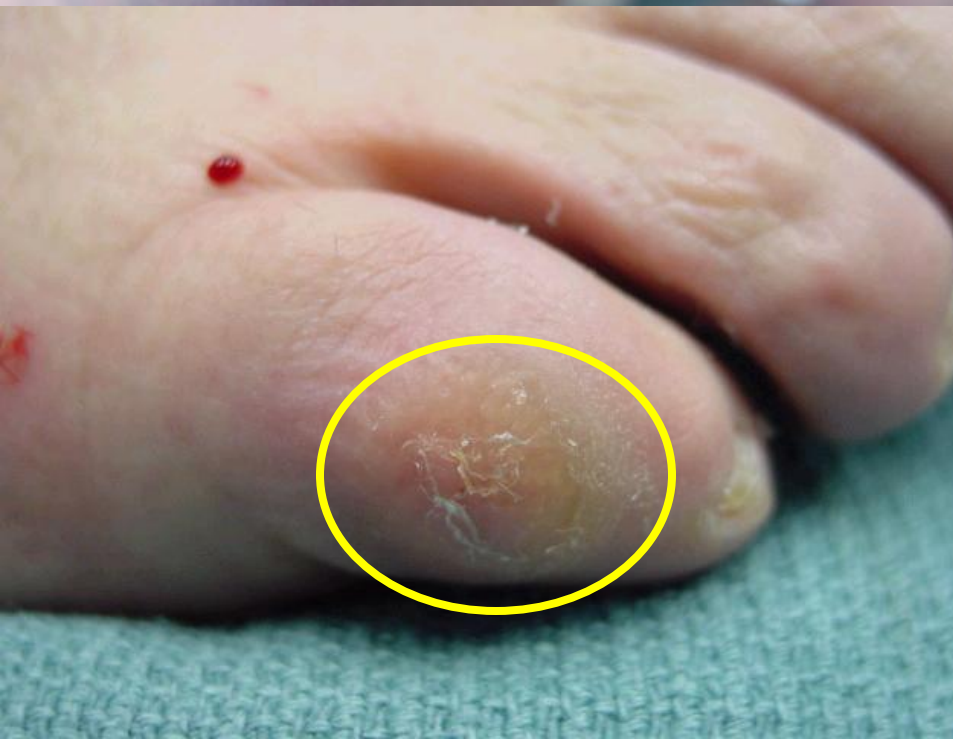
Callous / Corn

- Thickened area of skin caused by chronic rubbing or irritation of a bony prominence by the ground or shoe gear.
- Very high areas of pressure within a callous can develop a painful central core.
- Lesions reoccur because the cause of the lesion is often from bone.

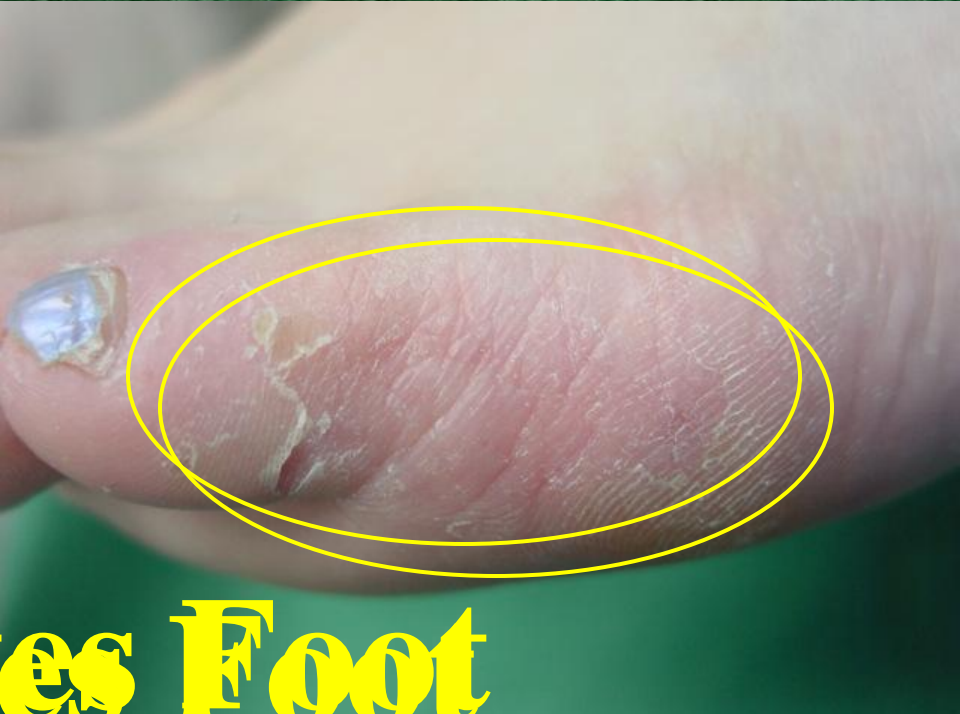
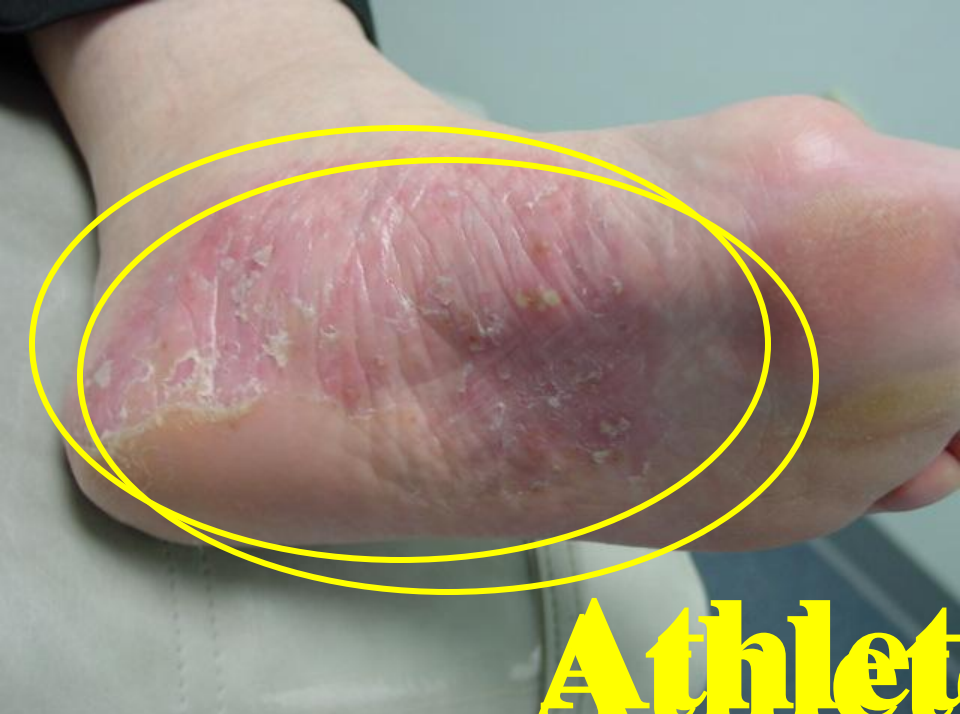
Callous / Corn

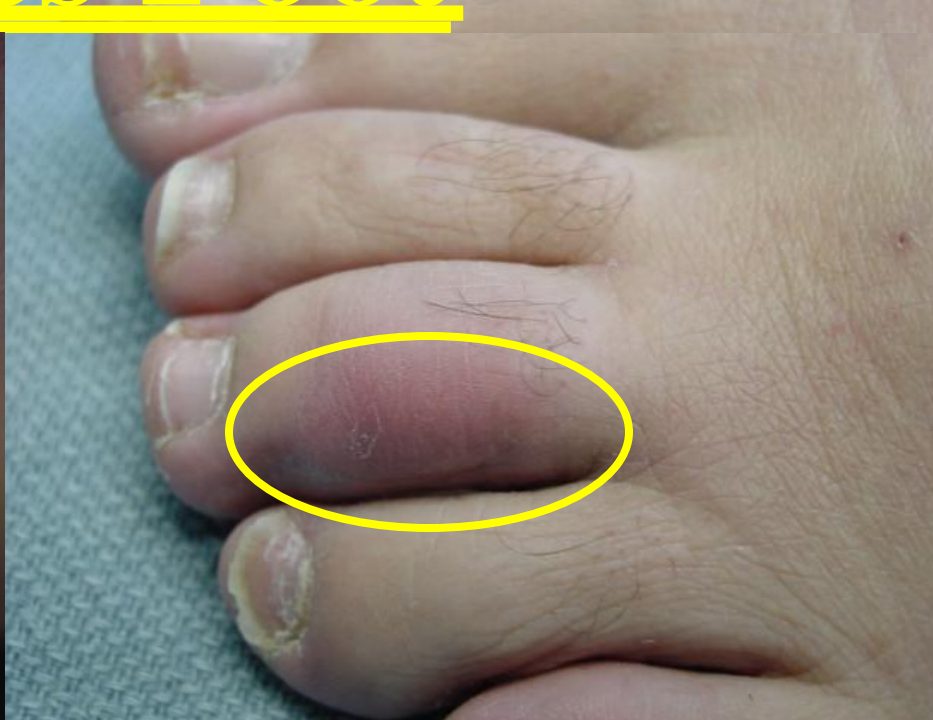
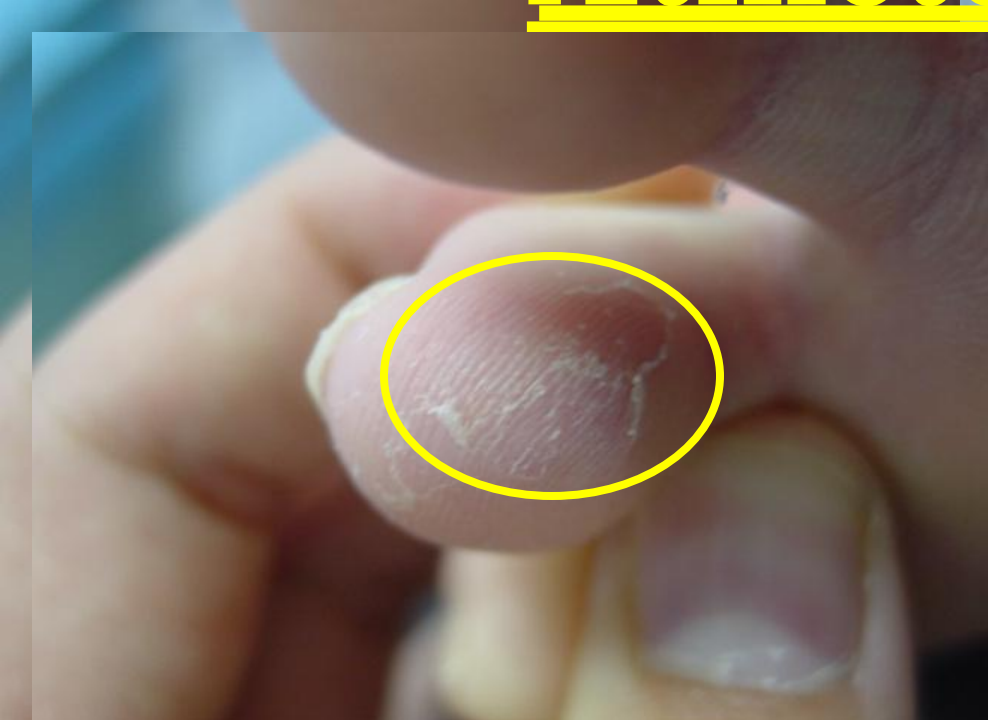
Athletes Foot

- A fungal infection typically caused by fungus found in soil (Dermatophyte).
- Picked up by contact with the fungus usually walking barefoot (Gym, hotel, pool, etc.).
- May occur anywhere on the foot and may burn and/or itch.
- The affected areas of skin will often peel or may have small blisters.



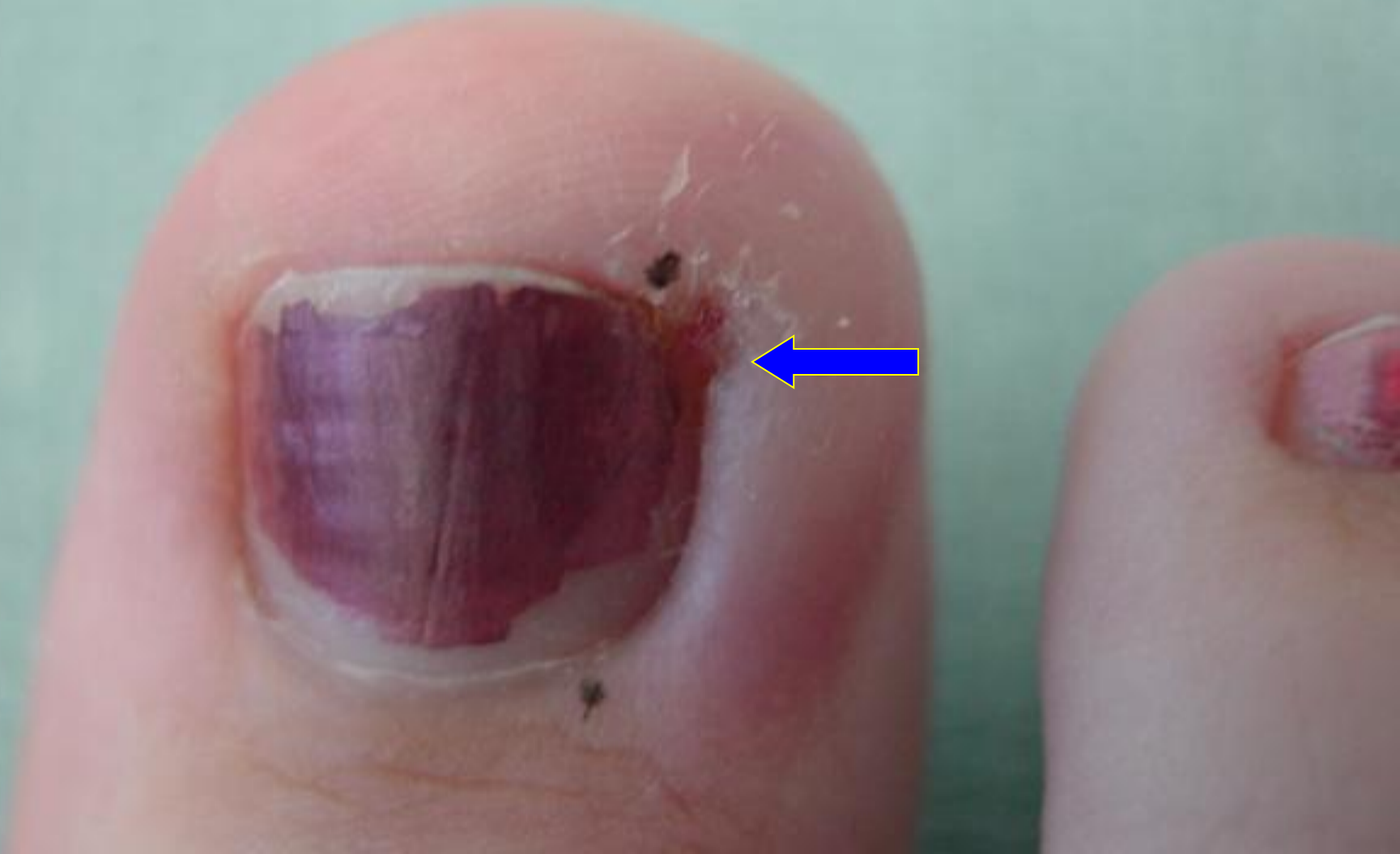Athletes Foot



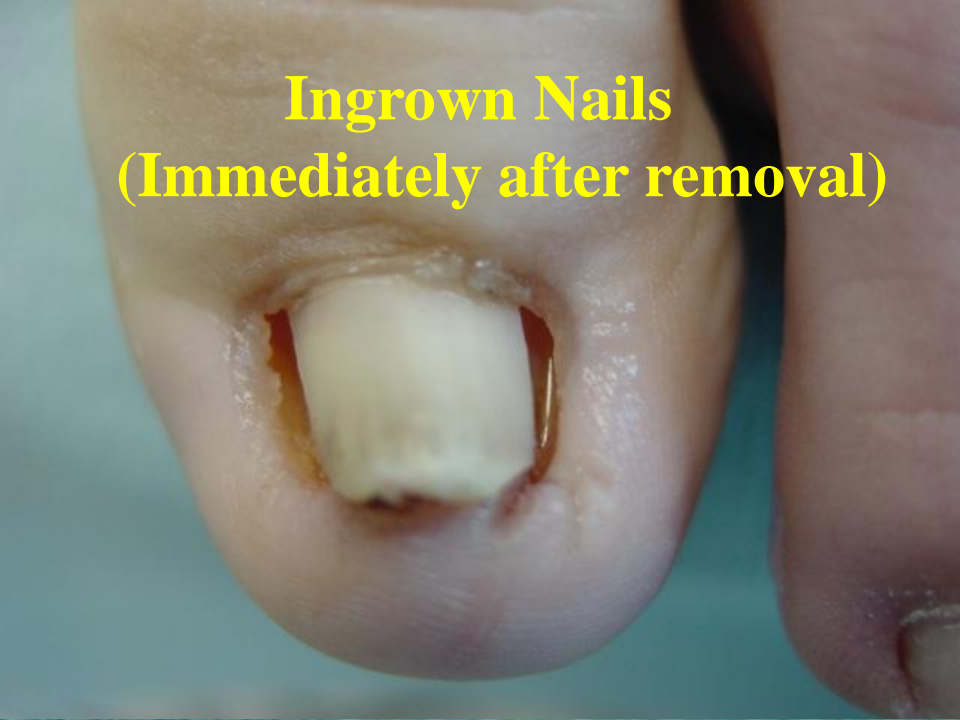Ingrown Nails

- Toenail which grows into the skin. Most often caused by a wide toenail and an external pressure.
- The nail may cause pain or infection due the pressure of the nail border.
- May be treated with removal and/or antibiotics. May be permanently corrected with retaining a normal nail appearance.

Ingrown Nails

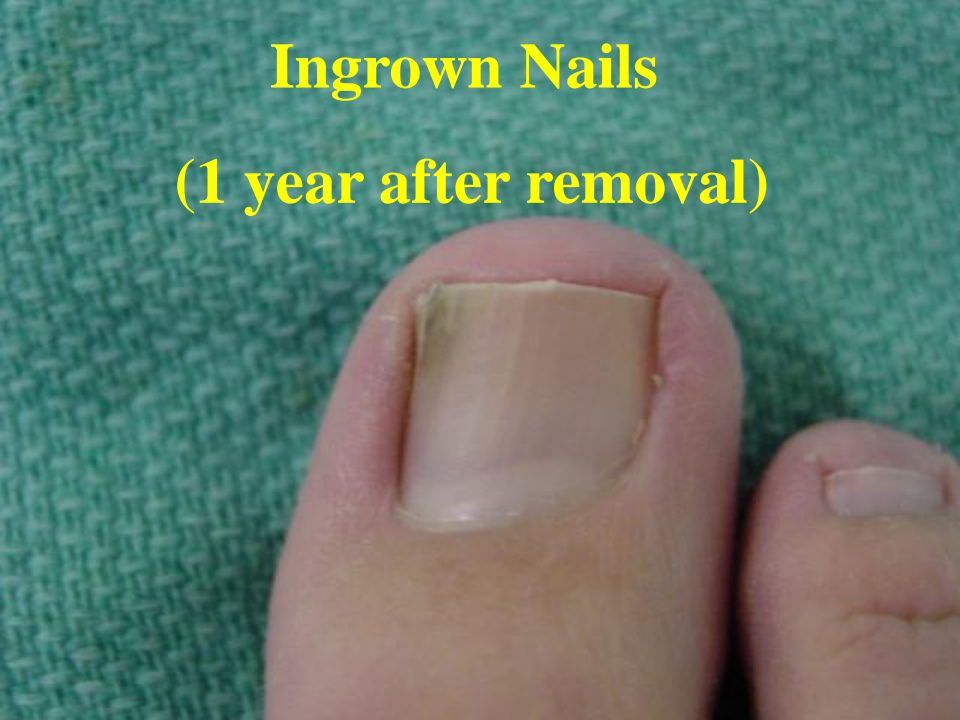

**Ingrown Nails
(Immediately after removal)**



Ingrown Nails

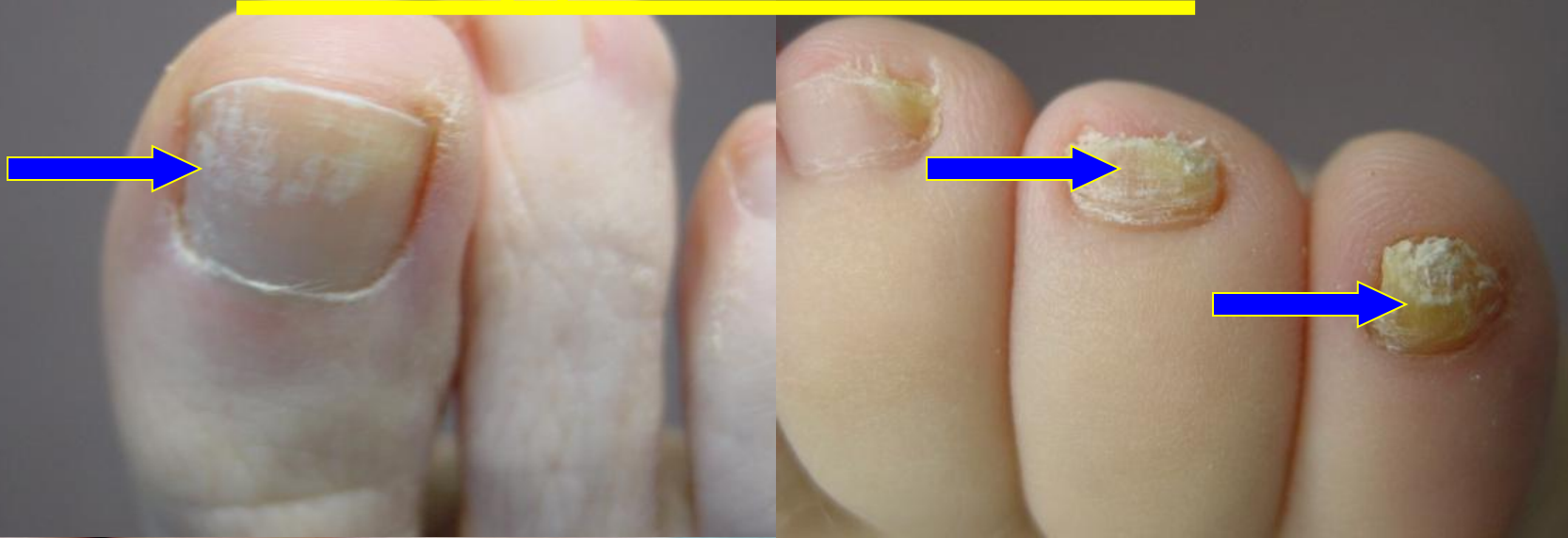**Ingrown Nails
(1 year after removal)**



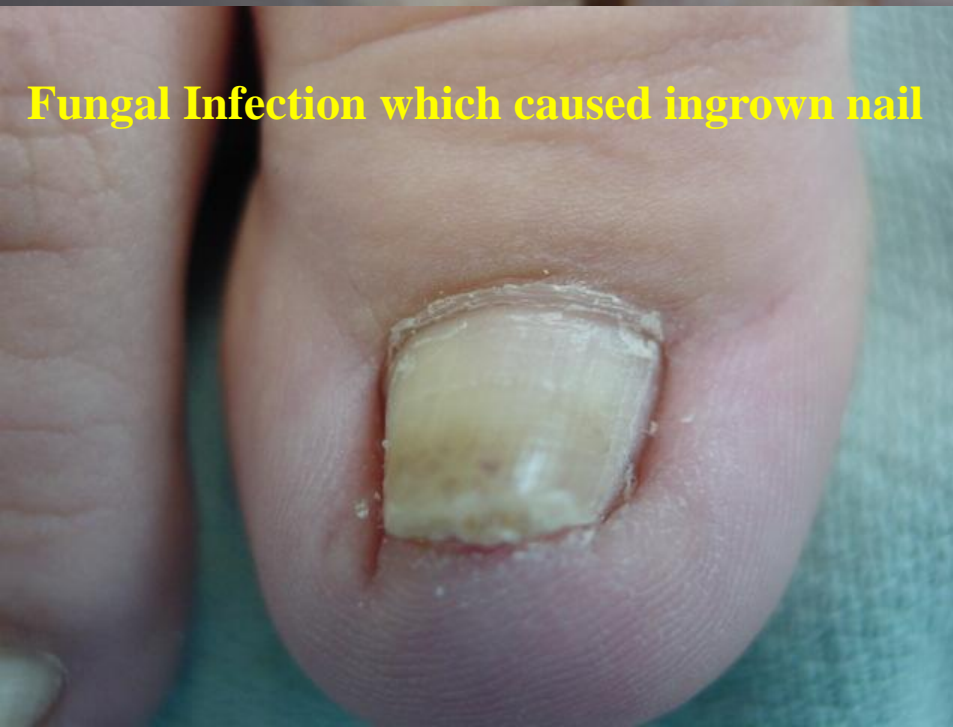Fungal Toenail

- A thickened nail caused by a fungus.
- Initially caused by an injury to the nail which allows the organism to enter the nail.
- Progressive in nature and slow growing.
- May spread to other nails or other people in close contact. Organism may also spread from nail to the skin (athletes foot).
- May be treated if pain or concerns arise.

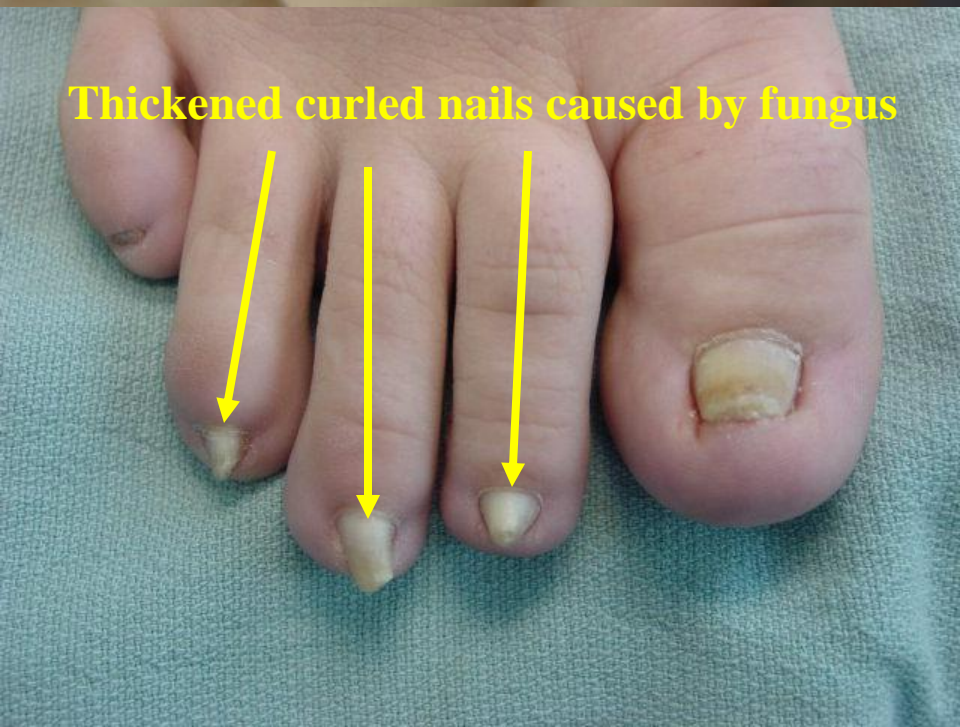Fungal Toenail



Fungal Infection which caused ingrown nail



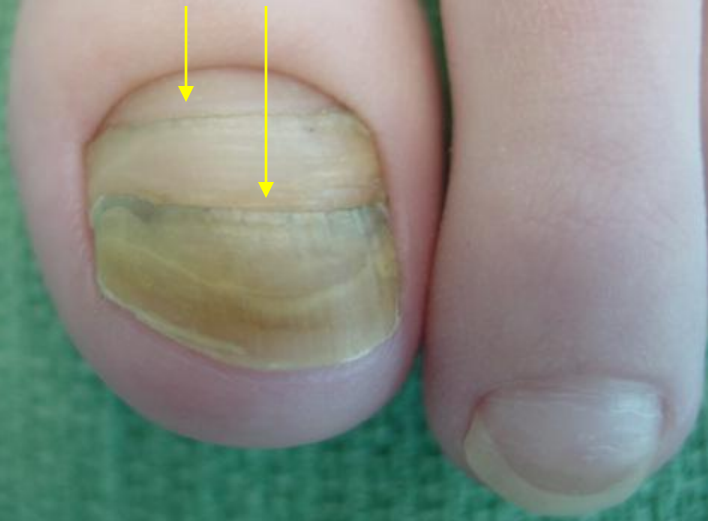Thickened curled nails caused by fungus



Nail Injury

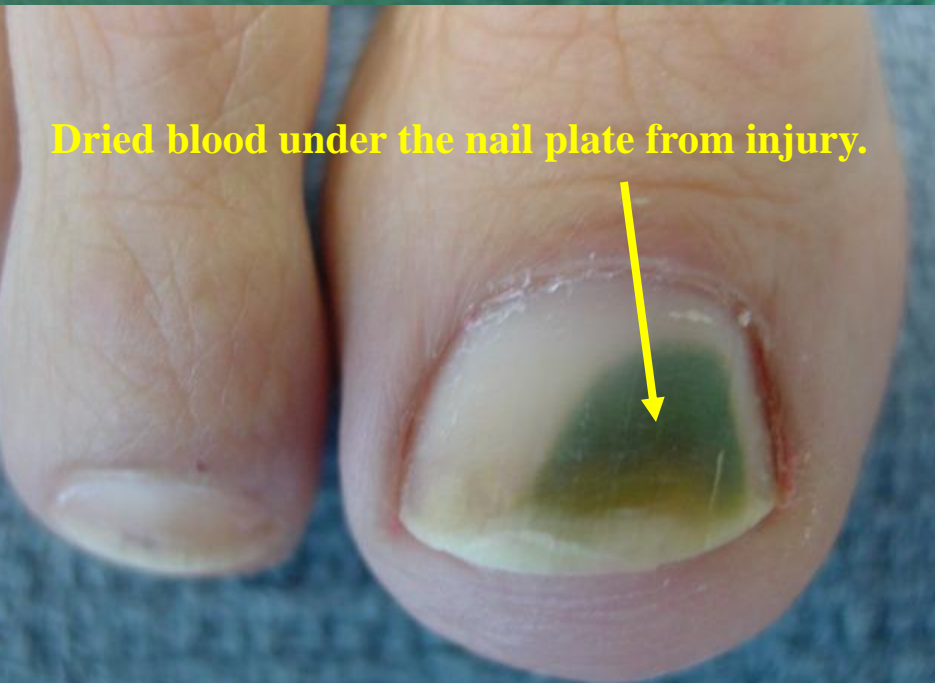- Chronic injury (i.e. athletic activities) causes injury to the nail root and results in nail horizontal layers.
- Isolated injury may also cause bleeding under the nail, leaving a dark spot which persists until the nail grows out.

Lines of injury



Nail Injury

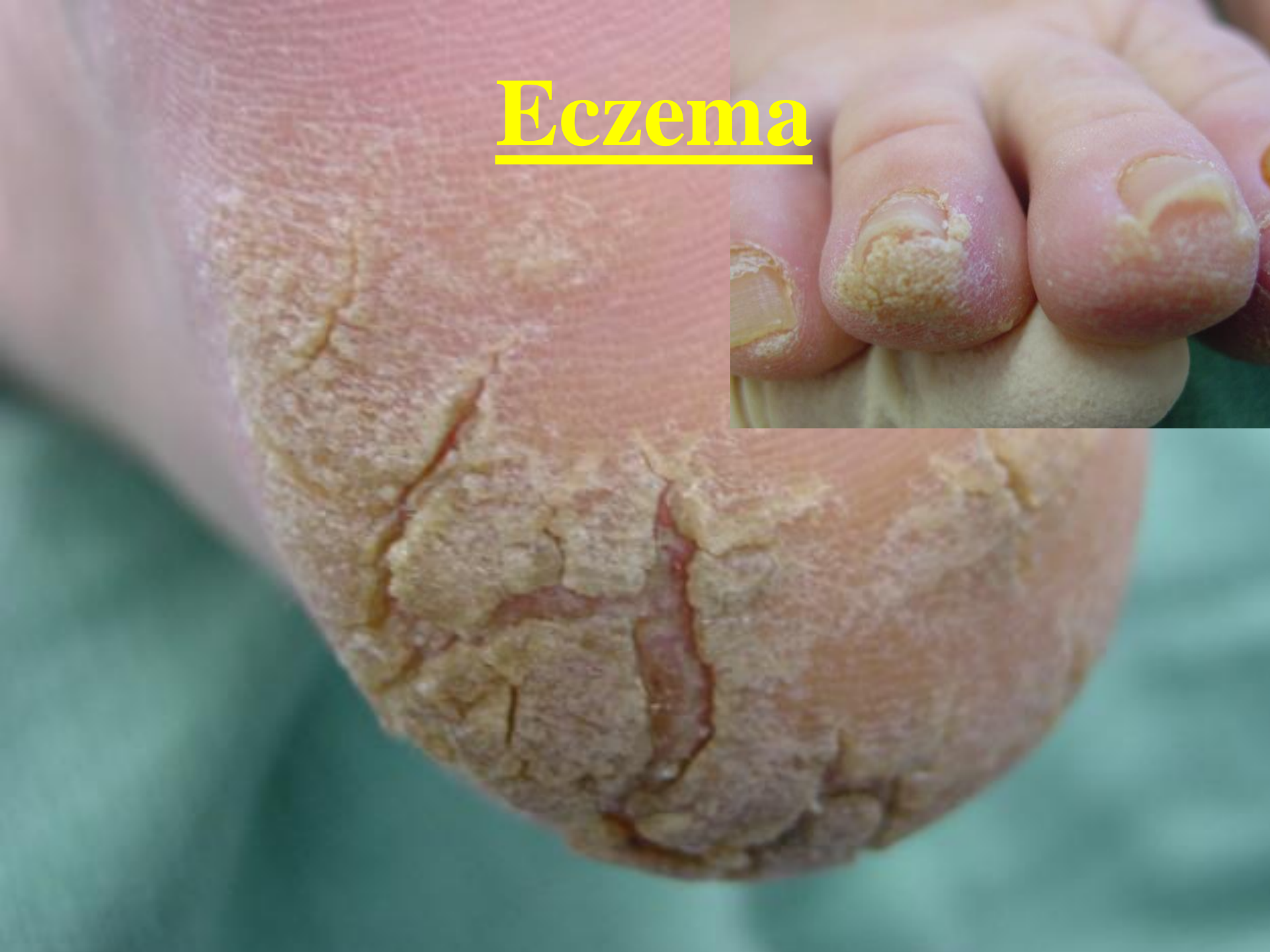Dried blood under the nail plate from injury.



Eczema

- A skin inflammatory condition usually associated with redness, itching, skin cracking or small blisters.
- May be chronic in nature and may worsen with changes of season.
- Treatment varies dependant on severity.

Eczema

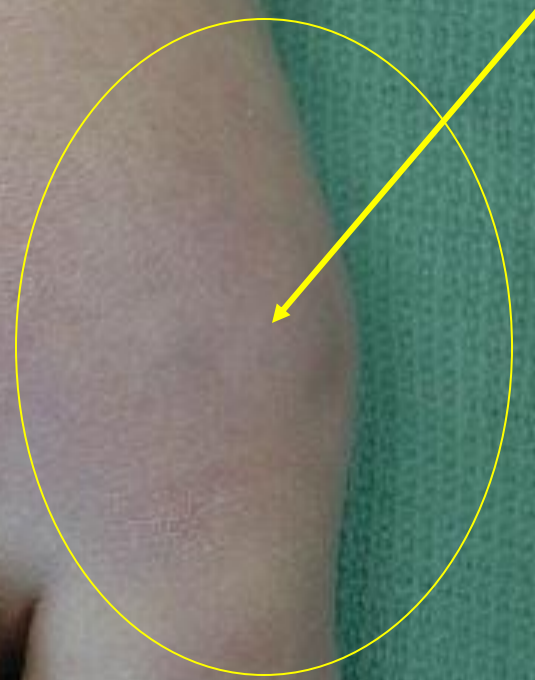

Gout

- A build up in the blood and tissue of uric acid. Uric acid arises naturally in the body and from the breakdown of certain foods; red meats, seafood, and some nuts.
- Attack may be triggered by dehydration.
- Most commonly attacks the foot in the big toe joint. Symptoms include severe pain and swelling.
- Treatments vary.

Gout

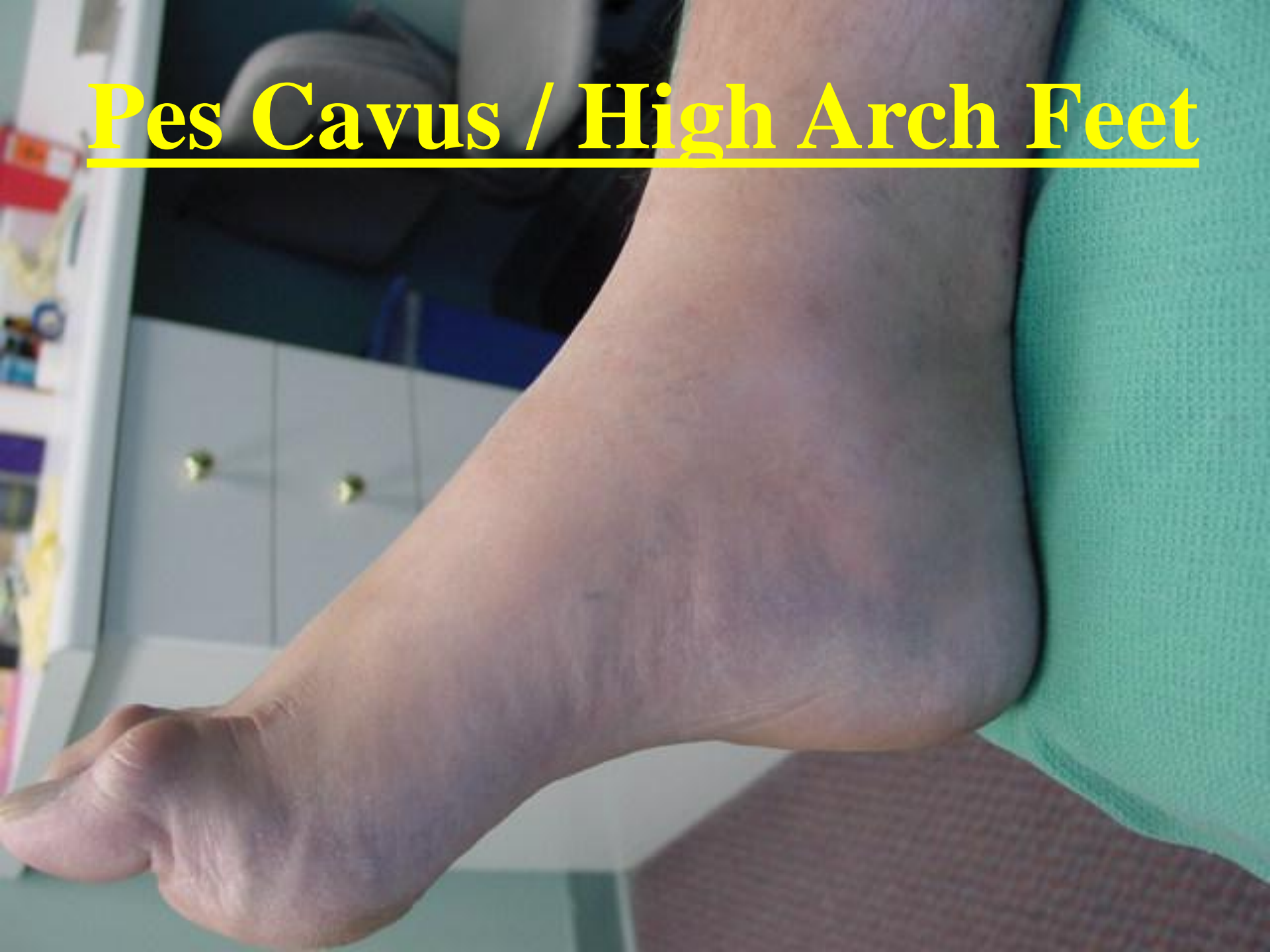Redness and swelling of the big toe joint



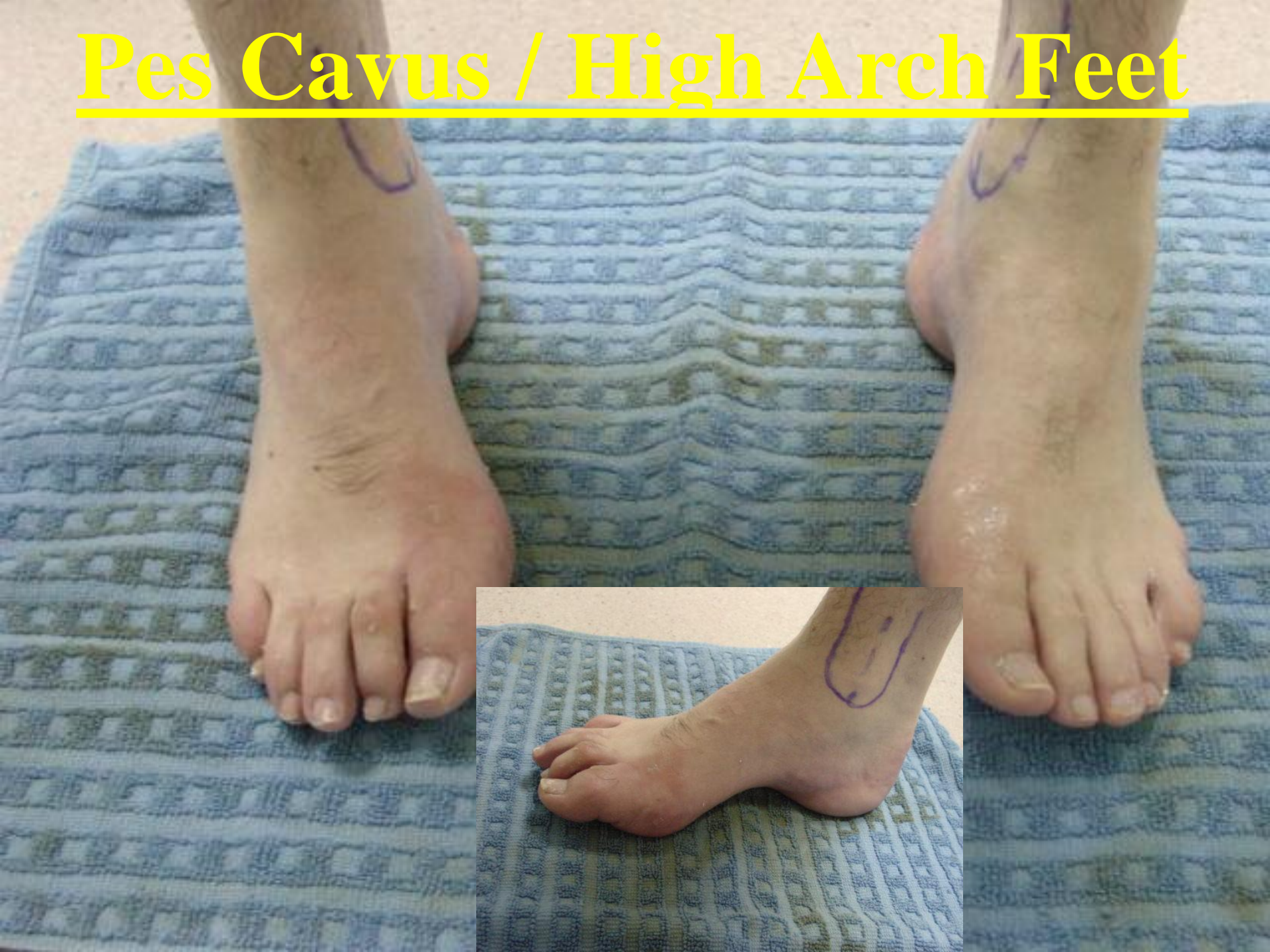High Arched Feet / Pes Cavus

- Condition which may arise naturally or come from certain neurological disorders (Polio, MS or CP).
- May cause pain in the Achilles Tendon, arch or ball of the foot.
- Individuals are predisposed to contracted toes, arthritis or chronic ankle sprains.
- Treatments range from conservative to surgery.

Pes Cavus / High Arch Feet



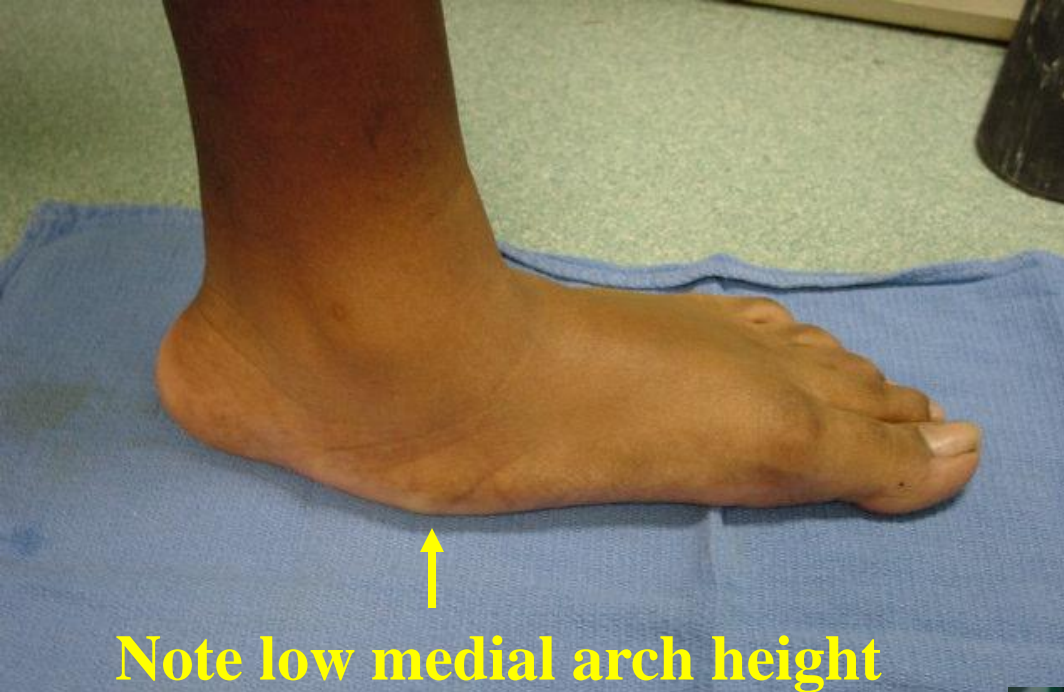Pes Cavus / High Arch Feet



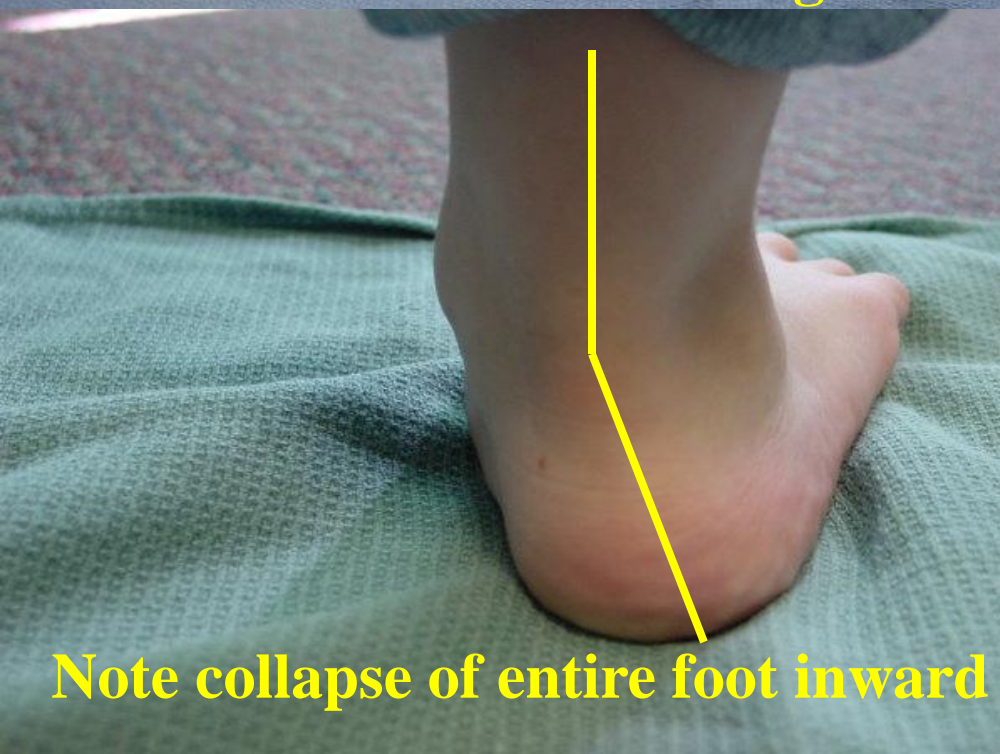Flat Feet

- A structural problem of low arches
- May be congenital or acquired.
- Pain may occur in the feet, ankles, knees or back. Individuals may be predisposed to bunions or arthritis.
- Can be corrected with shoe style changes, custom shoe inserts and surgery.

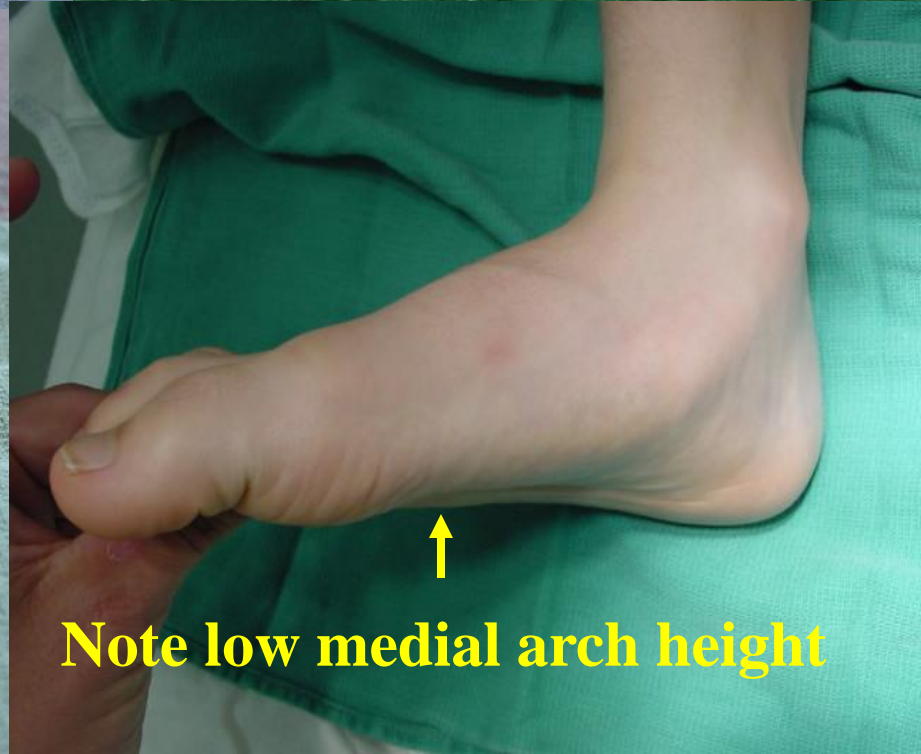
Pes Planus / Flat Feet



Note low medial arch height



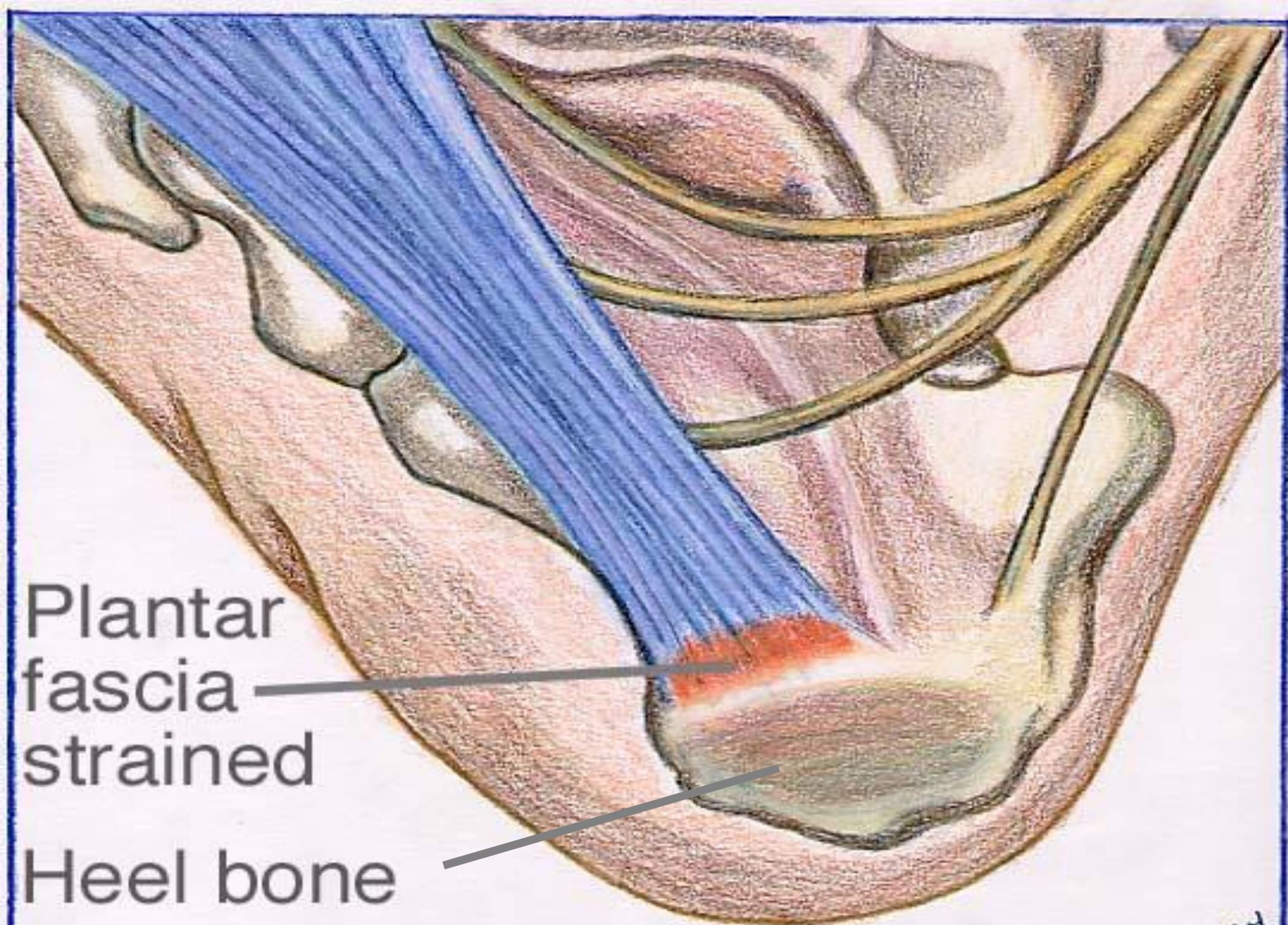
Note collapse of entire foot inward



Note low medial arch height

Plantar Fasciitis / Heel Spur Syndrome

- Inflammation and partial tearing of a ligament band which attaches from the heel to the ball of the foot.
- Usually a result of poor arch support and overuse.
- May be accompanied by a calcified spur on the heel.
- Usually resolves with conservative treatments.



Plantar
fascia
strained

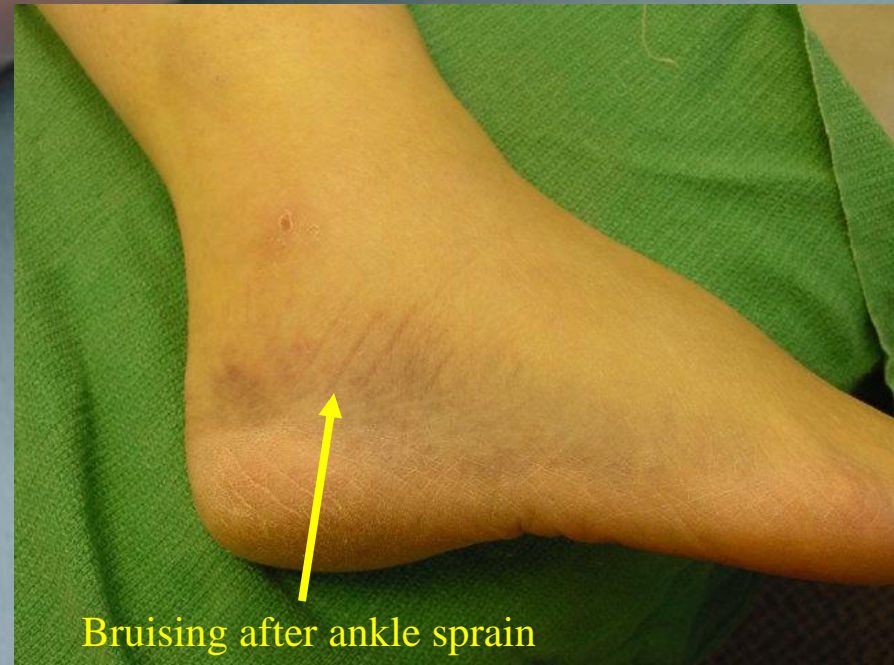Heel bone

Ankle Sprain

- Tear or stretching of the ligaments of the ankle. Usually the ligaments on the outside of the ankle are involved.
- Caused by and twisting injury of the foot / ankle .
- Instability of the ankle can develop due to the ligament injury.
- Most often treated conservatively. Surgical repair can be performed to treat chronic ankle sprains.

Ankle Sprain

(Swelling in area of ligament injury)

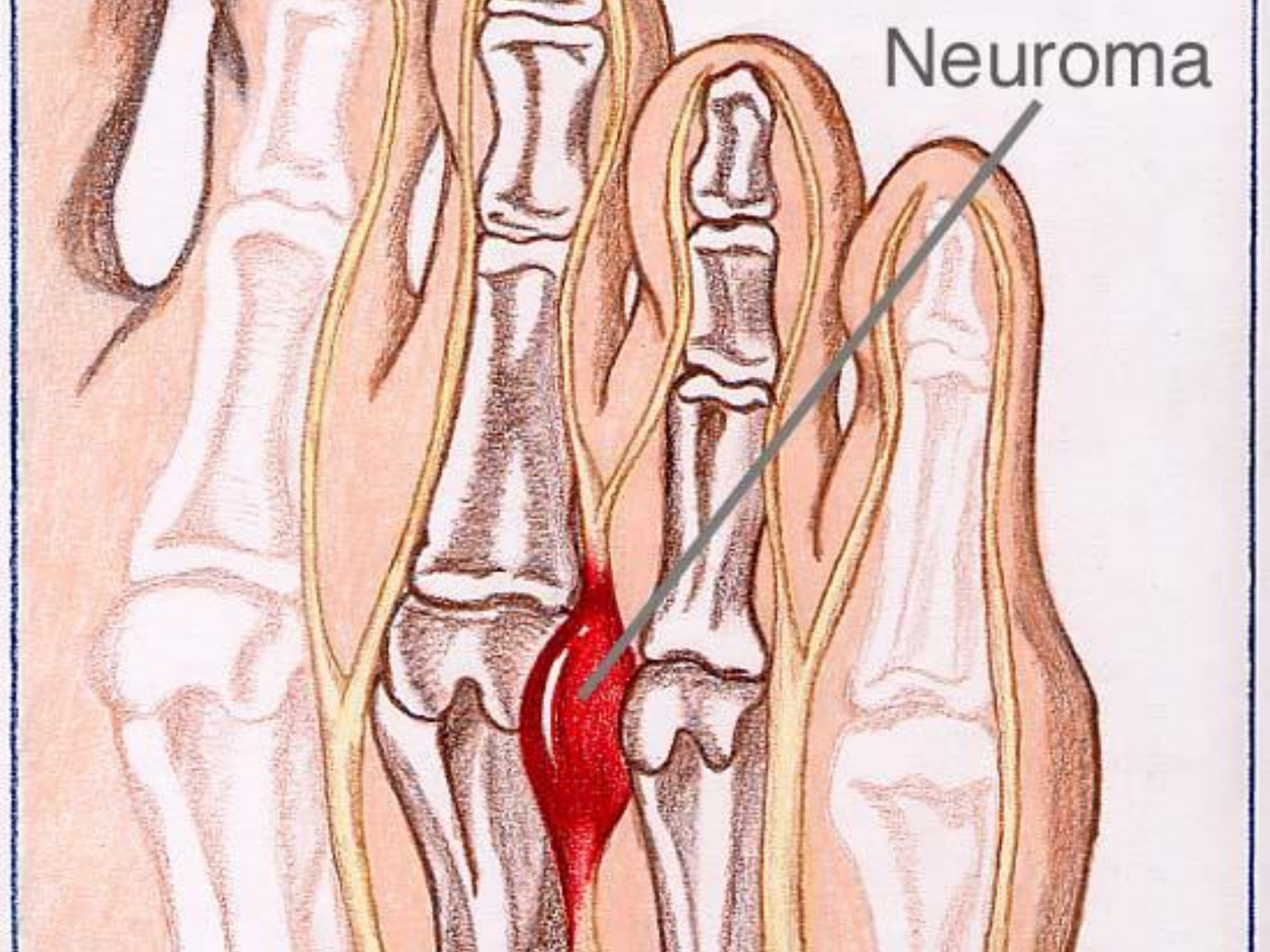


Bruising after ankle sprain

Morton's Neuroma

- Injured or compressed nerve most often between the 3rd and 4th toes.
- Burning / pain on the ball of the foot or toes.
- Patients may feel fullness or a mass in the area when they walk.
- Treatments may be conservative or surgical.

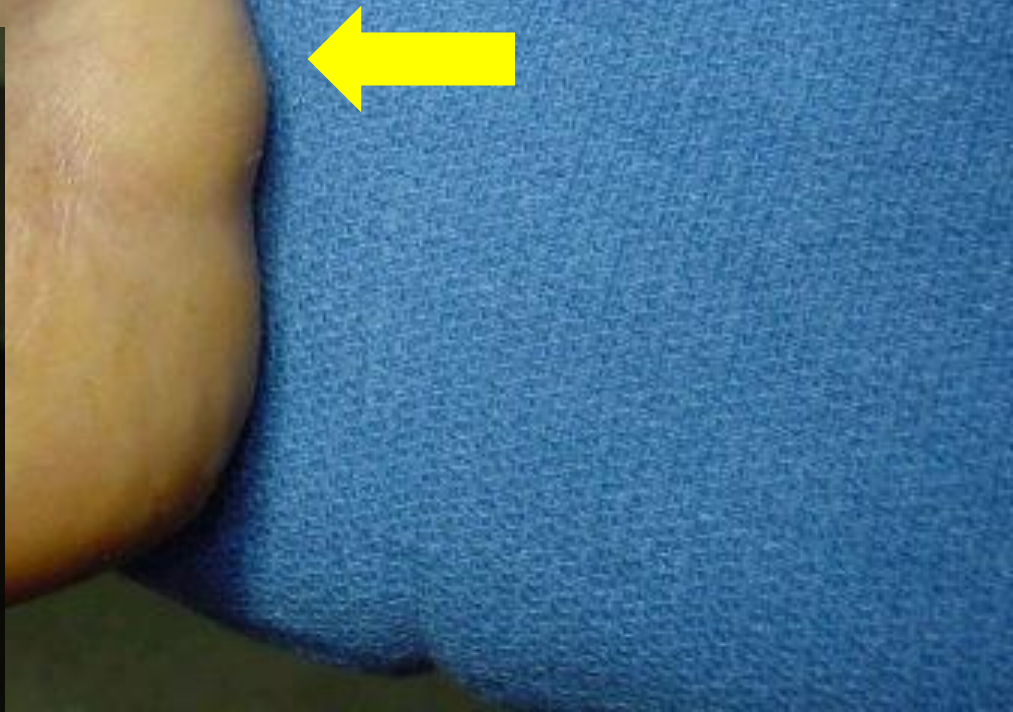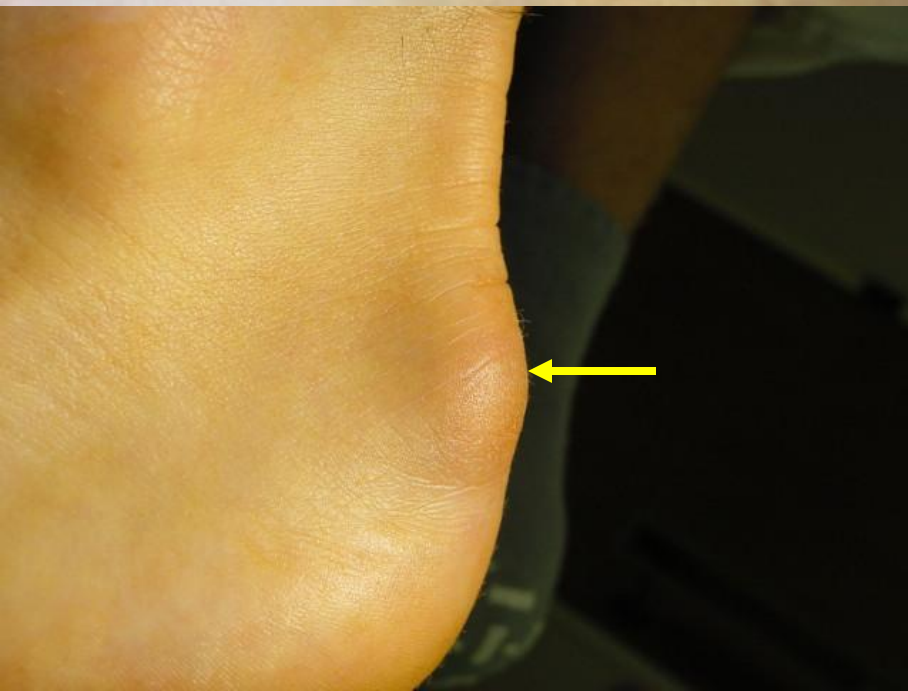Neuroma



Haglund's Deformity / Retrocalcaneal Exostosis

- Prominent bone on the back of the heel.
- Back of the heel is irritated by shoes and activity, which places pressure on the area.
- Can also be aggravated by a tight Achilles tendon over prominent heel bone.
- Treatments may be conservative or surgical.

Haglund's Deformity / Retrocalcaneal Exostosis

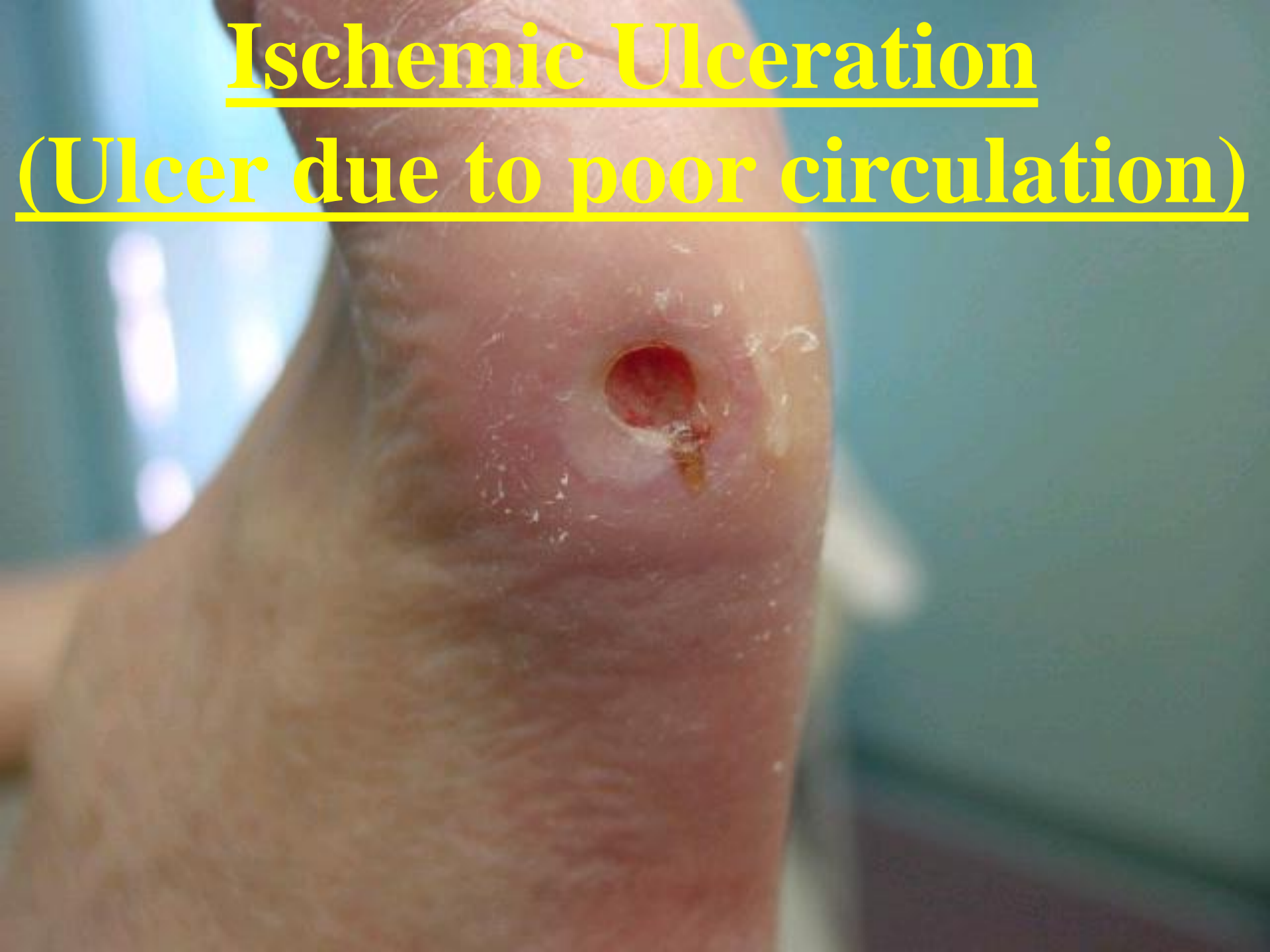

Ulcerations

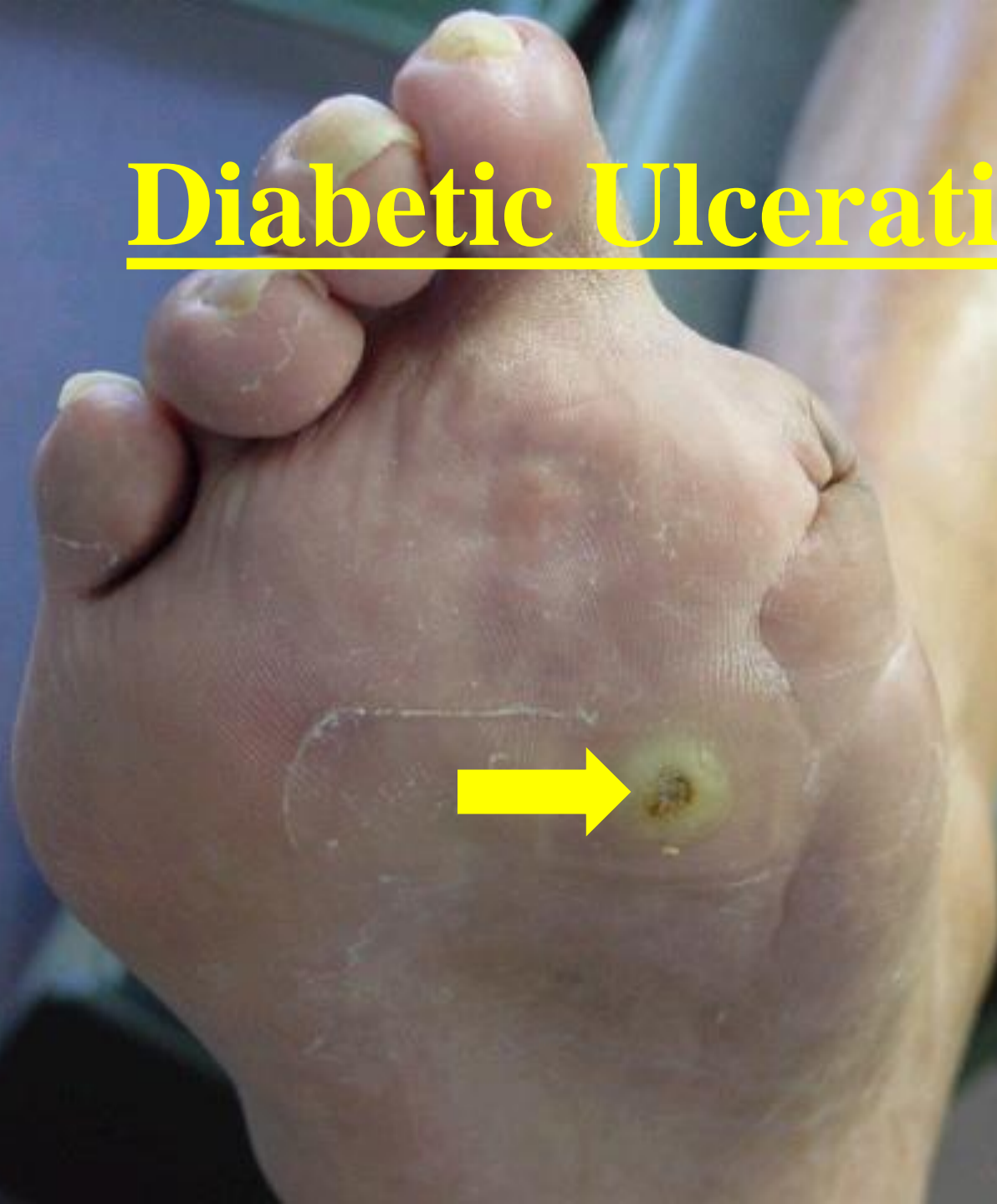
- Erosions of the skin caused by loss of sensation or poor circulation.
- Skin break down occurs which, places patients at risk for local or systemic infection.

Ischemic Ulceration

(Ulcer due to poor circulation)

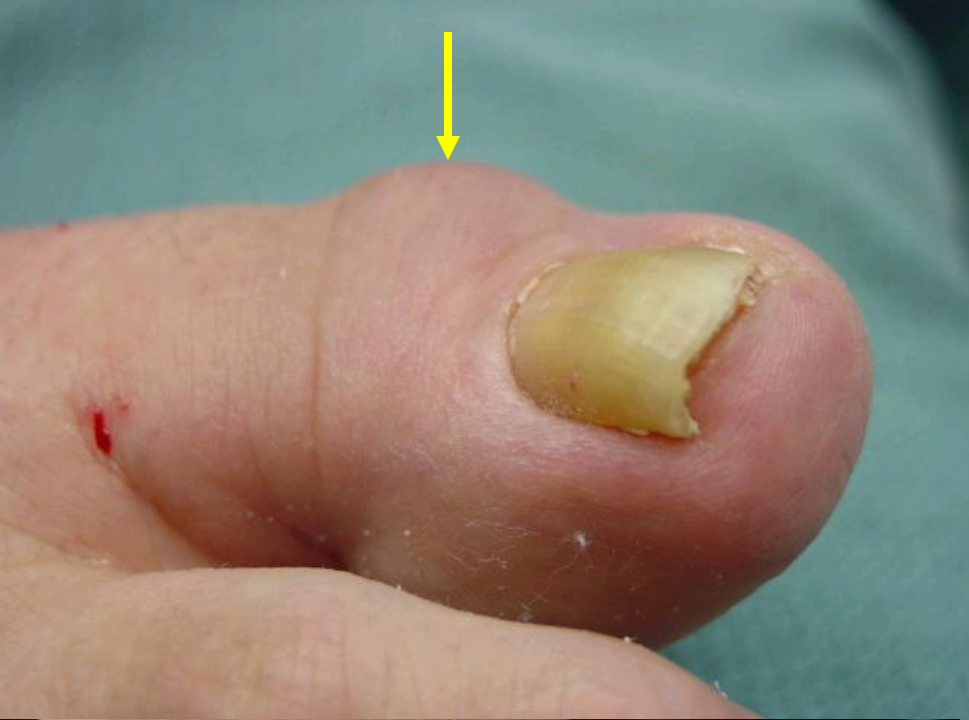

Diabetic Ulceration

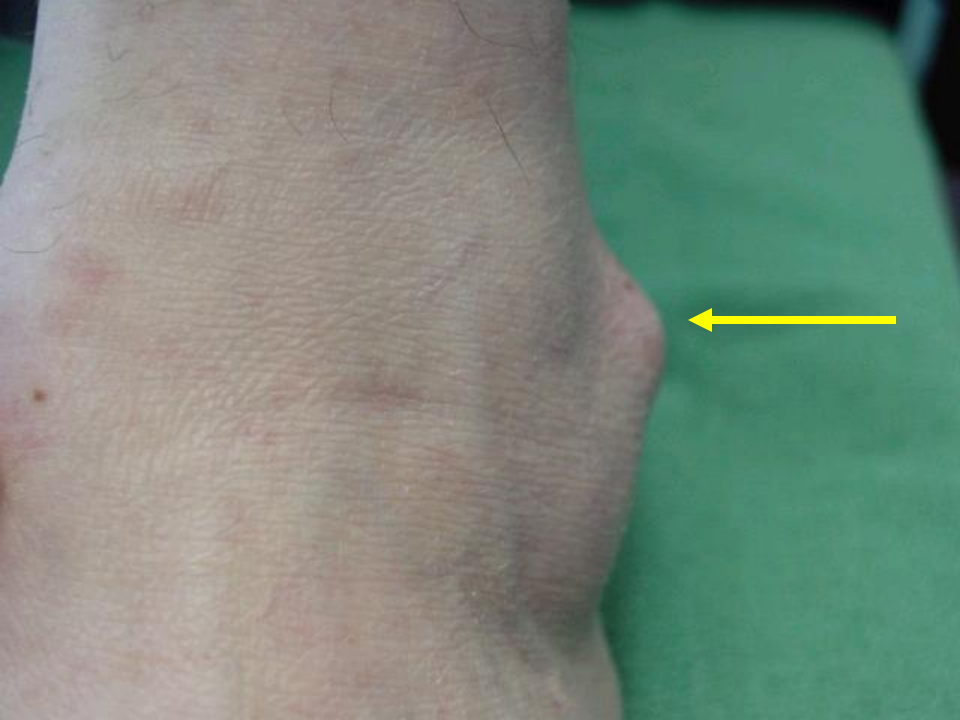

Ganglion Cyst

- Benign soft tissue mass which arises from a weak area in a tendon lining or joint.
- Cyst is often filled with a gelatinous fluid.
- Cyst may change size depending on irritation.



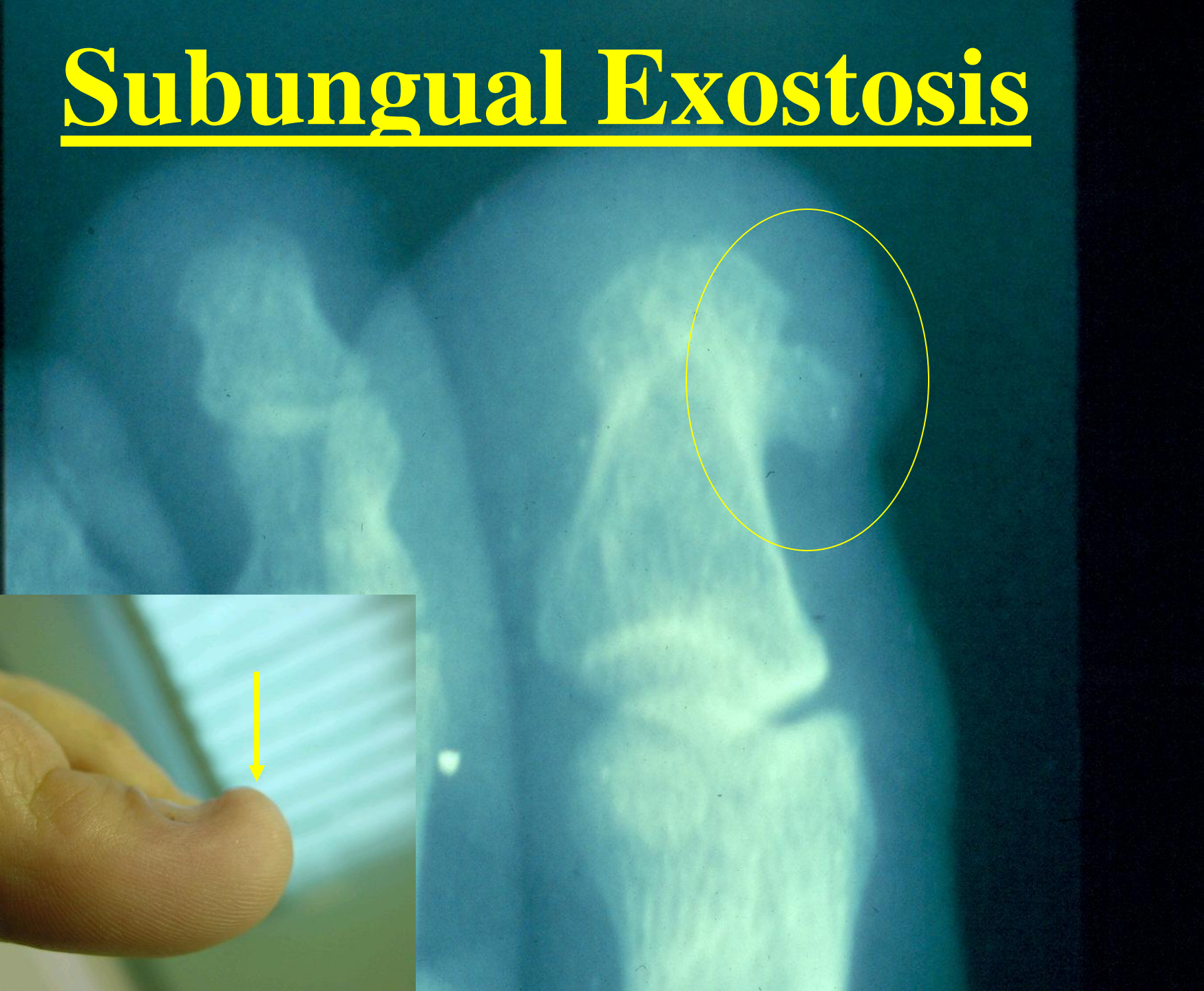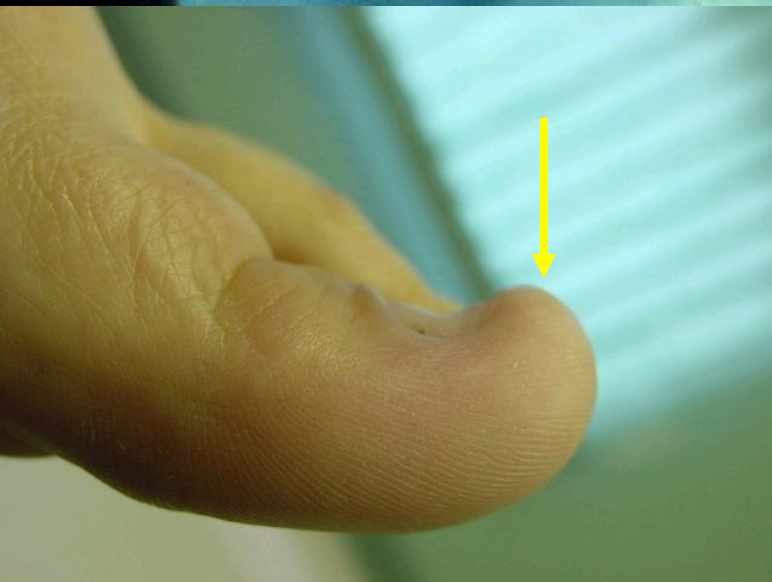Ganglion Cyst



Subungual Exostosis

- Bone and cartilage growth under the great toe nail.
- Pain may arise if pressure is placed over the area.
- May be treated with shoe style changes, nail removal or surgical removal.

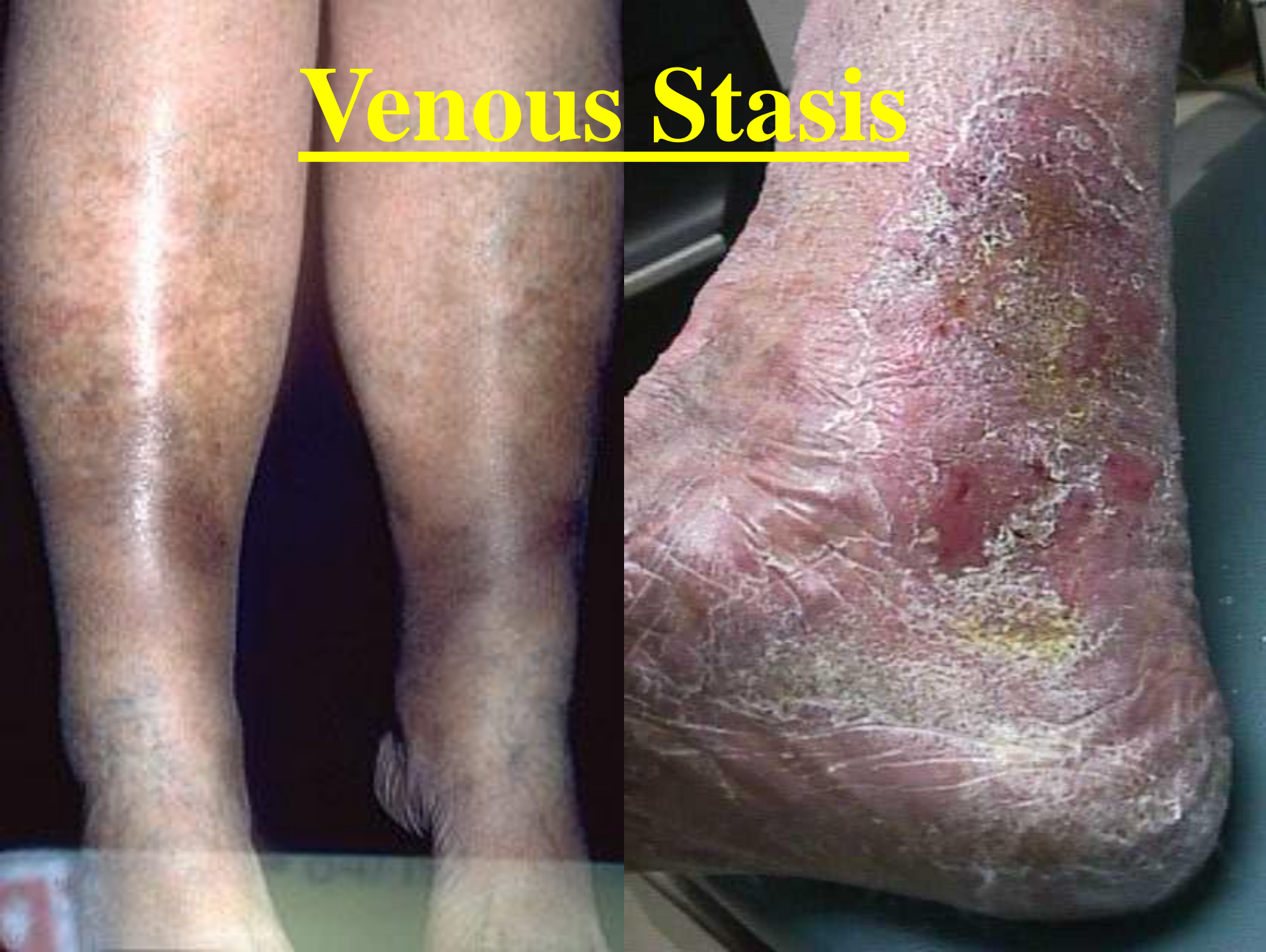Subungual Exostosis



Venous Stasis

- Discoloration of skin due to longstanding swelling of legs.
- Persistent swelling can lead to skin breakdown.
- Compression and elevation of the legs are essential to the prevention of complications.

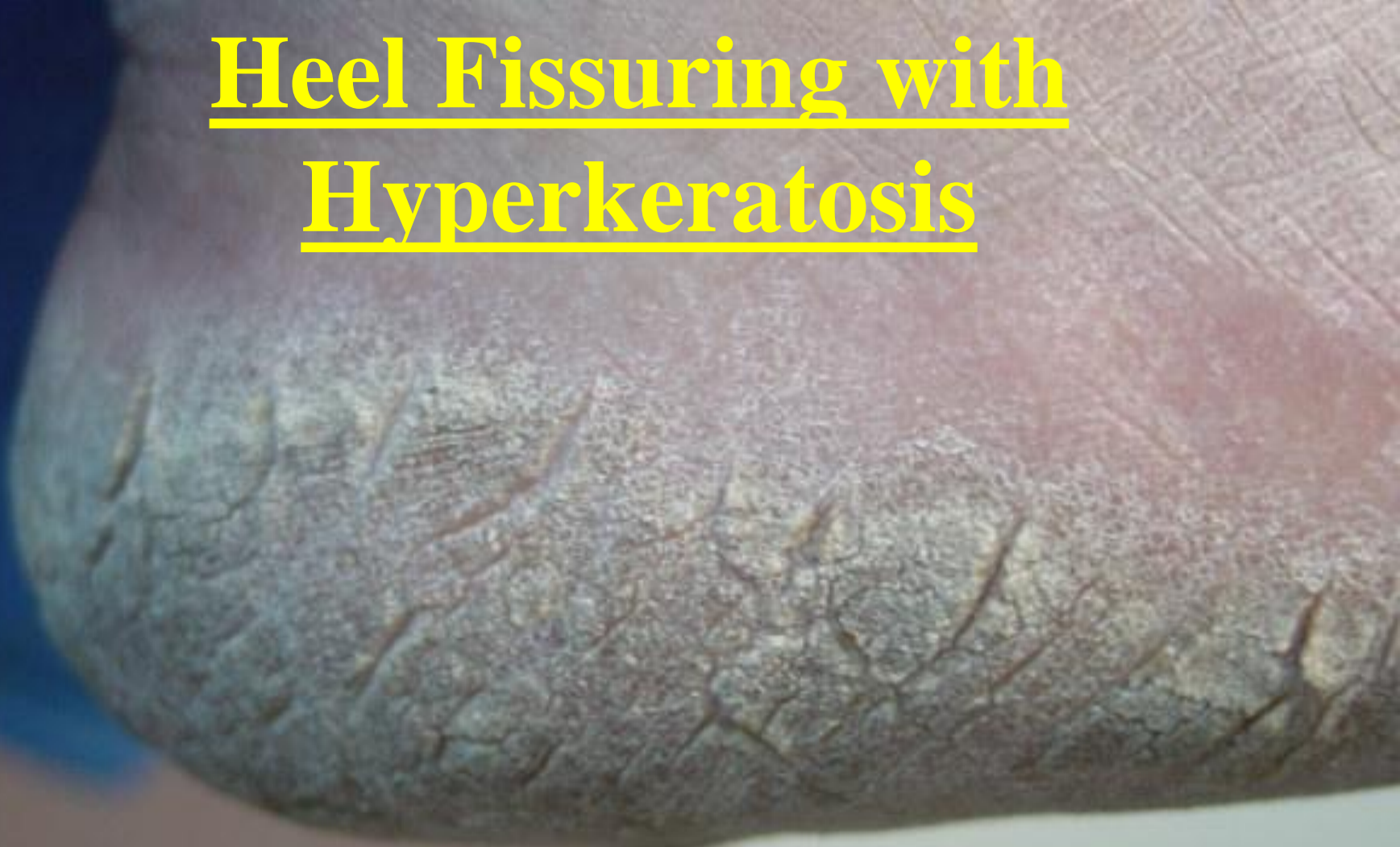Venous Stasis



Heel Fissuring / Cracking

- Thickening of the heel with associated cracking which causes pain.
- Thickening may arise from pressure, a buildup of skin or dermatological condition.
- May be chronic in nature.

Heel Fissuring with Hyperkeratosis

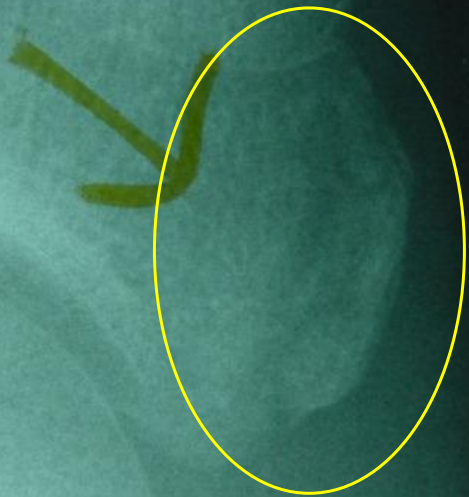


Fractures

Fractured Proximal Phalanx (Toe)




Fractured Heel Bone (Calcaneus)



Navicular Fracture

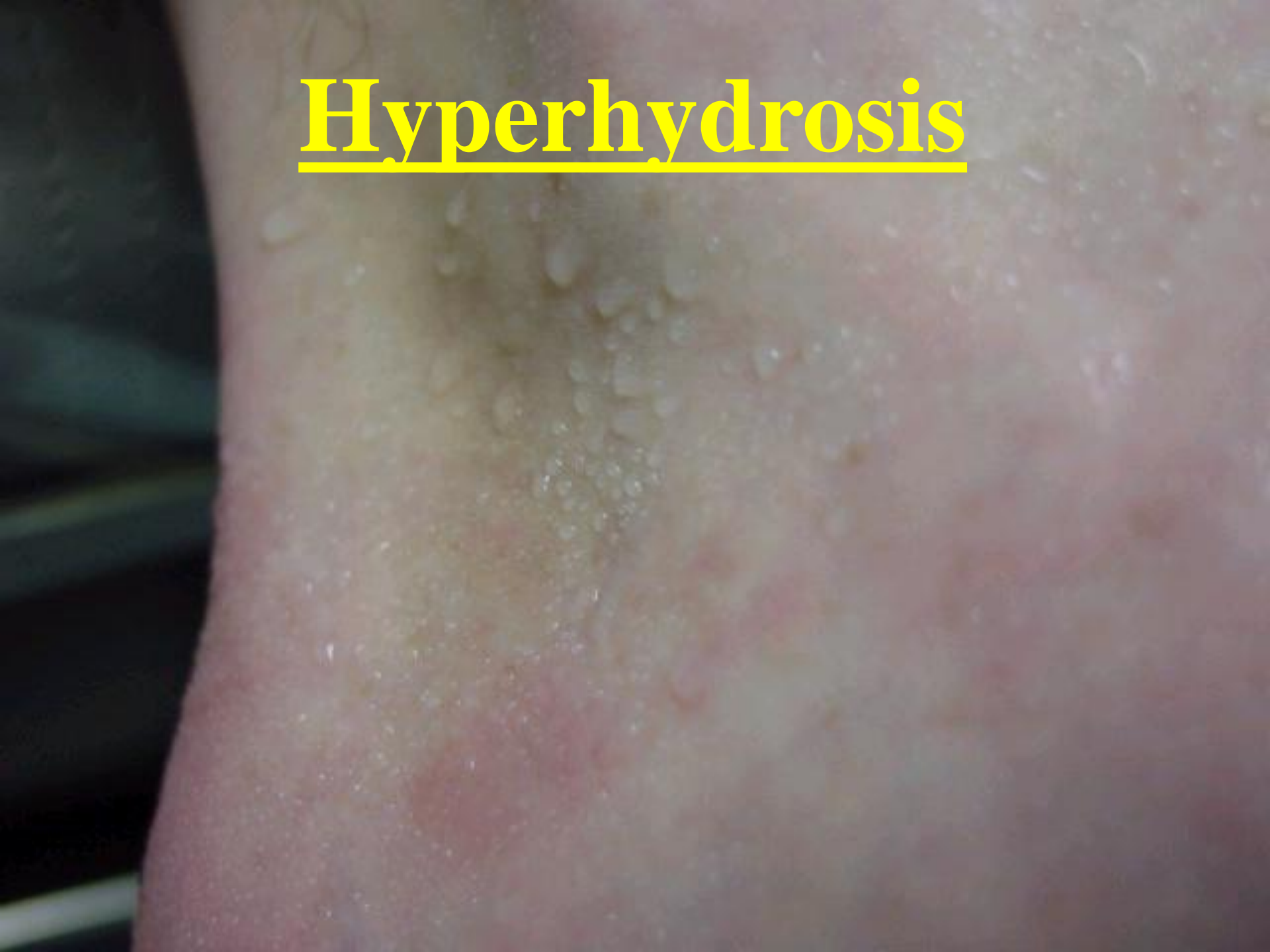Fracture 5th Metatarsal



Hyperhidrosis

- Excess perspiration of the foot.
- May be caused by stress or overactive sweat glands.
- Can often predispose patient to fungal infections, bacterial infections or foot odor.
- Can be treated with topical medications.

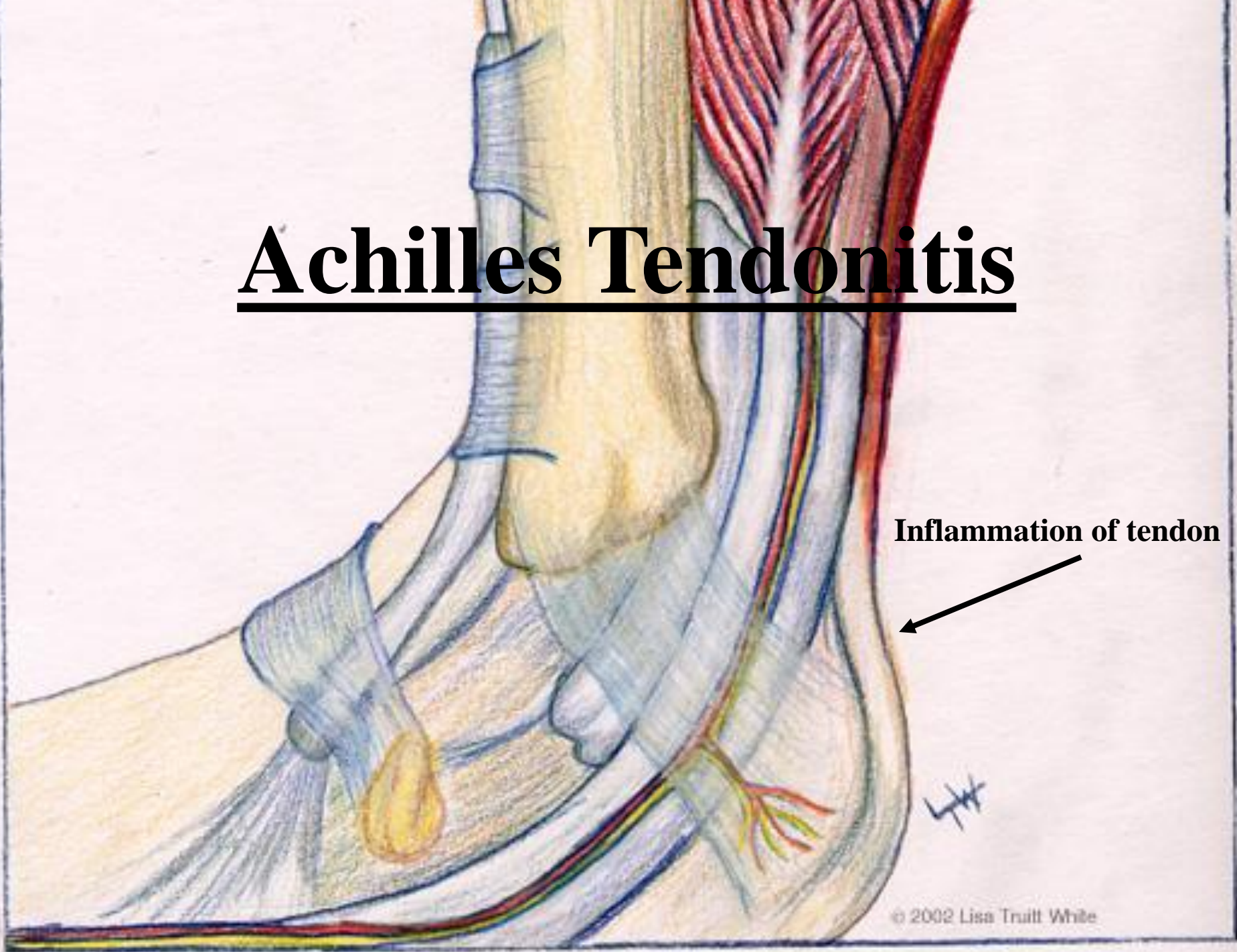
Hyperhydrosis



Achilles Tendonitis

- Inflammation of the tendon which may be caused by over use and/or tightness in the tendon.
- Swelling may occur at the back of the heel.
- May predispose patients to rupture of the tendon.
- Usually resolves with conservative treatments.

Achilles Tendonitis



Inflammation of tendon

Special Thanks To:
Kirk Woelffer, DPM
Lisa Truitt White

Novartis Pharmaceuticals

Willard J. Niemi, DPM, FACFAS