



Acute Management of Pediatric Vascular Injuries

Gilbert Aidinian, MD, FACS, FSVS, RPVI
Vascular and Endovascular Surgery

William Beaumont Army Medical Center

Disclosures

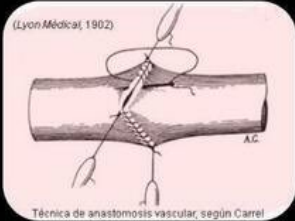

- None relative to this presentation

Origins of Vascular Injury Management

- Alexis Carrel (1902)
 - Popularized Techniques for arterial anastomosis
 - Nobel Prize in Physiology and Medicine in 1912

ALEXIS CARREL M.D.
28 de Junio de 1873

Padre de la cirugía vascular
y de la cirugía de TRASPLANTES

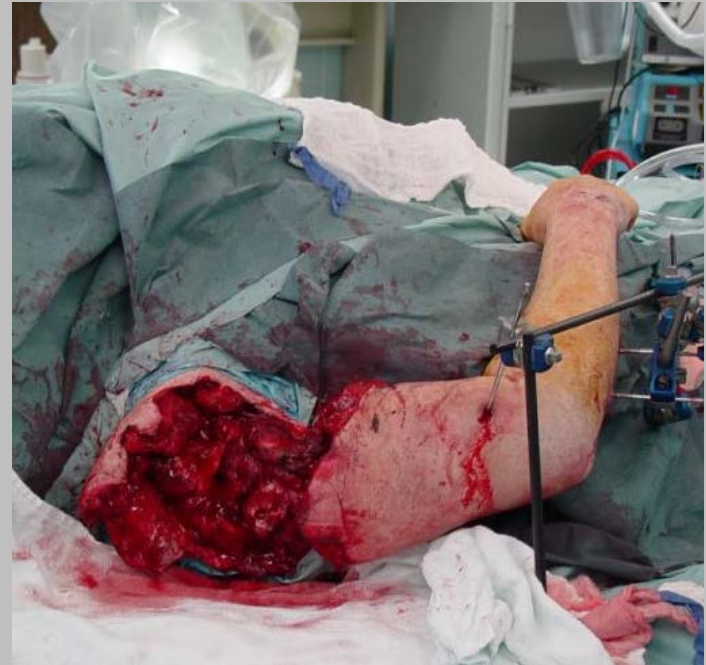
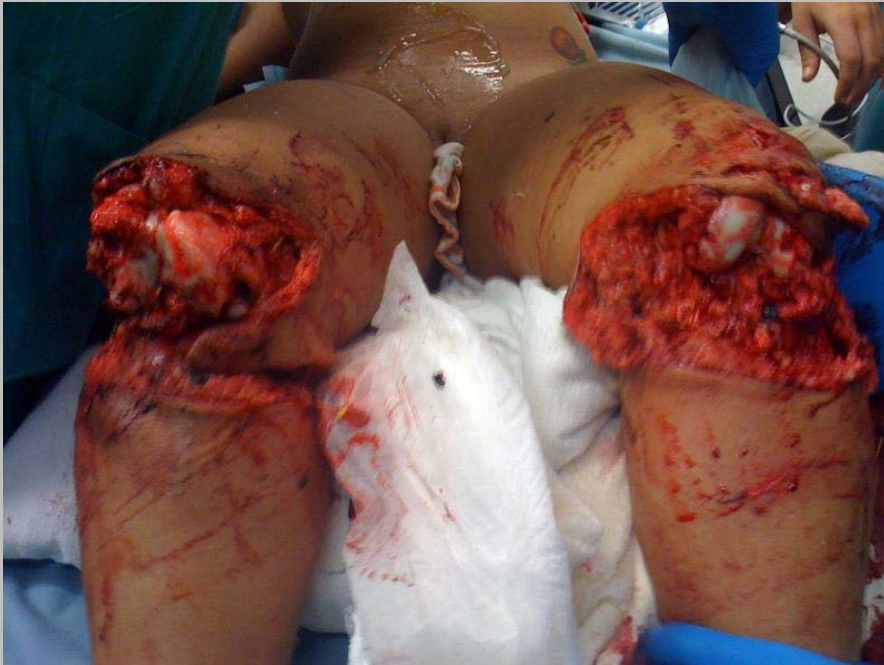
(Lyon Médical, 1902)

"Al great men are gifted with intuition. They know without reasoning or analysis, what they need to know"

Major Vascular Trauma

- Well studied in adult population
- Significant data from military conflicts



Origins of Vascular Injury Management

Evolution Through Military Conflicts

- WWII
 - Repair only minor injuries
 - Routinely ligated
 - Popliteal artery injury – 73% amputation
- Korea
 - Formal repair advocated
 - Repair with lateral suture or anastomosis
- Vietnam
 - Vascular repair with vein graft, vein repair
 - Popliteal artery injury – 32% amputation
- GWOT
 - Vascular repair with vein graft, vein repair, damage control, and shunts
 - Amputation rates ~ 5 – 15%



Modern Day Trauma

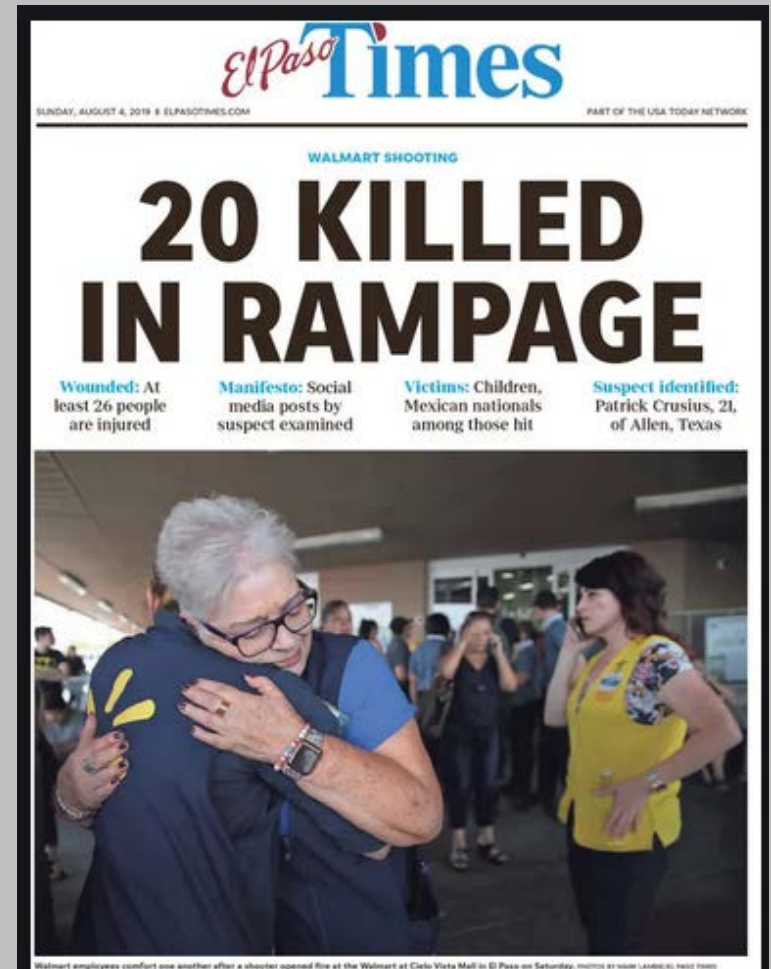- Trauma (United States)
 - Leading cause of death
 - Leading cause of death in children older than 2
- More males younger than 18 years die from handgun injuries than MVAs, drugs or disease
- Survivors are frequently incapacitated



Civilian Vascular Injury

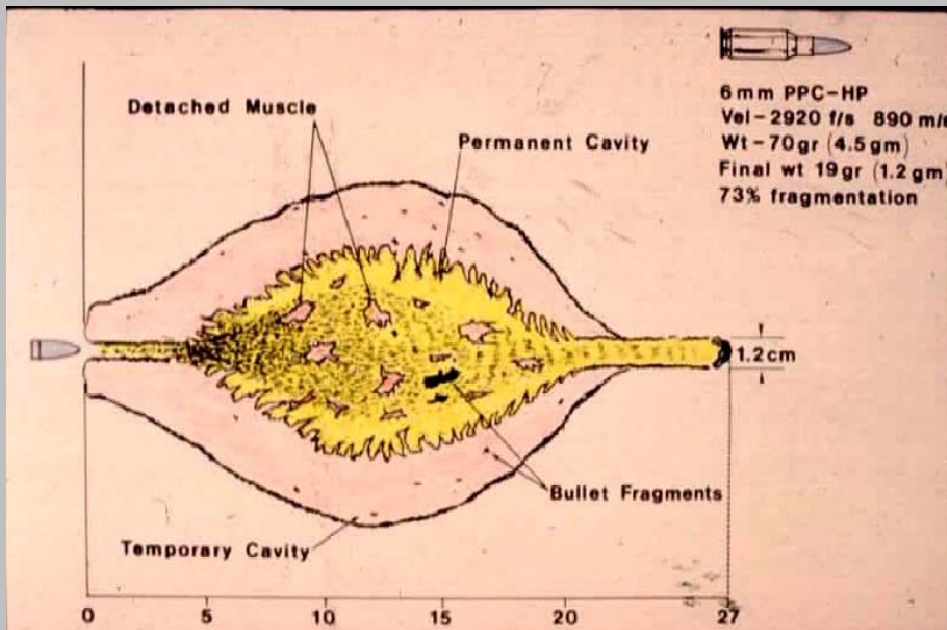
Violence In Society

- Homicide rates are loosely linked to the incidence of vascular injury
- In US, gun violence is the principal agent of death in 60% of cases
 - High-velocity penetrating trauma is increasing



High Velocity Missiles

- Widespread damage
- Cavitation effect
 - Vessels damaged remote from the wound tract



- As the blast cavity collapses, suction effect draws structures into the wound
- Significant soft tissue damage
- Destructive effect may not be suspected on initial inspection

Pediatric Vascular Injuries

Background

- Incidence (NTDB analysis)
 - 0.6% to 1.4% of all pediatric injuries
 - Likely underestimated
 - Does not include patients who died at the trauma scene
 - Does not include iatrogenic injuries
 - Traumatic injury progressively increases at age 14, peaking at age 21
- Leading cause of mortality in ages 2 to 18 years
 - 13.2% in-hospital mortality rate
 - 2.4% mortality at the time of presentation to the ED
 - Highest mortality (18.2%) in infants with chest vascular injuries

Pediatric Vascular Injuries

Background

- Challenging to diagnose and treat
 - More difficult to diagnose
 - Asymptomatic
 - Have more severe life-threatening injuries that take priority
 - Technically challenging to treat
 - Small caliber vessels
 - Associated with vasospasm
 - Considerations for ongoing axial growth

Pediatric Vascular Injuries

Etiology

- Iatrogenic
 - Most common (33% - 100%)
 - Misadventures of arterial and venous catheterization
 - ECMO cannulation injuries (20% - 52%)
 - » Both femoral and carotid sites

<u>Age (years)</u>	<u>Frequency (%)</u>
Neonates	Highest frequency
2-6	50
Over 6	33

Pediatric Vascular Injuries

Etiology

- Iatrogenic
 - Factors associated increased risk of iatrogenic femoral complications
 - Age younger than 3
 - Type of therapeutic intervention
 - ≥ 3 earlier catheterization
 - $\geq 6\text{Fr}$ or larger catheters

Pediatric Vascular Injuries

Etiology

- Non-iatrogenic
 - 2/3 of injuries for over age 6 years

MVA	24.3%
Firearm	19.6%
Stab wounds	16.6%
Falls	11.8%

Pediatric Vascular Injury

Anatomic Location

- Upper extremity
 - Most common location (37%)
 - Brachial artery injuries
 - Highest amputation rate
 - Blunt
 - Most commonly combined with orthopedic trauma
 - Supracondylar fracture
 - 10% brachial artery injury
 - Can result in amputation/Volkman Ischemic contracture
 - Explore/repair brachial artery if no return of pulses after orthopedic repair

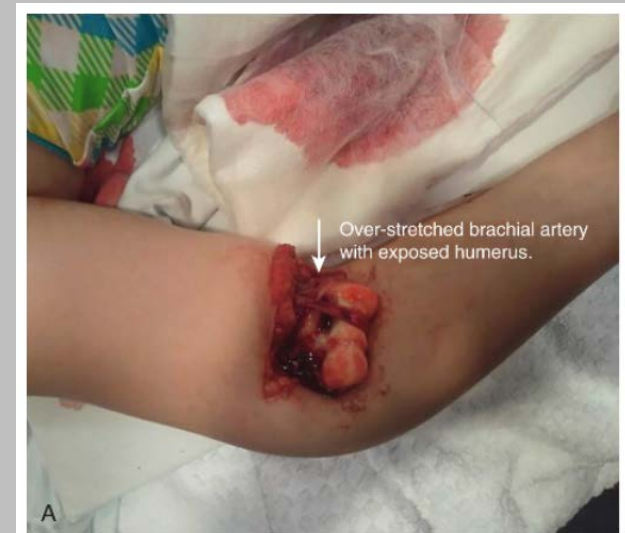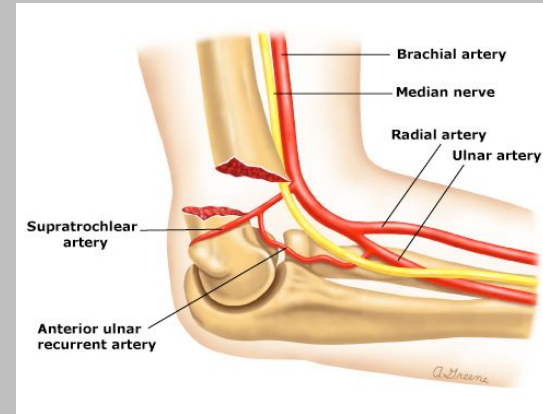
TABLE 1. Injuries by Location in All Patients (Survivors and Nonsurvivors)

Vessel	Arterial Injuries	Vessel	Venous Injuries
Head/neck	8		2
Common carotid artery	4	Internal jugular vein	2
Internal carotid artery	4		
Torso	30		16
Aorta	12	Vena cava	12
Iliac artery	5	Hepatic vein	2
Renal artery	3	Iliac vein	1
Innominate artery	2	Superior mesenteric vein	1
Epigastric artery	1		
Hepatic artery	1		
Hypogastric artery	1		
Ileal mesenteric artery	1		
Internal mammary artery	1		
Superior mesenteric artery	1		
Splenic artery	1		
Subclavian artery	1		
Lower extremity	28		8
Femoral artery	10	Popliteal vein	5
Posterior tibial artery	8	Femoral vein	3
Popliteal artery	7		
Anterior tibial artery	2		
Peroneal artery	1		
Upper extremity	45		1
Brachial artery	16	Brachial vein	1
Ulnar artery	16		
Radial artery	12		
Axillary artery	1		
Total	111		27

Pediatric Vascular Injury

Anatomic Location

- Upper extremity
 - Most common location (37%)
 - Brachial artery injuries
 - Highest amputation rate
 - Blunt
 - Most commonly combined with orthopedic trauma
 - Supracondylar fracture
 - 10% brachial artery injury
 - Can result in amputation/Volkman Ischemic contracture
 - Explore/repair brachial artery if no return of pulses after orthopedic repair



Pediatric Vascular Injury

Anatomic Location

- Truncal (30%)
 - Blunt (53%), penetrating (47%)
 - Highest mortality rate (16% - 41%)
 - Chest 41%, abdomen 25%
 - Higher than all other regions combined
 - Have concomitant significant organ injuries
 - Significantly higher ISS (45.4 ± 19.8)
 - Aorta (26%)
 - 50% mortality
 - IVC (26%)
 - 67% mortality

TABLE 1. Injuries by Location in All Patients (Survivors and Nonsurvivors)

Vessel	Arterial Injuries	Vessel	Venous Injuries
Head/neck	8		2
Common carotid artery	4	Internal jugular vein	2
Internal carotid artery	4		
Torso	30		16
Aorta	12	Vena cava	12
Iliac artery	5	Hepatic vein	2
Renal artery	3	Iliac vein	1
Innominate artery	2	Superior mesenteric vein	1
Epigastric artery	1		
Hepatic artery	1		
Hypogastric artery	1		
Ileal mesenteric artery	1		
Internal mammary artery	1		
Superior mesenteric artery	1		
Splenic artery	1		
Subclavian artery	1		
Lower extremity	28		8
Femoral artery	10	Popliteal vein	5
Posterior tibial artery	8	Femoral vein	3
Popliteal artery	7		
Anterior tibial artery	2		
Peroneal artery	1		
Upper extremity	45		1
Brachial artery	16	Brachial vein	1
Ulnar artery	16		
Radial artery	12		
Axillary artery	1		
Total	111		27

Pediatric Vascular Injury

Anatomic Location

- Lower extremity
 - 25% of injuries
 - Femoral artery (28%)
 - Popliteal artery (19%)
 - Highest amputation rate
 - Popliteal vein most commonly injured vein (63%)
 - No deaths

TABLE 1. Injuries by Location in All Patients (Survivors and Nonsurvivors)

Vessel	Arterial Injuries	Vessel	Venous Injuries
Head/neck	8		2
Common carotid artery	4	Internal jugular vein	2
Internal carotid artery	4		
Torso	30		16
Aorta	12	Vena cava	12
Iliac artery	5	Hepatic vein	2
Renal artery	3	Iliac vein	1
Innominate artery	2	Superior mesenteric vein	1
Epigastric artery	1		
Hepatic artery	1		
Hypogastric artery	1		
Ileal mesenteric artery	1		
Internal mammary artery	1		
Superior mesenteric artery	1		
Splenic artery	1		
Subclavian artery	1		
Lower extremity	28		8
Femoral artery	10	Popliteal vein	5
Posterior tibial artery	8	Femoral vein	3
Popliteal artery	7		
Anterior tibial artery	2		
Peroneal artery	1		
Upper extremity	45		1
Brachial artery	16	Brachial vein	1
Ulnar artery	16		
Radial artery	12		
Axillary artery	1		
Total	111		27

General Principles of Management

Diagnostic Evaluation

TYPE OF INJURY	CLINICAL PRESENTATION
Partial laceration	Decreased pulse, hematoma, hemorrhage
Transection	Absent distal pulses, ischemia
Contusion	Initially, examination may be normal; may progress to thrombosis
Pseudoaneurysm	Initially, examination may be normal; bruit or thrill, decreased pulses
AV fistula	Same as pseudoaneurysm
External compression	Decreased pulses; normal pulses when fracture aligned

- Prompt treatment in order to optimize outcomes
- Destruction of surrounding soft tissue
- Look for hard signs

General Principles of Management

Diagnostic Evaluation

Signs of Traumatic Vascular Injury

HARD SIGNS

- Observed pulsatile bleeding
- Arterial thrill by manual palpation
- Bruit auscultated over or near an area of arterial injury
- Absent distal pulse
- Visible expanding hematoma

SOFT SIGNS

- Significant hemorrhage by history
- Neurologic abnormality
- Diminished pulse compared with contralateral extremity
- Proximity of bony injury or penetrating wound

General Principles of Management

Associated Orthopedic Injuries

Table 151-3 -- Orthopedic Injuries Commonly Associated with Vascular Trauma

Orthopedic Injury	Arterial Injury
Supracondylar fracture of the humerus	Brachial artery
Clavicular, first rib fracture	Subclavian artery
Shoulder dislocation	Axillary artery
Elbow dislocation	Brachial artery
Distal femur fracture	Superficial femoral, popliteal artery
Posterior knee dislocation	Popliteal artery
Proximal tibia fracture	Popliteal artery, distal vessels

General Principles of Management

Diagnostic Evaluation

- Physical Examination
 - Examine contralateral extremity
 - Skin color
 - Capillary refill
 - Pulse exam
 - Consider vasospasm
- In absence of hard signs
 - Address life threatening injuries
 - Resuscitate and warm the child
 - Re-evaluate pulses
 - Avoids unnecessary diagnostic tests/interventions

General Principles of Management

Soft Signs

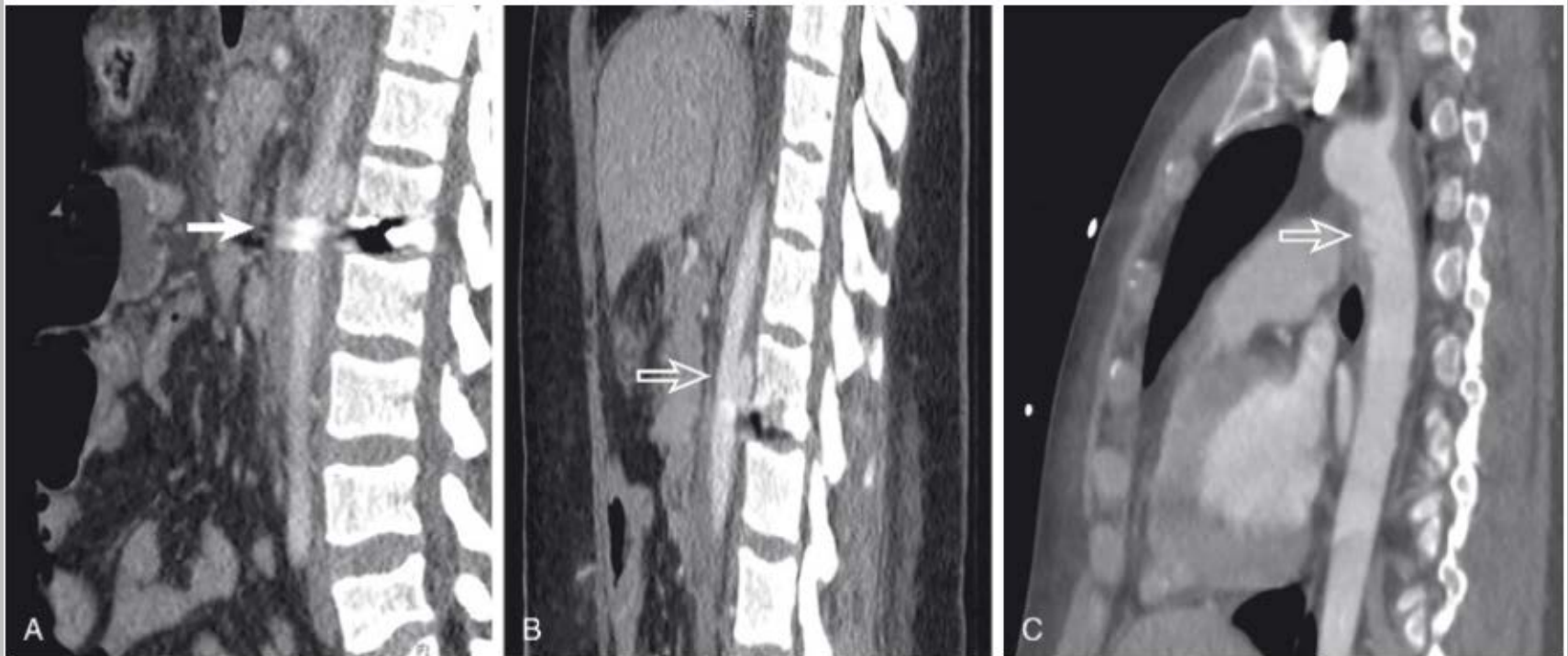- Continuous hand held Doppler examination
- Measure ABI (ankle-brachial index)
 - Not as reliable in younger than 2 years
- Measure IEI (injured extremity index)
 - Concerning for vascular injury when <0.9 in children older than 2 and less than 0.88 in children under 2
- Pulse oximetry on injured extremity
- Duplex ultrasonography
 - Non-invasive
 - Portable
 - Sensitivity ($>95\%$), specificity ($>97\%$)
 - Nearly all major extremity injuries that require therapeutic intervention can be identified

General Principles of Management

Soft Signs

– CT angiography

- Useful for blunt truncal injuries
- Not as useful for extremity arterial injuries in children



General Principles of Management

Soft Signs

- Catheter based angiography
 - Selective cases
 - Most safe in 10 years and older
 - High complication rates in small children
 - Very useful in identifying the location of arterial injury and distinguishing arterial injury from vasospasm

Pediatric Vascular Injuries

Treatment

- Historic treatment
 - Ligation and systemic anticoagulation
 - Loss of axial growth and debilitating gait disturbance
 - Limb overgrowth due to traumatic AVF
 - Amputation
- Gold standard
 - IMMEDIATE restoration of perfusion

Pediatric Vascular Injuries

Medication Considerations

- Unfractionated heparin
 - Safe to use in children (bolus 75 – 100 u/kg)
- Protamine sulfate
 - Safe to use intraoperatively to reverse heparin (1 mg/100 units of heparin)
 - Not typically administered in neonates and young children
- LMWH
 - Anticoagulant agent of choice in preoperative and postoperative pediatric patients
- NOACs
 - Data on use in children is limited and not defined
- Antiplatelet agents (Aspirin/Clopidogrel) safe to use in appropriate doses
 - 30 day course

Pediatric Vascular Injuries

Treatment

- Principles of adult vascular trauma can be translated to the pediatric population
 - Pre-operative antibiotics (include Gram (-) if bony injuries)
 - Fluoroscopy table
 - Prep entire injured extremity AND prep uninjured extremity
 - Systemic heparanization
 - Harvest saphenous vein from uninjured leg
 - Proximal and distal control
 - Evaluate artery, vein, nerve, soft tissue
 - Intravascular temporary shunts
 - Use of appropriately sized embolectomy catheters
 - Liberal use of fasciotomy

Management of Pediatric Vascular Injuries

Treatment

ORIGINAL ARTICLE

Management and outcome of pediatric vascular injuries

Carl-Magnus Wahlgren, MD, PhD and Björn Kragsterman, MD, PhD, Stockholm, Sweden

J Trauma Acute Care Surg Vol 79, Number 4

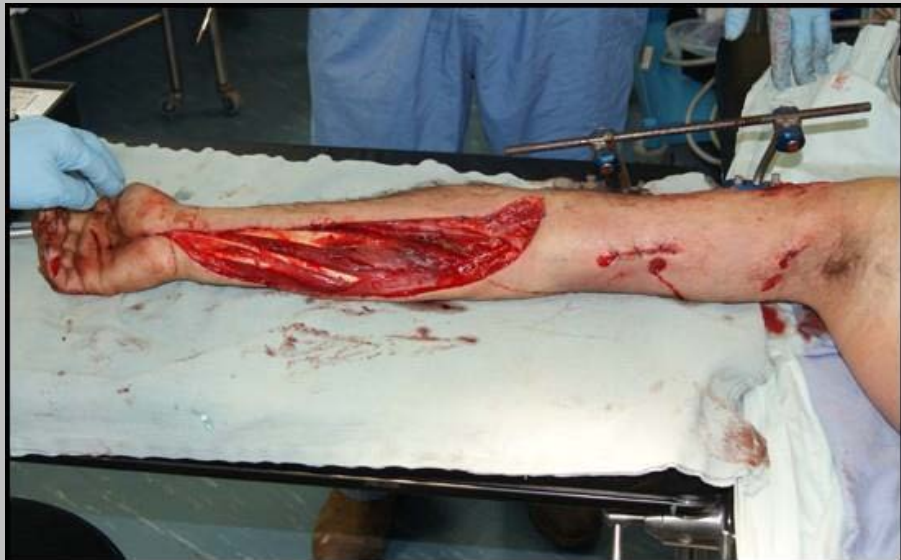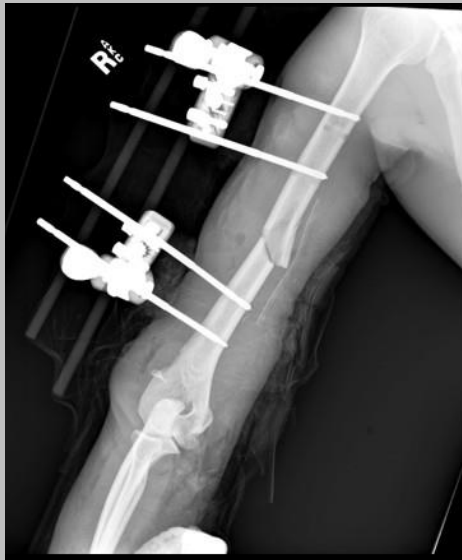TABLE 2. Operative Management of Vascular Injuries

Operative Management (n = 222)	Frequency, n (%)
Interposition graft	54 (24)
Exploration	51 (23)
Patch	43 (19)
Primary repair	27 (12)
Bypass	21 (9.5)
Endovascular	8 (3.7)
Miscellaneous	18 (8.1)

Pediatric Vascular Injuries

Treatment

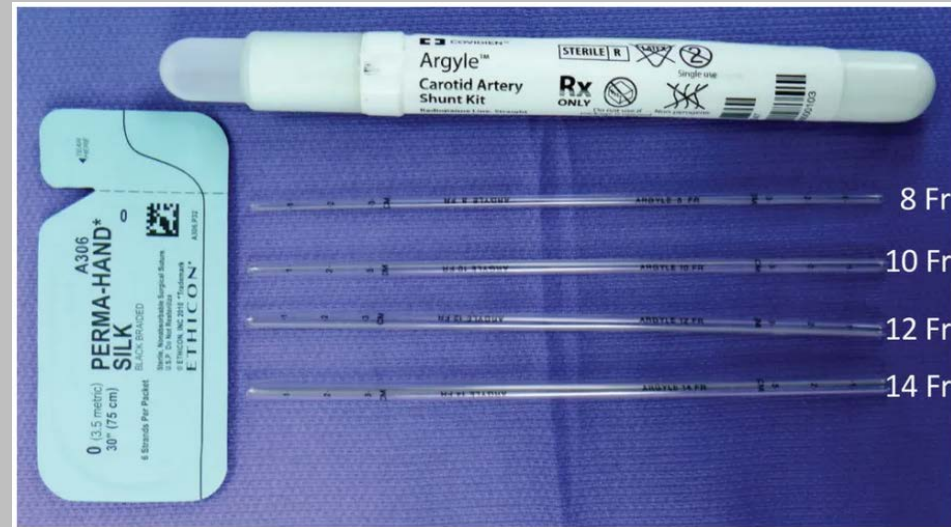- Temporary vascular shunts

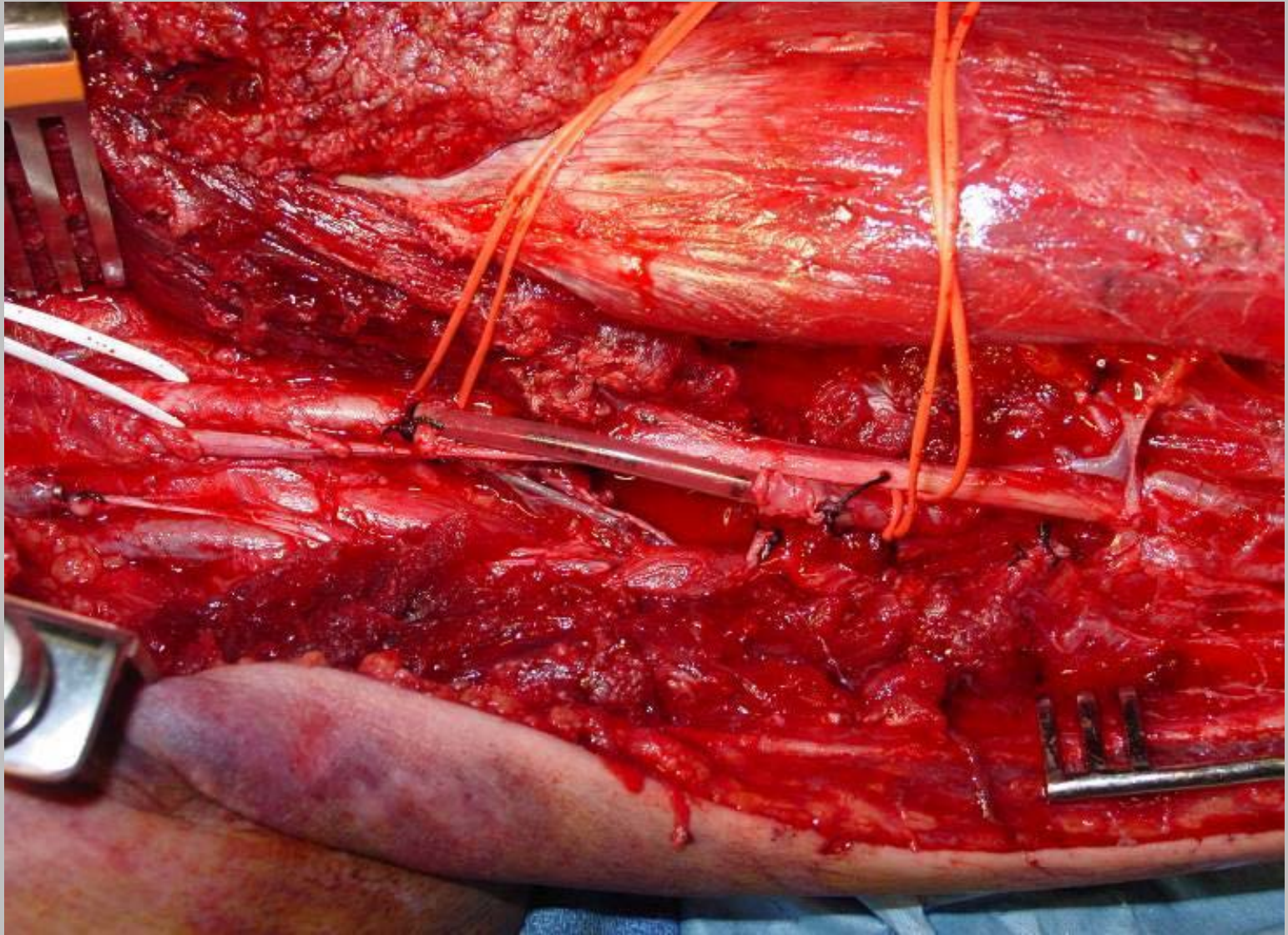


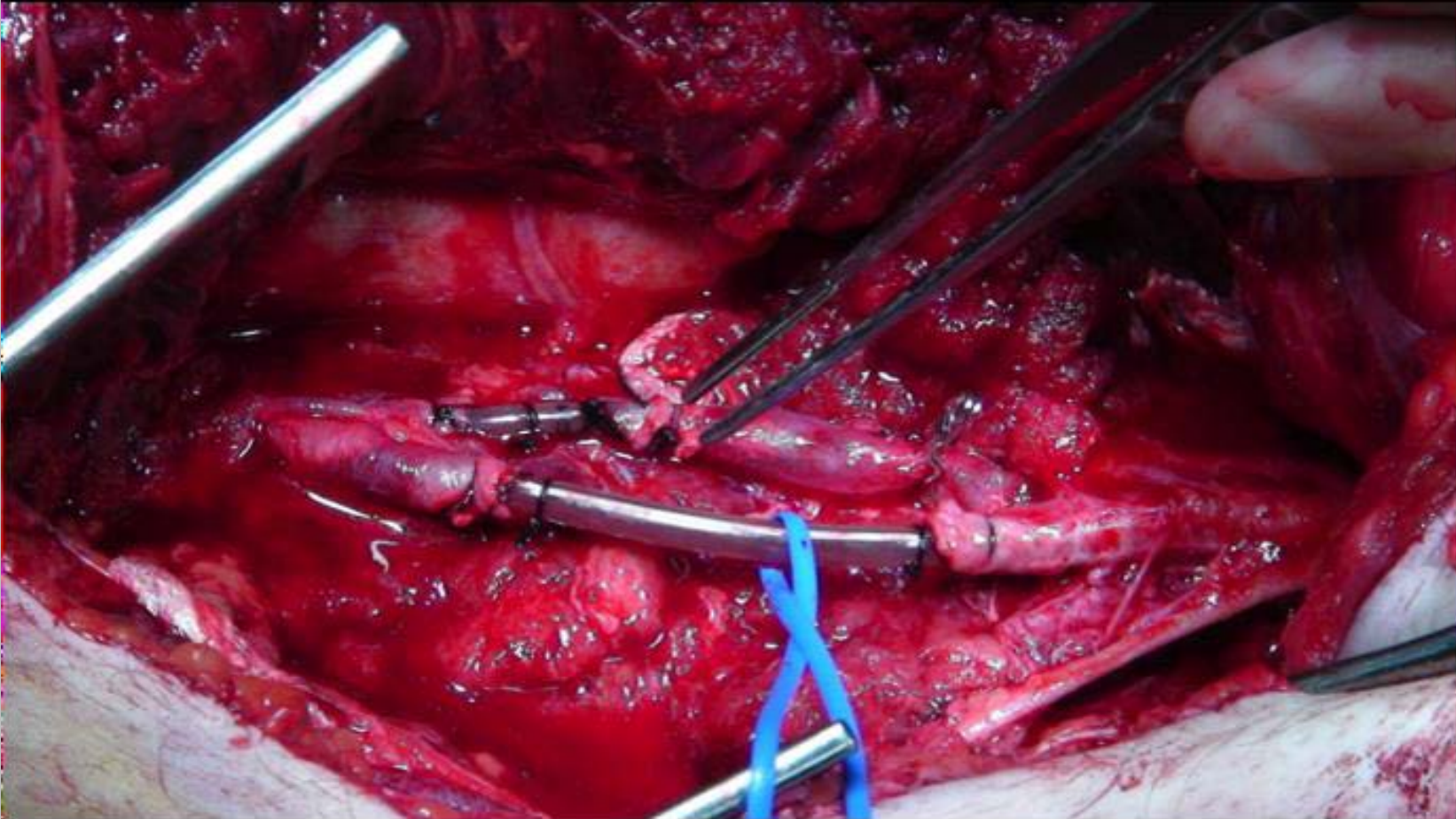
- Reduce ischemia time when revascularization needs to be delayed (damage control surgery)
- Allow fracture fixation, vein repair

How to Place a Shunt

- Obtain proximal and distal control
 - Preferably out of the zone of injury
- Mobilize the artery in both directions
- Resect the injured segment of the artery
- Allow the distal end to back-bleed
 - Perform thrombectomy if necessary
- Flush the proximal artery until pulsatile flow is observed
 - Perform thrombectomy if necessary
- Insert the largest shunt without damaging the normal artery
 - Secure with silk or Rummel Tourniquet
- Confirm patency with continuous wave Doppler



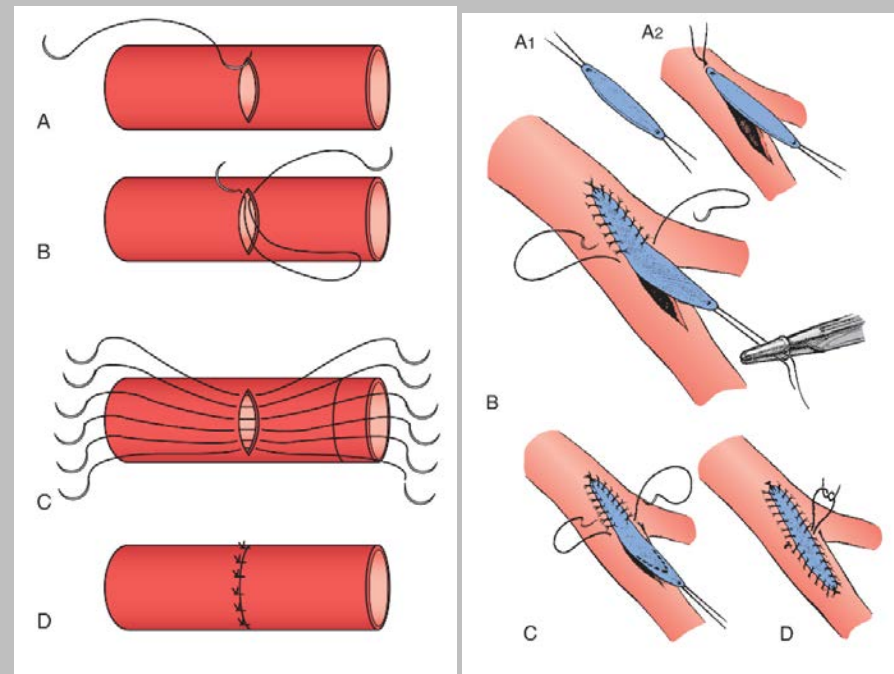


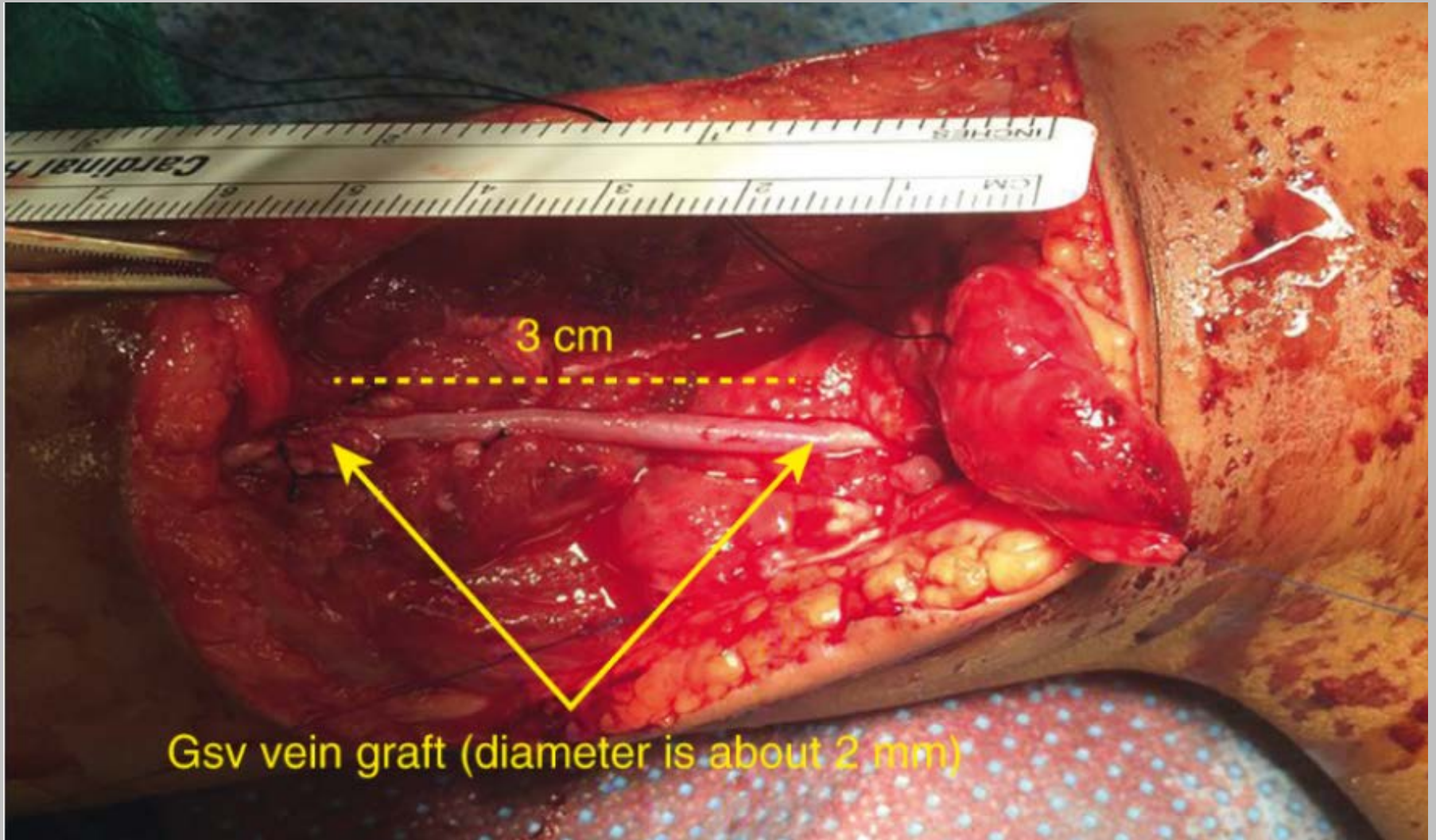


Management of Pediatric Vascular Injuries

Treatment

- Define the extent of the vascular injury
- Accommodate vessel axial growth and luminal expansion
- Intravascular vasodilators
 - Papaverine
- Primary repair
 - Short segment injury
 - Can result in stenosis
 - Interrupted sutures
- Patch repair
 - Avoids luminal growth issues
 - Interrupted sutures
 - Vein patch with non-injured GSV
- Autologous grafts (reversed saphenous vein)
 - When primary repair not feasible
 - GSV is the conduit of choice
 - Prosthetic grafts have higher poor long term patency

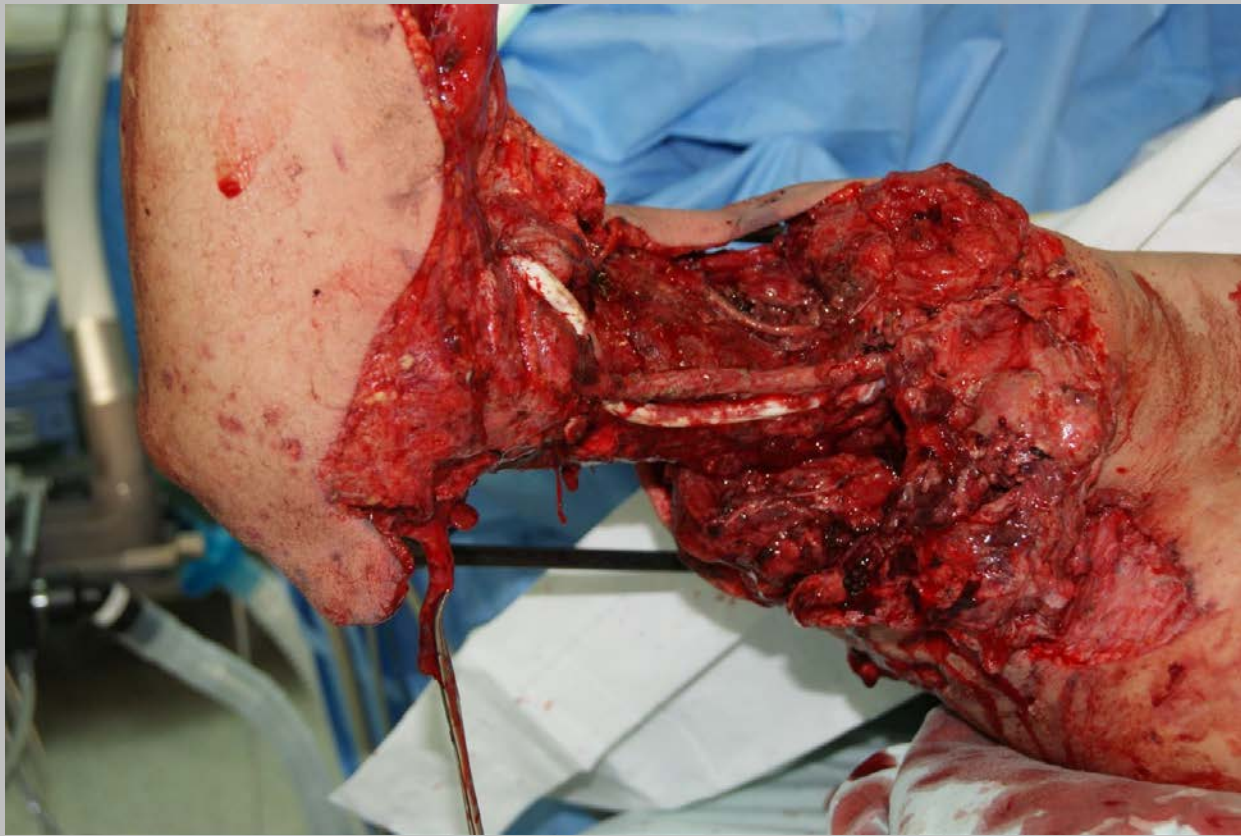



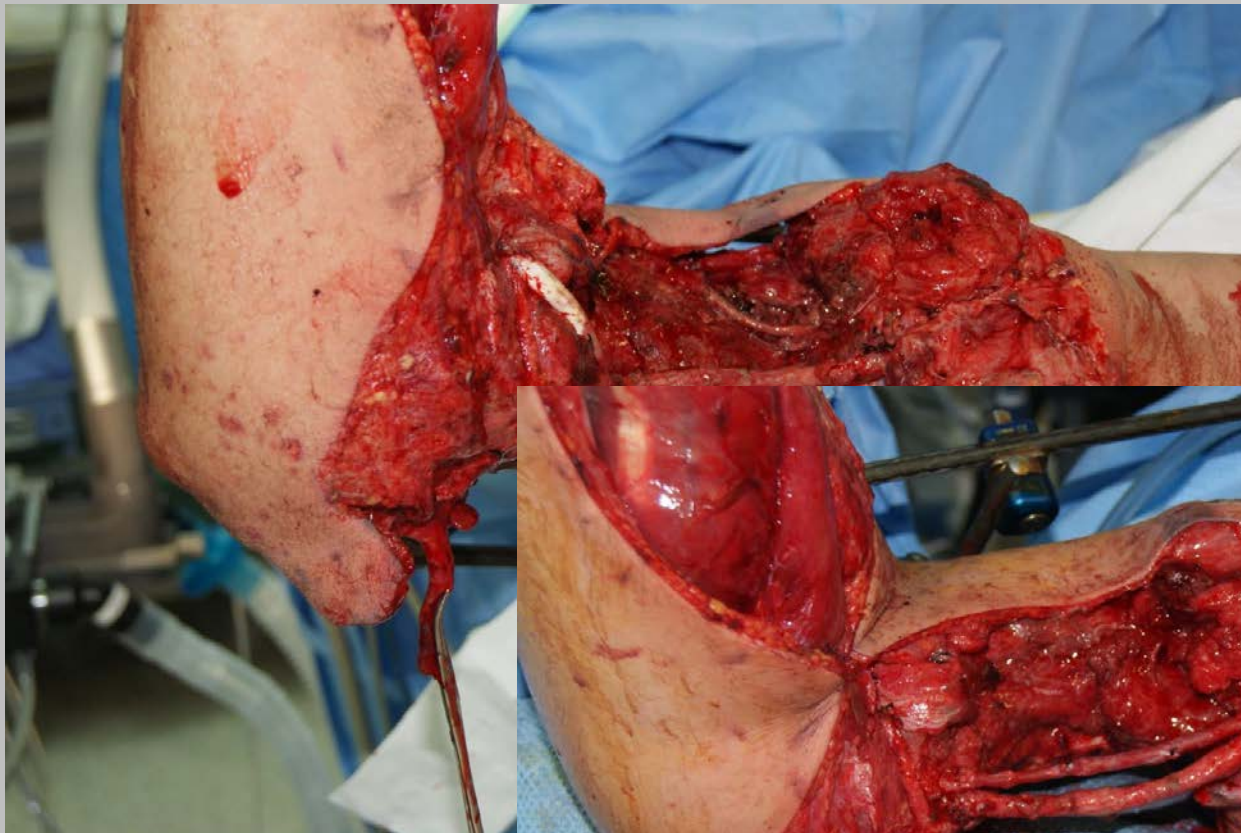
Gsv vein graft (diameter is about 2 mm)

Vascular Repair Rules

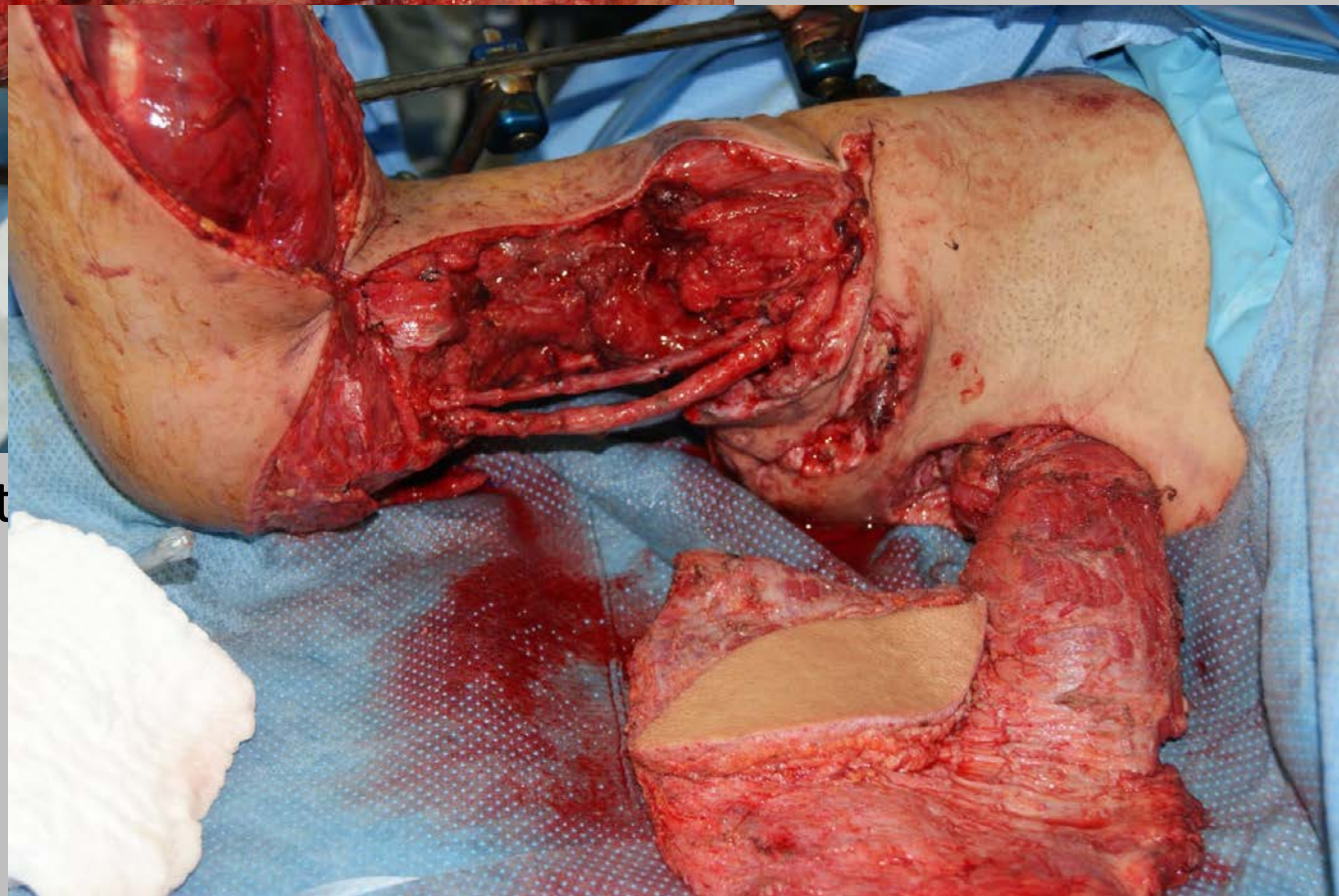
- It is imperative to ensure that vascular repairs are covered with healthy muscle and not left exposed or bathed in devitalized infected tissue.... **EXPOSED GRAFTS WILL BLOW OUT!**



Injury with ePTFE temporary vascular conduit



Injury with ePTFE t

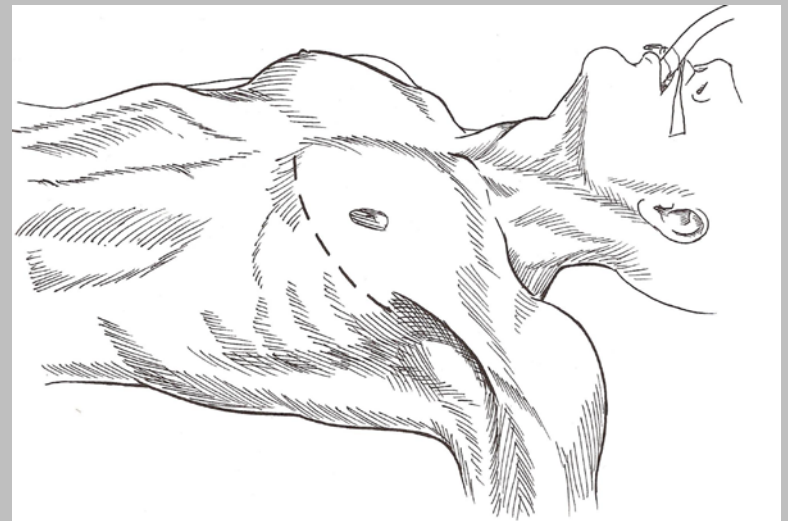
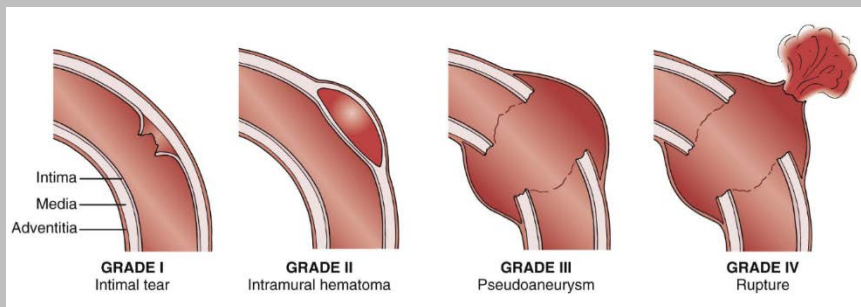
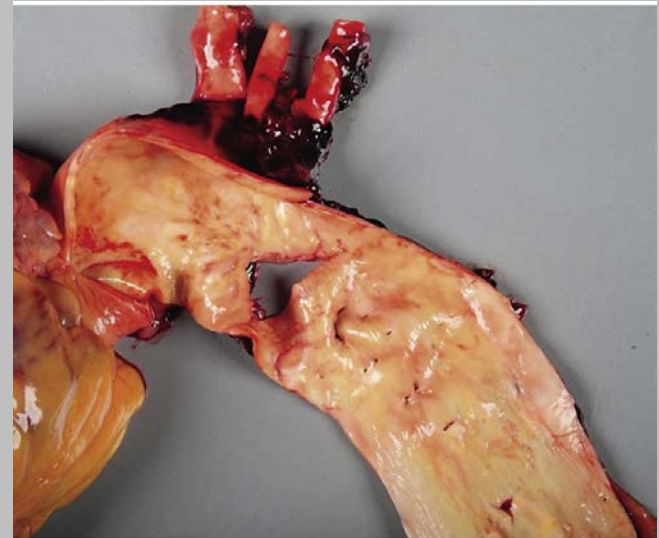

Saphenous vein graft with early latissimus flap

Management of Pediatric Vascular Injuries

Truncal

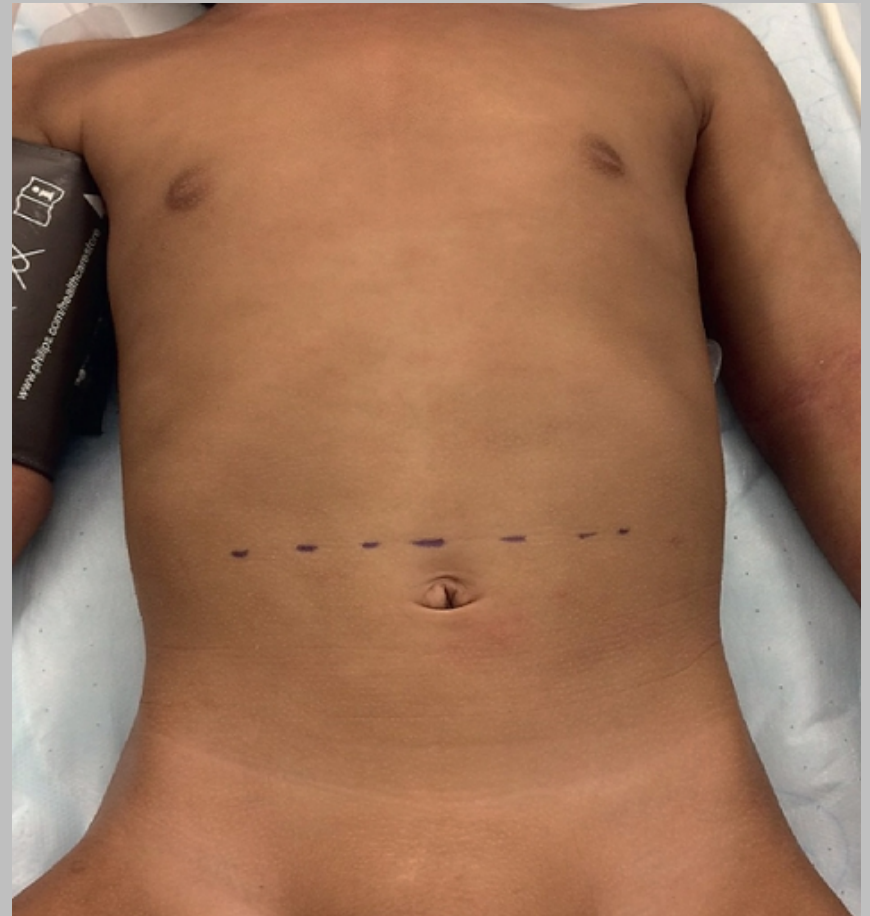
- Thoracic aortic repair
 - Special diagnostic problem
 - Inaccessible on clinical exam
 - Clamp-and-sew technique
 - Delayed repair of blunt injuries
 - Initiate beta-blocker therapy



Management of Pediatric Vascular Injuries

Truncal

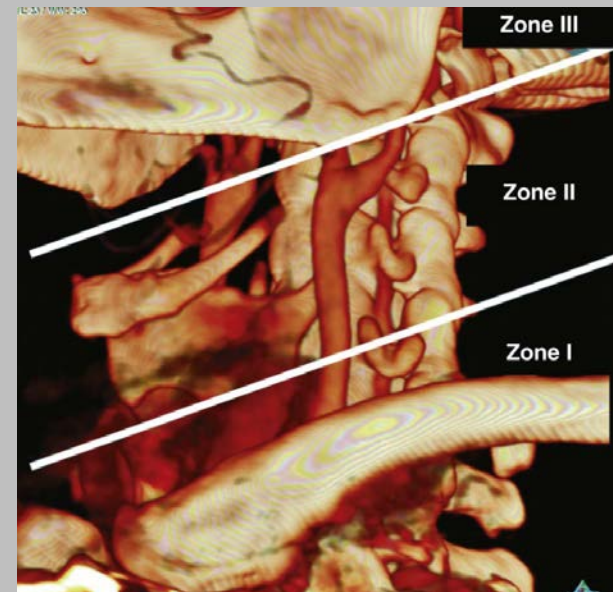
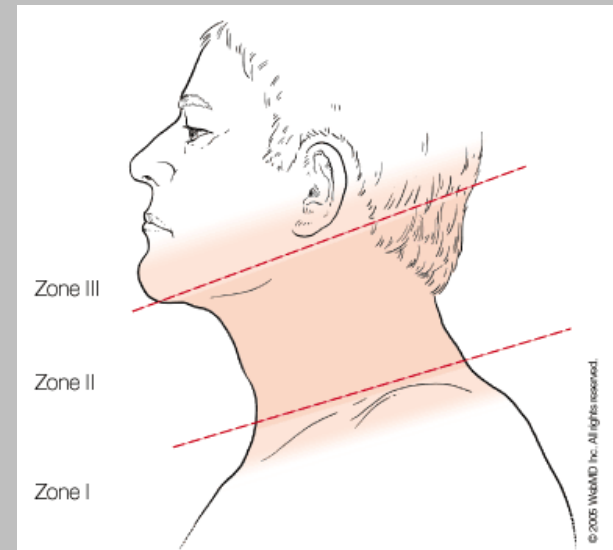
- Abdominal aortic repair
 - After age of 10, there is minimal longitudinal aortic growth
 - Synthetic graft
 - Aortic/caval injuries
 - Autologous conduit (GSV)
 - All other injuries
 - General principles
 - Broadly prep the patient
 - Transverse incision (young children)
 - Provides best exposure to abdominal aorta and its major branches



Management of Pediatric Vascular Injuries

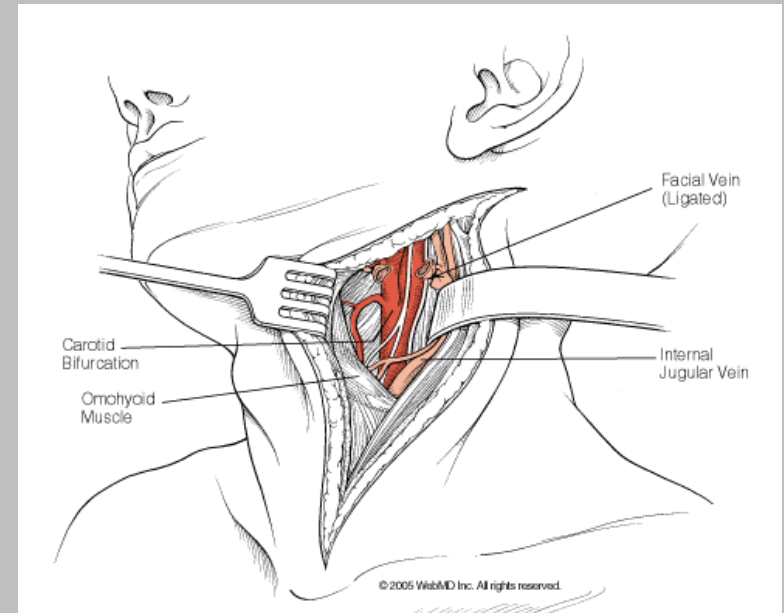
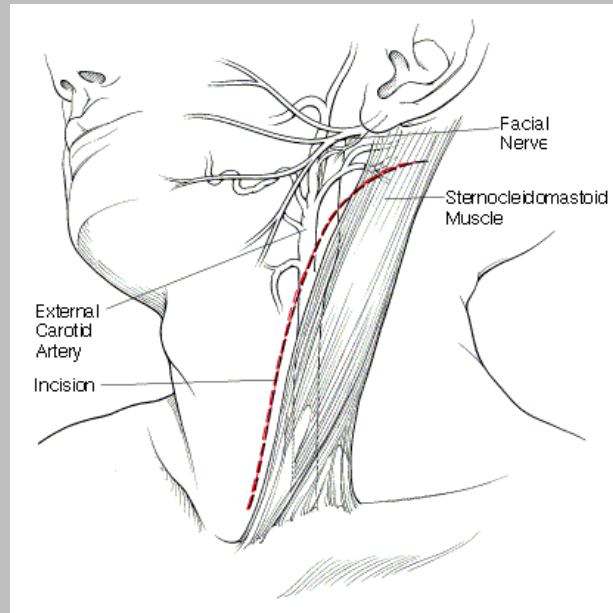
Cervical

- **Zone III**
 - Above the angle of the mandible
- **Zone II**
 - Between the cricoid cartilage and the angle of the mandible
- **Zone I**
 - Below the cricoid cartilage



Management of Pediatric Vascular Injuries

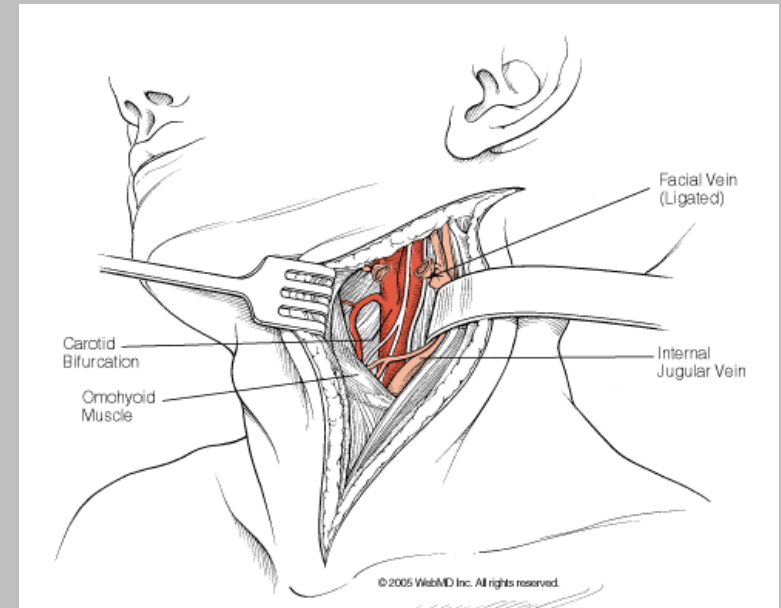
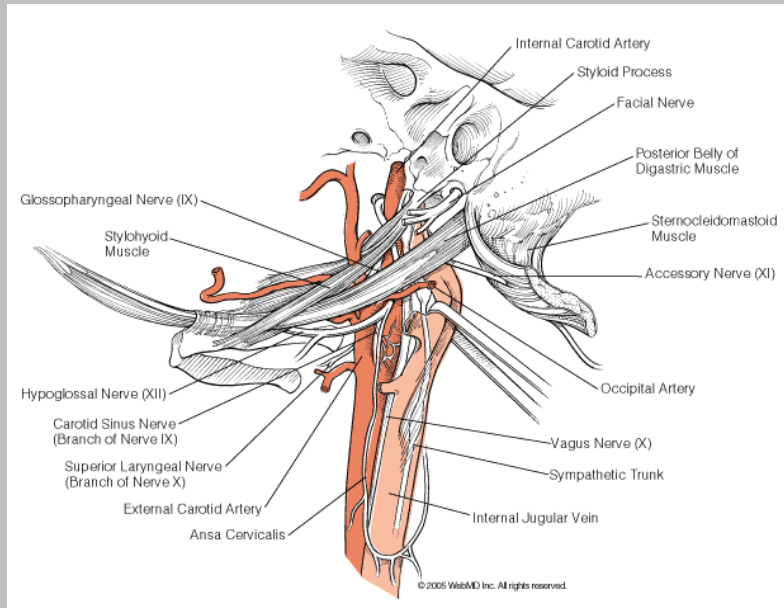
Cervical - Penetrating



- Anatomically accessible lesions (**zone II**) require repair via neck incision

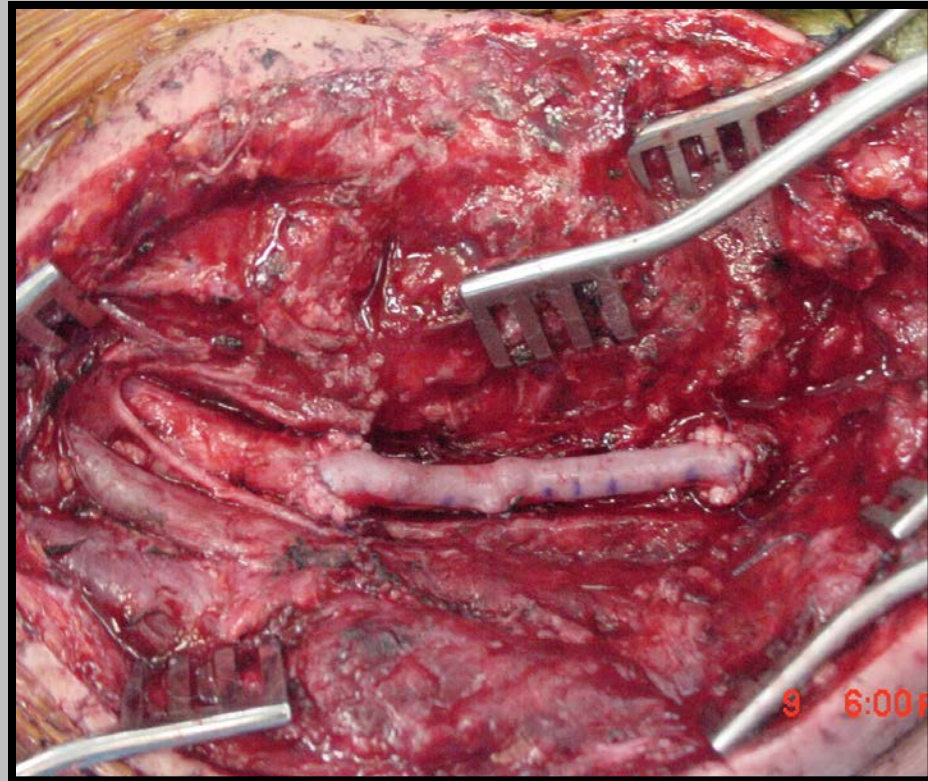
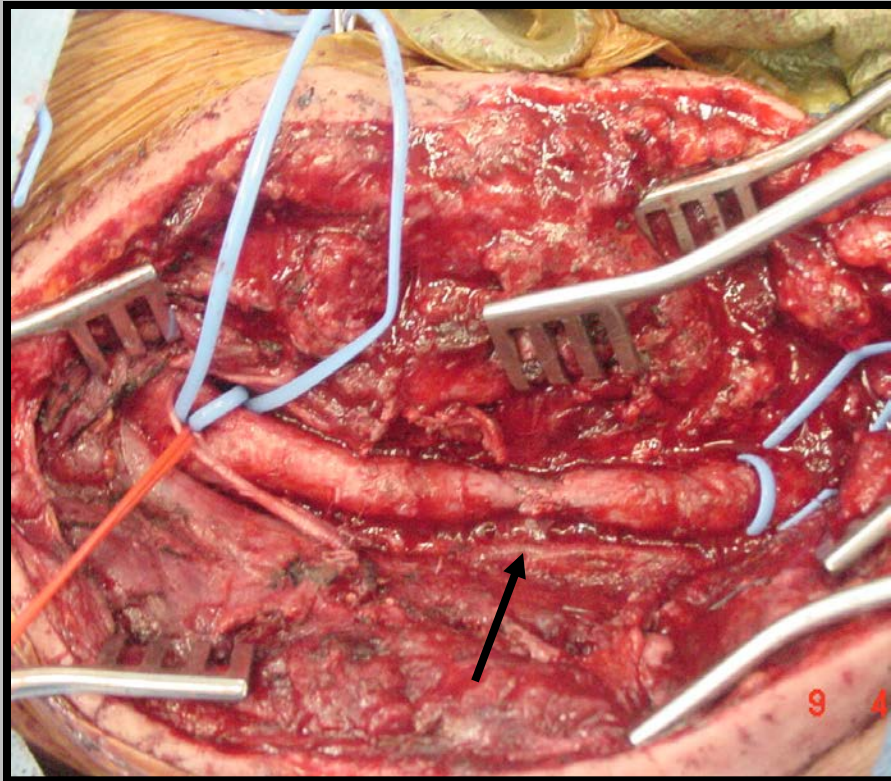
Management of Pediatric Vascular Injuries

Cervical - Penetrating



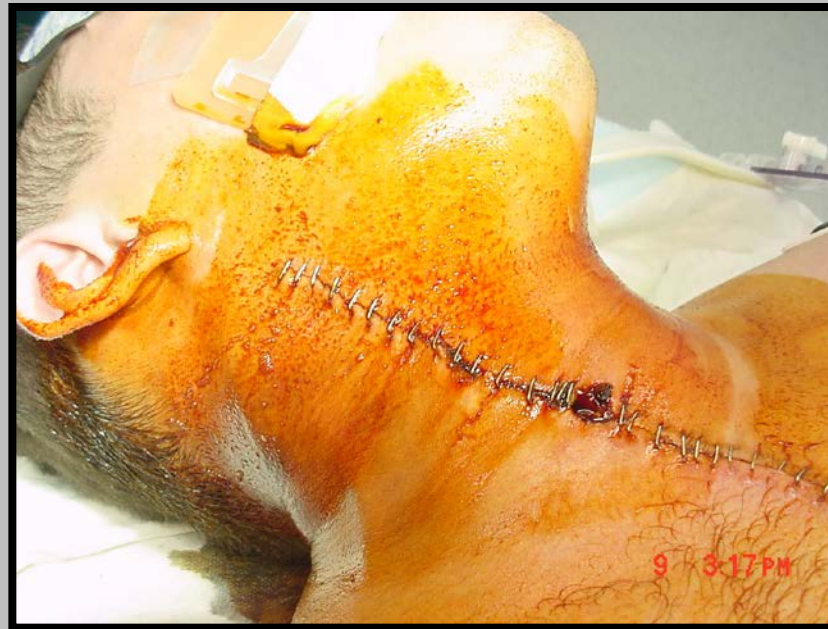- Anatomically accessible lesions (**zone II**) require repair via neck incision

ICA vein graft – Zone II



Management of Pediatric Vascular Injuries

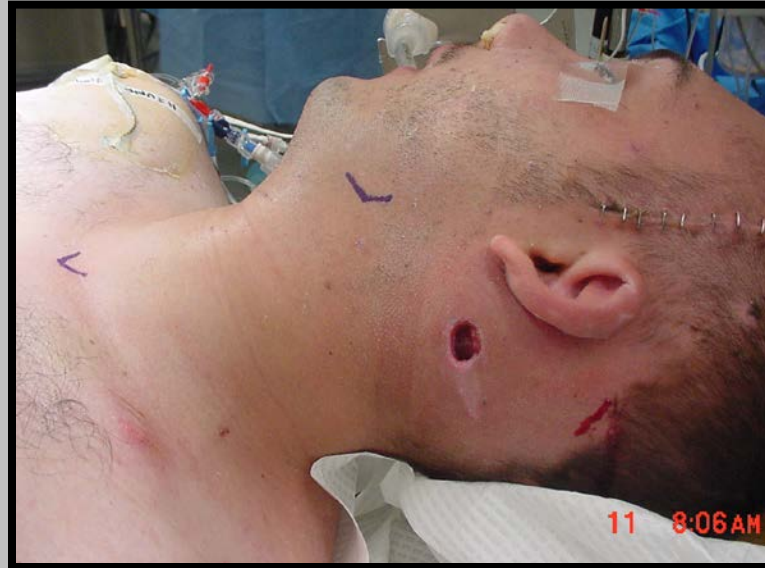Cervical - Penetrating



- Proximal (**zone I**) may require median sternotomy
 - Or start with cervical incision and extent down to median sternotomy

Management of Pediatric Vascular Injuries

Cervical - Penetrating



- Distal (**zone III**) may require ligation of internal carotid artery or endovascular repair

Management of Pediatric Vascular Injuries

Cervical - Blunt

- Hyperextension injury
 - ICA is forcibly stretched over the transverse process of C2 and the body of C1
- Medial/intimal tears/dissection
- Rarely require surgical intervention
- Careful observation, antiplatelet therapy and serial imaging

Management of Pediatric Vascular Injuries

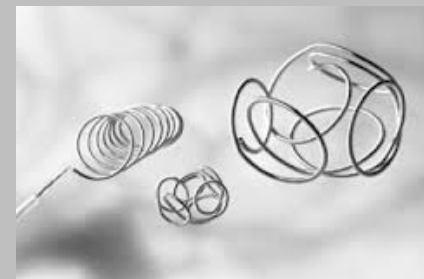
Cervical

- Aerodigestive injuries frequently accompany carotid artery trauma
 - Penetrating >>> blunt
 - Endoscopy
 - Oropharynx, trachea, esophagus
 - Esophagography
- Higher risk of infection of vascular repair !!

Management of Pediatric Vascular Injuries

Endovascular Treatment

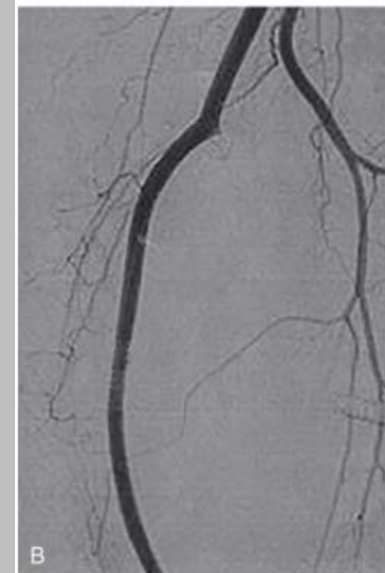
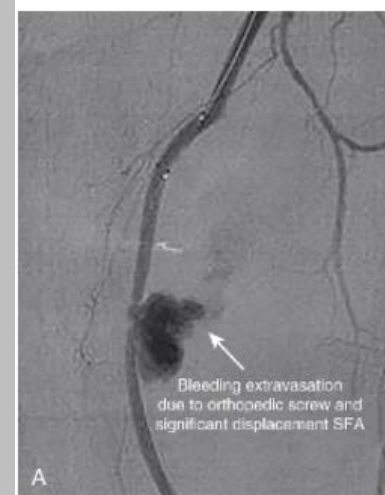
- Limited role in pediatric trauma
- Fraught with complications
 - Access site complications
- Can be used to control bleeding
 - Proximal balloon occlusion
 - Embolization
 - Covered stent placement



Management of Pediatric Vascular Injuries

Endovascular Treatment

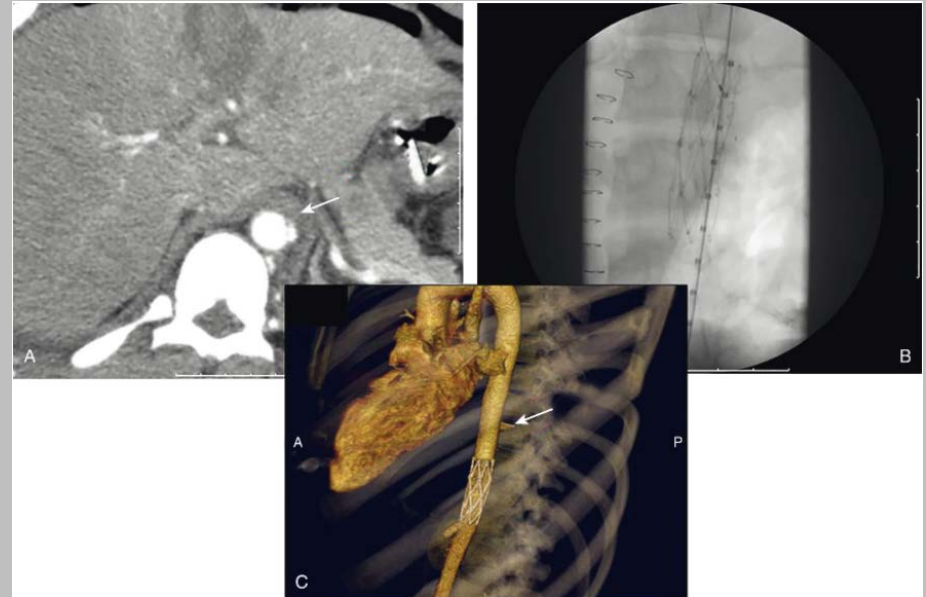
- Limited role in pediatric trauma
- Fraught with complications
 - Access site complications
- Can be used to control bleeding
 - Proximal balloon occlusion
 - Embolization
 - Covered stent placement



Management of Pediatric Vascular Injuries

Endovascular Treatment

- Small thoracic stent grafts for adolescent thoracic aortic repair
 - Long term results are lacking



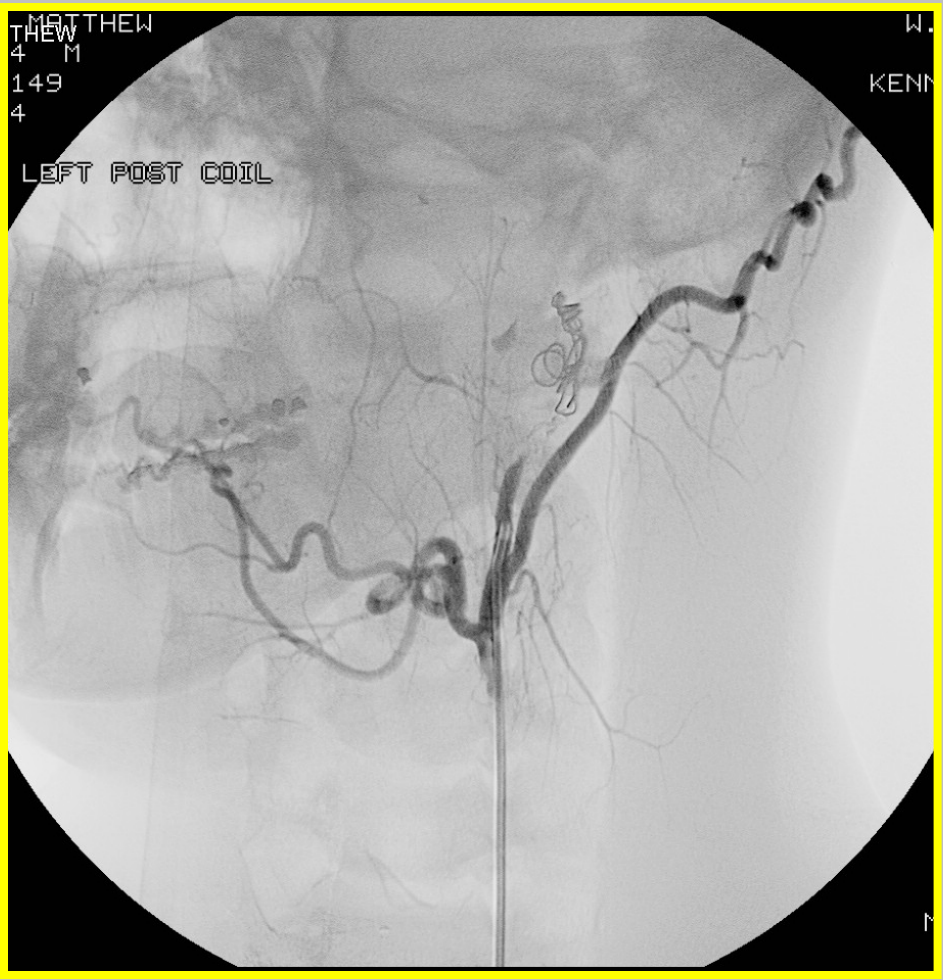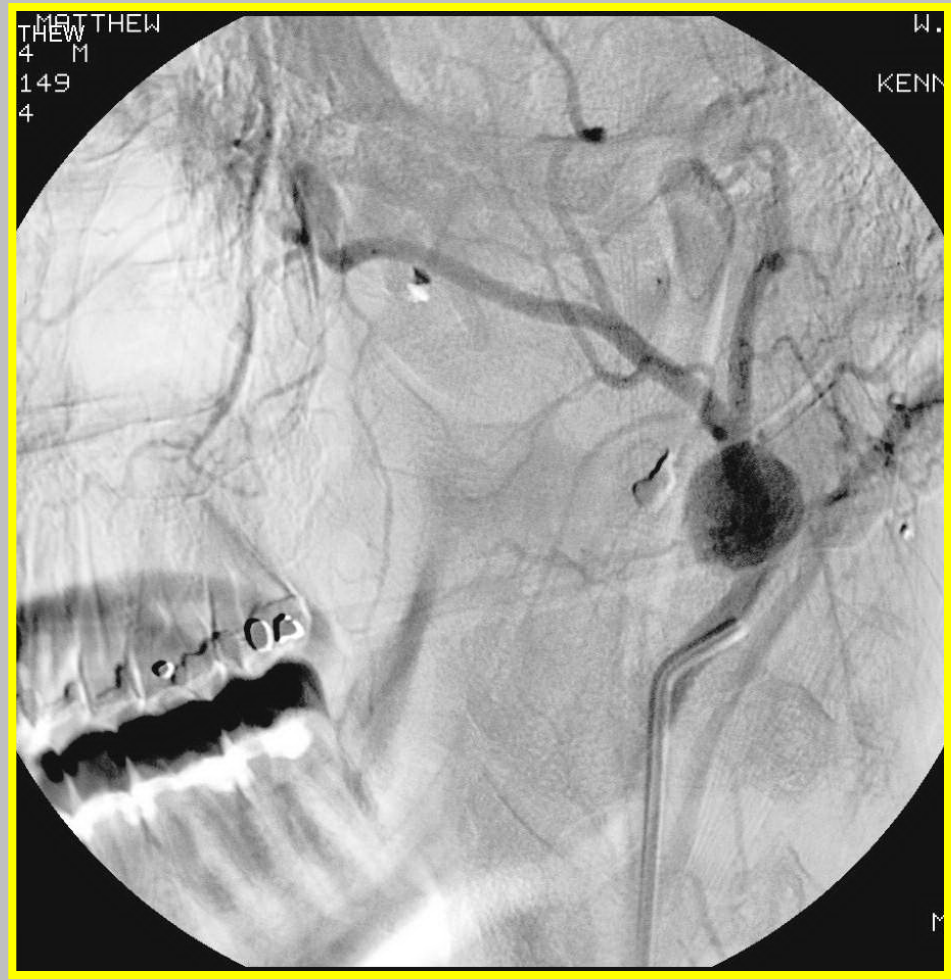Case Reports > Vasc Endovascular Surg. May-Jun 2006;40(3):239-42.

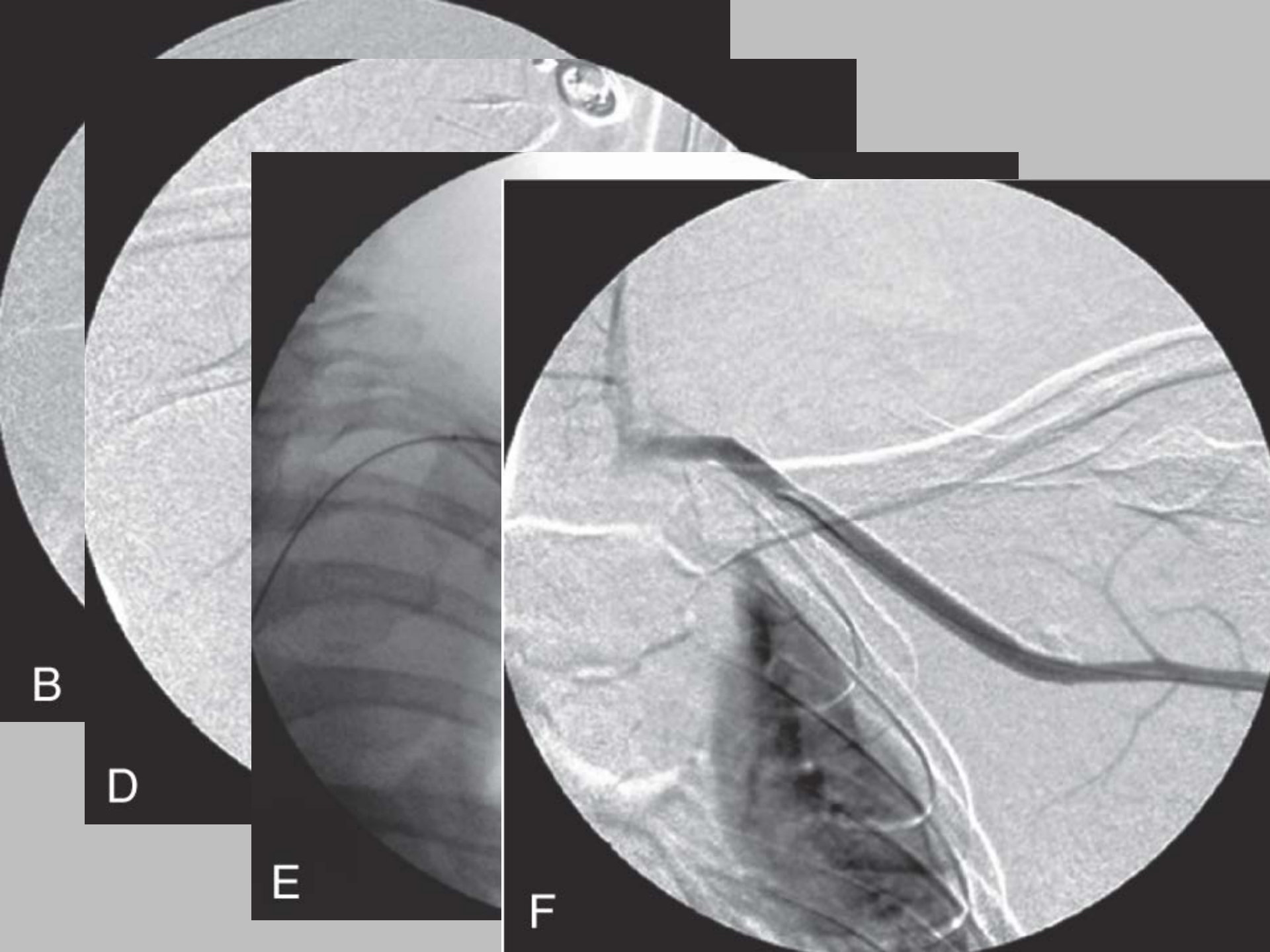
doi: 10.1177/153857440604000310.

Endograft repair of traumatic aortic transection in a 10-year-old--a case report

Gilbert Aidinian¹, Michael Karnaze, Eugene P Russo, Dipankar Mukherjee

Left Carotid Injury





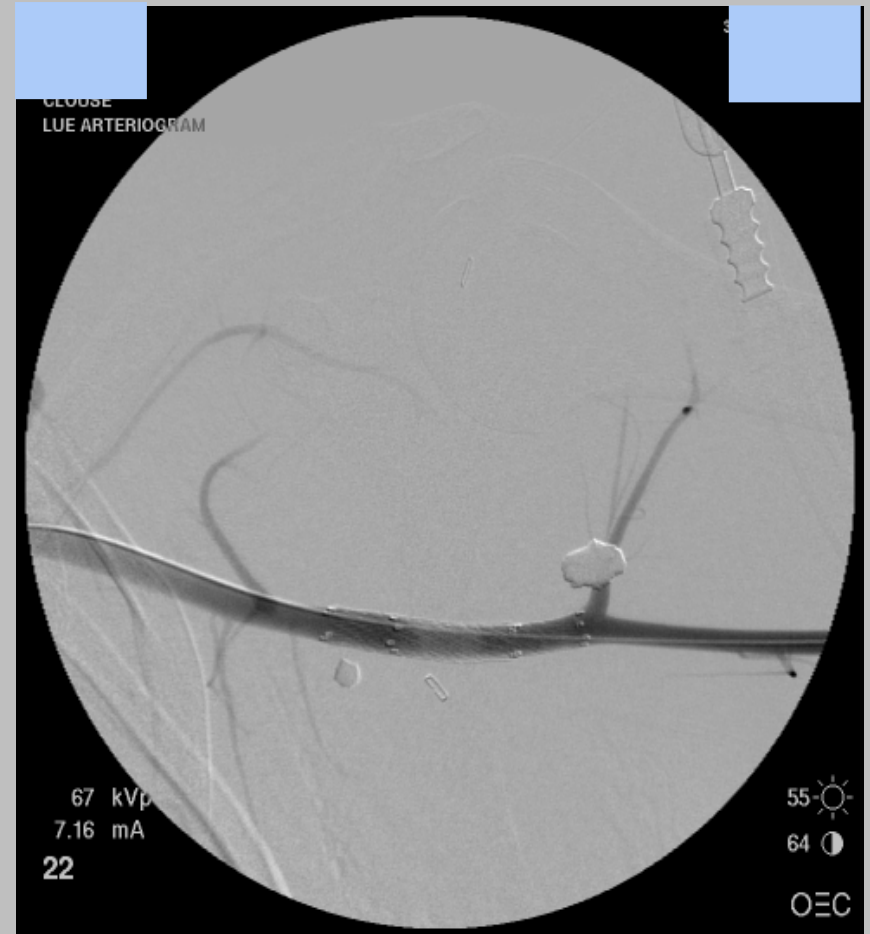
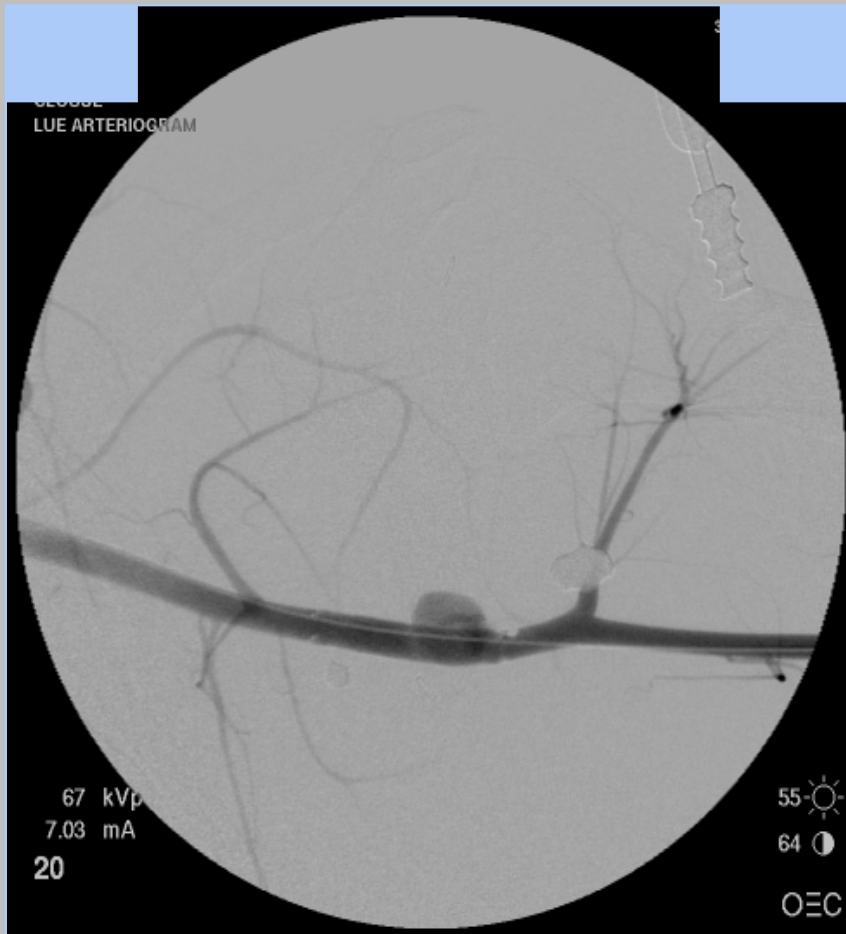B

D

E

F

Covered Stent



Management of Pediatric Vascular Injuries

Endovascular Treatment

- Contrast volume
 - Neonates: Less than 4 – 5 mL/kg
 - Infants: Less than 6 – 8 mL/kg
- Hand injection instead of power injection for patients less than 15 kg
- Systemic heparinization to prevent common femoral artery thrombosis
- 3 to 5 Fr sheaths

Management of Pediatric Vascular Injuries

Postoperative

- Endograft repairs
 - Annual CTA until adulthood
- Duplex surveillance
 - Accessible sites

Conclusion

- Rare events
- Establish algorithmic institutional guidelines to treat these patients
- Guidelines on use of ultrasound for arterial access in this population
- Aggressive operative management

Questions?



William Beaumont Army Medical Center

